



Article

Robotic Liver Resection: Report of Institutional First 100 Cases

Maria Conticchio ^{1,*} , Antonella Delvecchio ¹ , Valentina Ferraro ¹, Matteo Stasi ¹, Annachiara Casella ¹, Rosalinda Filippo ¹, Michele Tedeschi ¹, Alba Fiorentino ^{2,3} and Riccardo Memeo ¹

¹ Unit of Hepato-Biliary and Pancreatic Surgery, “F. Miulli” General Hospital, 70021 Bari, Italy; a.delvecchio@miulli.it (A.D.); v.ferraro@miulli.it (V.F.); m.stasi@miulli.it (M.S.); a.casella@miulli.it (A.C.); rosalinda.filippo@gmail.com (R.F.); m.tedeschi@miulli.it (M.T.); r.memeo@miulli.it (R.M.)
² Unit of Radiation Oncology, “F. Miulli” General Hospital, 70021 Bari, Italy; a.fiorentino@miulli.it
³ Department of Medicine, LUM Giuseppe Degennaro University, 70010 Casamassima, Italy
* Correspondence: maria_cont@hotmail.it; Tel.: +39-3929786255

Abstract: Backgrounds: Liver surgery has developed progressively during the last 10 years, especially in minimally invasive approaches. Robotic surgery seemed to overcome laparoscopic limitations with 3D visualization, the increased degrees of freedom given with Endowrist instruments, tremor filtering, better dexterity, and improved ergonomics for the surgeon. Methods: This work was a retrospective analysis of our first 100 robotic hepatectomies from March 2020 to July 2022. Patient demographics characteristics and intra- and postoperative outcomes were analyzed. Results: A total of 59 males and 41 females, with a median age of 68 years, underwent a robotic liver resection. The indications for robotic liver resections were malignant lesions in 86% of patients. Anatomical resection (AR) was undertaken in 27% of cases and non-anatomical resection (NAR) in 63% of cases. None of the patients were converted to the ‘open’ approach. Postoperative complications were as follows: 1% of biliary leakage, 5% of ascites, 6% of pulmonary infections, and 3% of other sites’ infections. CONCLUSIONS Our results showed the satisfactory experience of a tertiary HPB center with its first 100 robotic liver resections. The opportunity to make the robotic approach routinary provided global growth of a surgical team, improving the quality of patient outcomes.

Keywords: robotic surgery; first 100 cases; liver resections



Citation: Conticchio, M.; Delvecchio, A.; Ferraro, V.; Stasi, M.; Casella, A.; Filippo, R.; Tedeschi, M.; Fiorentino, A.; Memeo, R. Robotic Liver Resection: Report of Institutional First 100 Cases. *Surg. Tech. Dev.* **2023**, *12*, 176–187. <https://doi.org/10.3390/std12040017>

Academic Editor: Egidio Riggio

Received: 22 April 2023

Revised: 26 August 2023

Accepted: 7 October 2023

Published: 12 October 2023



Copyright: © 2023 by the authors. Licensee MDPI, Basel, Switzerland. This article is an open access article distributed under the terms and conditions of the Creative Commons Attribution (CC BY) license (<https://creativecommons.org/licenses/by/4.0/>).

1. Introduction

Liver surgery has developed progressively during the last 10 years, especially in minimally invasive approaches. Since the first laparoscopic liver resection in 1992, many innovations in techniques and tools have marked the evolution of liver surgery. The initial Consensus Conference of Louisville in 2004 [1], Morioka in 2008 [2], and the recent Southampton Guidelines Meeting in 2017 [3] have stated standard references concerning surgical indications and specific techniques in the laparoscopic approach.

Moreover, the diffusion of robotic platforms has exponentially increased; in 2003, Giulianotti and colleagues [4] reported the first series of robotic-assisted laparoscopic liver resections.

In 2018, the first international consensus statement on robotic liver surgery was published [5] to promote the development of robotic hepatectomies.

Robotic surgery seemed to overcome laparoscopic limitations with 3D visualization, the increased degrees of freedom given with Endowrist instruments, tremor filtering, better dexterity, and improved ergonomics for the surgeon [6–10]. Despite several studies that have shown the feasibility and safety of the robotic approach compared with the laparoscopic one, the benefits of robotic surgery still remain under debate [11–13].

The only evidence of the superiority of the robotic over laparoscopic approach concerns complex hepatectomies, such as postero-superior resection, hilar dissection, and biliary-enteric anastomoses [14].

The main benefits of robotic surgery regarding the improvement of surgical technique are better surgeon ergonomics, facilitating the use of indocyanine green images, potential for intraoperative liver navigation, and faster learning curves.

Moreover, robotic surgery can be considered advantageous compared to conventional laparoscopy in cases of extended abdomen adhesions derived from previous surgeries [15].

Anyway, frail and elderly patients benefit from minimally invasive surgery thanks to the reduction of postoperative complications, faster postoperative recovery, and quick returns home [16].

The aim of our study was to report our initial experience with the first 100 robotic liver resections. The primary endpoint was to show intraoperative data about our standardized techniques. Secondly, we reported postoperative outcomes in order to explore the results and which factors have had an impact.

2. Materials and Methods

2.1. Study Design

This work was a retrospective analysis of first 100 robotic hepatectomies from a prospectively collected database of all liver resections at our center from March 2020 to July 2022.

This study included patients ≥ 18 years old who underwent robotic liver resection for benign and malignant liver lesions.

The diagnosis was based on non-invasive findings (CT scan or MRI abdomen) or histopathology when necessary. The type of treatment was planned in multidisciplinary team discussions including surgeons, hepatologists, oncologists, interventional radiologists, and pathologists.

This research was conducted in agreement with the local ethics committee, and all participants gave written informed consent to participate in this study.

In our center, all minimally invasive liver resections are systematically performed with a robotic approach thanks to daily access to the robotic platform.

Patient characteristics included gender, age, type of underlying liver disease, Child–Pugh score, MELD score, American Society of Anesthesiology (ASA) score, body mass index (BMI), Charlson Comorbidities score, albumin, serum Ca 19.9, and AFP. Lesion features included benign or malignant nature, position, size, and number. Intraoperative variables were reported including operative time, estimated blood loss, number of transfusions, and rate of conversion. Measures of postoperative outcome were reported as postoperative complications (general and liver-related), with indication of their severity according to Clavien Dindo classification [17], rate of re-operation, length of hospital stay, and 90-day mortality rate.

Preoperative study included a multidisciplinary evaluation (MDT evaluation) with CT scan staging and MRI often associated with Primovist administration. Liver biopsy was reserved for cases of uncertain diagnosis. Robotic approach was our default technique in minimally invasive liver resections.

Huge tumors, vascular structures involvement, or prior abdominal surgery did not represent a contraindication to the robotic approach. Perihilar cholangiocarcinoma was suitable for an ‘open’ approach.

2.2. Surgical Technique

Robotic surgery was performed using the da Vinci Xi robotic platform (Intuitive Surgical Inc., Sunnyvale, CA, USA).

The surgery was mainly performed by 2 surgeons experienced in liver surgery. Their preparation comes from about 10 years of open and laparoscopic liver surgery. Thanks to this experience, the surgeons had an advantage in adapting to the robotic platform. Initially, less complex robotic liver resections were preferred to minimize potential complications during the learning phase. As surgeons gained proficiency, they gradually moved on to more complex surgeries, such as major liver resections or tumors in difficult locations.

Managing potential intraoperative and postoperative complications is also an essential aspect of the learning curve. As experience grows, surgeons have become better equipped to effectively manage complications. Robotic surgery involves a multidisciplinary team, which includes surgical assistants, nurses, and anesthesiologists. Effective teamwork and communication are key to achieving positive results.

The patient was placed in a supine position and 30° reverse Trendelenburg position with a mild lateral inclination. A pneumoperitoneum was created using an open technique through a supra-umbilical incision. Other 3 robotic trocar and 1 or 2 laparoscopic 12 mm trocar assistants (depending on procedure) were inserted under direct vision, and their location was standardized in two types of positioning according to interested hemi liver (Figures 1 and 2).

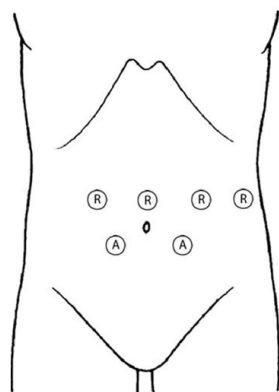


Figure 1. Trocar position for left hemi liver resections.

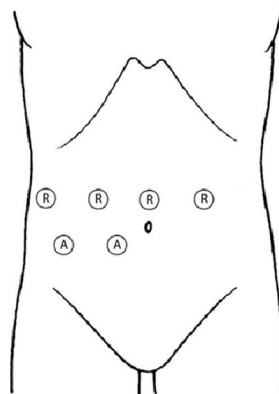


Figure 2. Trocar position for right hemi liver resections.

The surgeon was seated at the robotic console, and the assistant surgeon was between patient's legs. The assistant surgeon performed retraction, suction, clipping, and eventually stapling.

In cases of previous abdominal surgery, viscerolysis was performed with cold scissors and blunt maneuvers. Viscerolysis was started laparoscopically, up to allowing positioning of robotic trocars, and completed robotically. Every procedure began with an abdominal cavity exploration and the first part of the mobilization of hemiliver, associated with intraoperative ultrasound. The hepatic hilum was prepared to Pringle maneuver with section of hepatoduodenal ligament and the positioning of Foley catheter for intracorporeal intermittent pedicle clamping.

The pedicle approach was chosen depending on the planning procedure. Liver parenchymal transection was performed with double bipolar forceps, 'kellyclasia' fashion, and using Vessel Sealer (Intuitive Surgical Inc, Sunnyvale, CA, USA). Indocyanine Green (ICG) visualization was routinely used in positive or negative staining in association

with intraoperative ultrasound to better underline lesions or parenchymal demarcation or anatomical vascularization. One vial of ICG (25 mg, Verdyne®, Diagnostic Green GmbH, Aschheim, Germany) 0.2 mg/Kg was dissolved in 25 mL sodium hydrochloride or water for intraoperative intravenous injection.

Hem-o-lock clips or linear EndoGIA staplers were used for the section of vascular and biliary structures. The specimens were placed in a laparoscopic extraction bag and removed through a mini-Pfannenstiel incision.

2.3. Statistical Analysis

Statistical analyses were performed using the IBM SPSS Statistics 20 software. Demographic data and clinical outcomes were analyzed. Continuous variables were compared using an independent sample *t*-test and Mann–Whitney U test. Categorical variables were compared using the chi-square test and Kruskal–Wallis test, respectively.

3. Results

From March 2020 to July 2022, we performed 100 robotic liver resections on 59 males and 41 females, with a median age of 68 years. The BMI was 26.7 ± 3.2 kg/m², and the ASA score was 3 in 47% of our patients. A total of 52% of our patients presented a history of cardiovascular disease, 19% of diabetes mellitus, and 32% showed cirrhosis, with a Child–Pugh score A in 97% of the total.

The 74% of resected lesions were single nodules, with a median tumor size of 25 mm (18–45 mm), Table 1.

Table 1. Patient demographics.

		All	Median (Range Interquartile)
	N	n = 100	
Age	100	66 ± 12	68 (58–75)
Age ≥ 65 y	100	58 (58.0%)	
Male	100	59 (59.0%)	
BMI	100	26.7 ± 3.2	27.0 (24.0–28.0)
ASA_I-II	100	53 (53.0%)	
ASA_III-IV	100	47 (47.0%)	
Previous open abdominal surgery	100	34 (34.0%)	
Previous laparoscopic abdominal surgery	100	26 (26.0%)	
Smoking	100	16 (16.0%)	
Diabetes	100	19 (19.0%)	
Cardiovascular disease	100	52 (52.0%)	
Pulmonary diseases	100	12 (12.0%)	
ALD	100	5 (5%)	
NASH	100	15 (15%)	
HBV	100	9 (9%)	
HCV	100	17 (17%)	
Other	100	2 (2%)	
Cirrhosis	100	32 (32.0%)	
MELD Score	100	6.6 ± 1.7	

Table 1. *Cont.*

		All	Median (Range Interquartile)
	N	n = 100	
Child–Pugh A	100	97 (97%)	
Child–Pugh B	100	3 (3%)	
CHARLSON Comorbidity score	99	6.4 ± 2.8	7.0 (5.0–8.0)
Preoperative albumine level	76	3.86 ± 0.49	3.90 (3.50–4.20)
CA199_preop	74	98 ± 470	12 (3–27)
AFP_preop	75	119 ± 757	3 (2–6)
ACE_preop	73	36 ± 254	2 (2–4)
Preoperative chemotherapy	100	25 (25%)	
Number of lesions > 1	100	26 (26%)	
Liver tumor size (mm)	96	36 ± 28	25 (18–45)

The indications for robotic liver resections were malignant lesions in 86% of patients: 35% hepatocellular carcinoma (HCC), 3% intrahepatic cholangiocarcinoma (iCCA), 8%, gallbladder carcinoma, 27% colorectal liver metastasis (CRLM), 13% non-colorectal liver metastasis (NCRLM), and 14% benign lesions (5% adenoma, 4% hepatic cyst, 1% FNH, 3% hemangioma, 1% intrahepatic lithiasis), Table 2.

Table 2. Indications for hepatectomy.

	N
Adenoma	5
Hepatic cyst	4
FNH	1
Hemangioma	3
Intrahepatic lithiasis	1
HCC	35
iCCA	3
ADK cholec	8
CRLM	27
NCRLM	13

Among all liver resections, 90 minor resections were performed: 62 in antero-lateral segments and 28 in the postero-superior liver segments.

Major hepatectomy, defined as resection of three or more adjacent liver segments, was performed in 10% of the cases (4% formal left hepatectomy, 5% formal right hepatectomy, 1% central hepatectomy). Anatomical resection (AR) was undertaken in 27% and non-anatomical resection (NAR) in 63% of cases, of which 24% were in postero-superior liver segments, Table 3. According to the IWATE Difficulty Index Scoring System, 41 liver resections resulted in a high difficulty score, 17 with an intermediate score, and 42 with a low difficulty score.

Table 3. Type of surgery.

	N
Formal Left Hepatectomy	4
Formal Right Hepatectomy	5
Anatomical Resection	27
Non-Anatomical Resection	63
Central Hepatectomy	1

The median operative time was 298 min with a median 200 cc of intraoperative estimated blood loss (EBL). An intermittent pedicle clamping was performed in 73% of procedures.

None of the patients were converted to the ‘open’ approach.

Postoperative complications were represented by 1% of biliary leakage, 5% of ascites, 6% of pulmonary infections, and 3% of infections of other sites.

Only one patient underwent a reoperation during hospitalization who represented a Clavien Dindo 3b postoperative complication.

The median length of hospital stay was 5 days (range 4–6). Postoperative mortality was nil. One of the 5% of the 90-day readmitted patients died of multiorgan failure (MOF), Table 4.

Table 4. Intraoperative and postoperative outcomes.

	N	All n = 100	Median (Range Interquartile)
Difficult Index Score			
Low	100	42 (42.0%)	
Intermediate	100	17 (17.0%)	
High	100	41 (41.0%)	
Simultaneous procedure	100	28 (28.0%)	
Rehepatectomy	100	4 (4.0%)	
Conversion rate	100	0 (0.0%)	
Operative time (min)	100	302 ± 107	298 (240–360)
Estimated blood loss (mL)	100	225 ± 178	200 (100–275)
Blood transfusion	100	1 (1.0%)	
Pedicle clamping	100	73 (73.0%)	
Total time of clamping (min)	100	34 ± 32	30 (0–48)
Drain	100	99 (99.0%)	
Postoperative complications	100	15 (15.0%)	
Biliary leakage	100	1 (1.0%)	
Hemorrhage	100	0 (0.0%)	
Ascitis	100	5 (5.0%)	
Pulmonary infection	100	6 (6.0%)	
Other infection	100	3 (3.0%)	

Table 4. Cont.

	N	All n = 100	Median (Range Interquartile)
Difficult Index Score			
Clavien Dindo 1	100	68 (68.0%)	
Clavien Dindo 2	100	8 (8.0%)	
Clavien Dindo 3	100	1 (1.0%)	
Reintervention	100	1 (1.0%)	
ICU stay days	100	0.08 ± 0.27	
Length of hospital stay	100	5.5 ± 2.6	5.0 (4.0–6.0)
Postoperative CT scan	100	23 (23.0%)	
Readmission at 90 d	100	5 (5.0%)	
Death	100	1 (1.0%)	

The number of included patients per year is shown in Figure 3; 10 robotic liver resections were performed during 2020, and 45 were performed for 2021 and 2022.

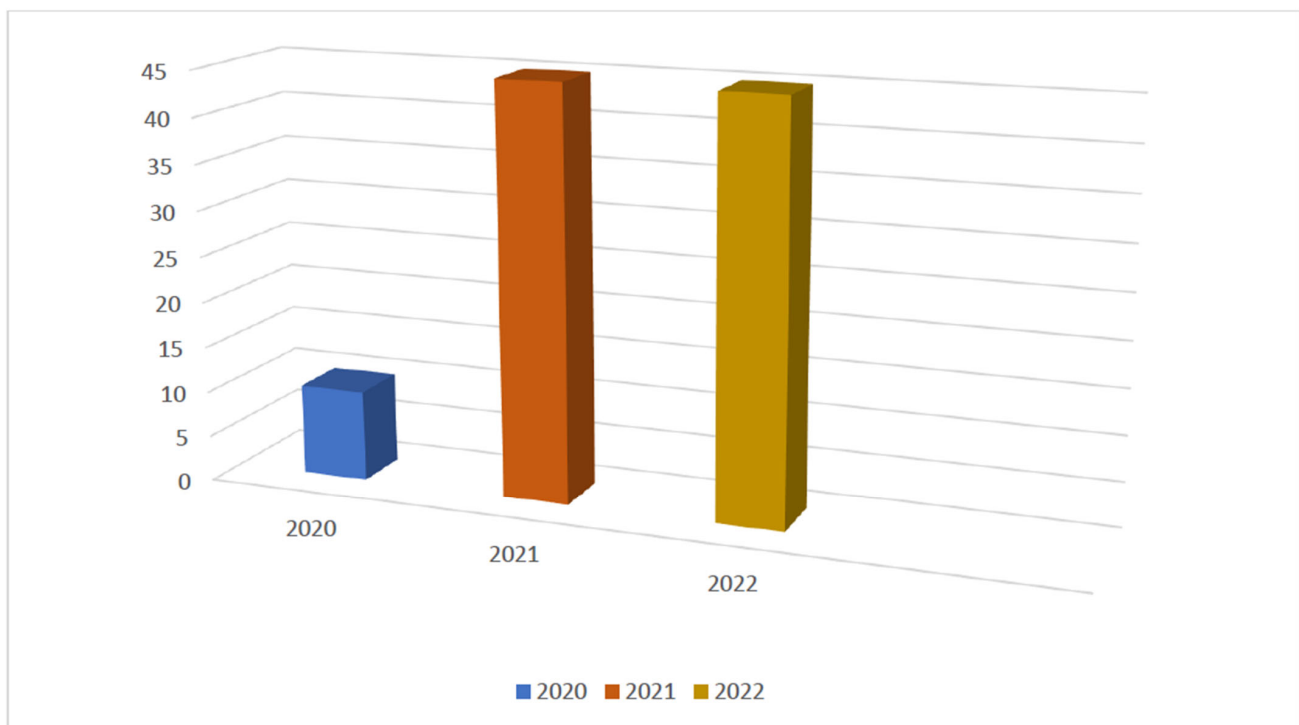


Figure 3. Table of patients per year.

4. Discussion

A minimally invasive approach has radically marked the evolution of liver surgery. If most of the laparoscopic procedures have been standardized over time and become the gold standard, the robotic approach requires a formal framework.

The high-definition of 3D vision, the tremor filter, the dexterity given by the endowristed movements, and an augmented surgeon's ergonomics allowed the surgeon to perform some complex procedures, like hilar dissection or bilio-enteric anastomosis, and access to posterosuperior segments thanks to the articulation of the instruments, overcoming the limits of the laparoscopy [18–21].

However, the absence of tactile feedback, the high cost, and the lack of available surgical instruments limit robotic platform development and application.

The diffusion of the robotic platform has exponentially increased in the last 10 years, showing that there is a low level of evidence concerning the cost as a substantial limit [22,23] and that in centers with a solid training program, the learning curve is faster compared to laparoscopic procedures and also for major resections [24–26].

In 2018, the first international consensus statement on robotic liver surgery was published [5] to promote the development of robotic hepatectomies.

According to the recommendations, robotic hepatectomy had a longer operative time and higher costs, whereas no significant differences were observed for blood transfusion rate, R0 resection rate, length of hospital stay, overall complication rate, severe complication rate, and oncological outcomes compared to the laparoscopic approach.

To date, the benefits of the robotic approach in liver surgery have not yet been clearly defined.

Some recently published studies, including minor and major hepatectomies, have compared robotic and laparoscopic techniques without providing conclusive results in favor of either approach [21].

Other studies showed a lower estimated blood loss, less narcotic use, shorter length of hospital stay, and improved short-term quality of life in the robotic approach for complex liver resection [5].

The reduction in blood loss during robotic major hepatectomy is due to the significant improvement in the magnification of the field of view, which allows surgeons to identify vessels and more accurately control blood inflow and outflow [27].

Patients who benefit from a robotic approach are those with lesions of the postero-superior segment, tumors difficult to reach with conventional laparoscopic procedures, which would require a large skin incision when performed with an open approach [14].

In addition, frail and elderly patients with a loss of reserve capacity and a lifetime accumulation of different diseases benefit from minimally invasive surgery thanks to the reduction of postoperative complications, a faster postoperative recovery, and a quick return home [16].

The main benefits of robotic surgery regarding the improvement of surgical technique are better surgeon ergonomics, facilitating the use of indocyanine green images, the potential for intraoperative liver navigation, and faster learning curves.

The complexity of liver anatomy and the absence of clear superficial liver landmarks have prompted the development of intraoperative navigation systems.

The purpose of intraoperative navigation tools is to provide feedback to surgeons regarding the location of the transection line relative to the lesion of interest and vascular structures [14].

The learning curve depends on the surgeons' individual skills, their previous surgical experience, and the availability of training opportunities. The goal of the learning curve is to achieve a high level of proficiency in surgical outcomes while minimizing patient risk.

Another important topic of discussion is the use of a robotic approach in previous abdominal surgery. Peritoneal adhesions resulting from previous abdominal surgery are associated with longer operating times, technical difficulties, and higher postoperative complication rates. This was shown to be more pronounced after previous open surgery than previous minimally invasive surgery [15].

Robotic surgery is more advantageous than conventional laparoscopy to perform adhesiolysis. A recent study showed that conversion rates due to adhesions were significantly reduced in the robotic approach [28].

However, there are still some limitations associated with robotic liver surgery regarding setup time, lack of hepatic feedback, limited availability, instrumentation limitations, and costs.

The extra time required to undock the robotic platform may be considered deleterious during conversion to an open procedure in an emergency setting [14].

One of the challenges in robotic and generally minimally invasive surgery is the lack of hepatic tactile feedback for the surgeon. In open surgery, surgeons can feel the tissues they are manipulating. Robotic systems typically provide visual and tactile feedback through the controls, but true haptic feedback is limited.

The robotic platform does not have the wide range of instruments available in open and laparoscopic surgery; for example, the system does not integrate an ultrasonic aspirator for parenchymal transection.

In this era of increased focus on health care costs, not only questions of surgical safety and efficacy but also costs must be considered in the decision-making process.

For many centers, the high costs are the reason why robotic surgery is still not routinely performed. However, it is important to note that a faster postoperative recovery and lower rates of postoperative complications compensate for the costs incurred by the use of the robotic platform.

In our center, the hospital policy allows daily use of robotic platforms thanks to the knowledge that, in expert hands, postoperative benefits of robotic surgery may mitigate intraoperative costs of robotic instruments.

This work reported outcomes of our initial 100 robotic liver resections during the last two years. We showed the safety and feasibility of the robotic approach for different types of procedures, from non-anatomical resections to major hepatectomies, with all the benefits of the minimally invasive technique associated with the advantages of making some complex procedures approachable more difficult in laparoscopy.

With 59% of males and a median BMI of 27 kg/m², our patients' characteristics were in line with the reported data of Western experiences [10,29,30]. More than half of our patients have had previous abdominal surgery (open or laparoscopic), and we performed the total of our liver resections with a nil conversion rate. This was a main finding that underlined the ability of the robotic platform to make extensive viscerolysis possible and to make patients already operated on benefit from the advantages of the minimally invasive approach.

As reported in several studies, almost the whole of our patients (86%) presented a malignant lesion as an indication of the resection, often on liver disease (48%), with a well-preserved liver function (97% Child–Pugh A).

Since the introduction of the robotic platform in our hospital, this approach has become our default approach for all liver resections eligible for minimally invasive surgery (MIS), Figure 4.

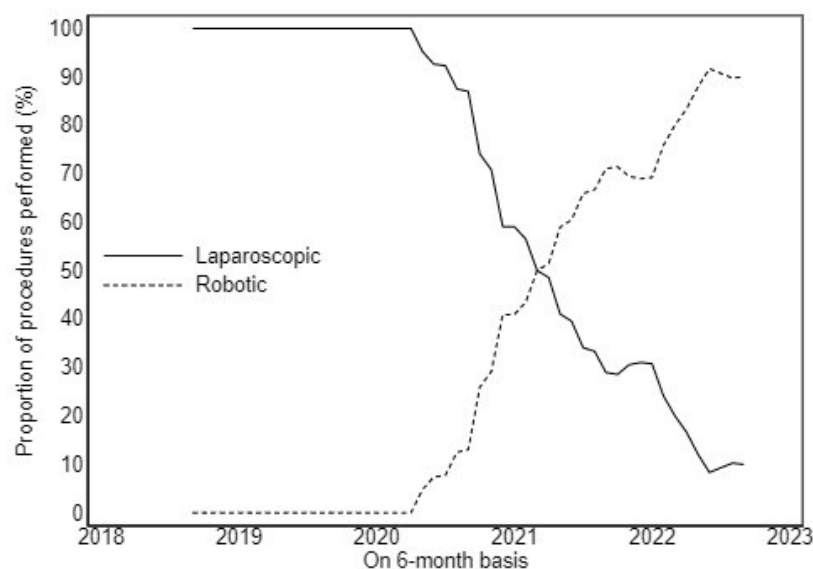


Figure 4. Laparoscopic and robotic trends in our center.

This systematic choice made it possible to build a dedicated team that quickly became experts, reducing the docking time, preparation, and setting up of the robotic room. Furthermore, the presence of the double console represented a key resource in the learning curve of the young surgeons in our group, guaranteeing a safe approach, rapid progression, and standardization of procedures.

A total of 90% of our robotic liver resections was represented by minor resections, with the first formal right hepatectomy performed by our senior HPB surgeon after about 40 minor procedures. The following major hepatectomy had a lower operative time comparable to minor ones. This result could be justified not only by a faster learning curve possible with the robot but also by the key contribution given with dedicated surgical equipment, which increased global efficiency.

Our operative time and intraoperative estimated blood loss (EBL) were similar to the reported data [7,8,10]. The magnified 3D view, better manipulation of the liver parenchyma, and the introduction of new energy devices made these results comparable with conventional laparoscopic ones, even if in the absence of the cavitron ultrasonic dissector [31,32].

A nil rate of conversion underlined the advantage provided by the robotic platform with the high degree of movements, with the tremor filtration and the stereoscopic camera, in the management of intraoperative complications, like bleeding or difficult exposure, often reported as causes of conversion in laparoscopic procedures.

Concerning postoperative outcomes, we presented a 15% complication rate in line with recent data [10,30,32], which is significantly lower than post-open liver resections.

Preoperative assessment of frailty is increasingly used as an important tool for predicting perioperative risks and the outlook for an uncomplicated recovery.

Many scores have been created to estimate and predict the risk of postoperative complications, for example, the NSQIP risk calculator. The scores can be used to identify frail patients who would benefit from preoperative rehabilitation interventions and to select treatment options with a more favorable risk/benefit ratio.

The goal of the scores is to provide accurate, patient-specific risk information to guide both surgical decision-making and informed consent [33].

The length of hospital stay was not significantly lower than other experienced center results [9,34,35]. A formal Enhanced Recovery After Surgery protocol that provides prehabilitation and standardized postoperative rehabilitation could improve this trend.

This work presented some limitations, first of all, concerning oncologic long-term outcomes due to 'en cours' follow-up. Secondly, the nature of this paper was to report a single-center experience that represented an intrinsic conceptual limit.

Our results showed the satisfactory experience of a tertiary HPB center with its first 100 robotic liver resections. The opportunity to make the robotic approach routinary provided global growth of a surgical team, improving the quality of patients' outcomes.

5. Conclusions

Robotic liver surgery represents a constantly evolving reality that seems capable of enhancing surgeon's abilities. Our experience reported robotic liver resections as safe and feasible procedures, demanding a faster learning curve, and it guaranteed the same benefits of laparoscopy, making complex procedures more approachable.

Author Contributions: Conceptualization, M.C.; methodology, A.D.; investigation, A.C. and R.F.; resources, M.S.; data curation, V.F.; writing—original draft preparation, M.C.; writing—review and editing, M.T.; validation, A.F. and R.M. All authors have read and agreed to the published version of the manuscript.

Funding: This research received no external funding.

Institutional Review Board Statement: Not applicable.

Informed Consent Statement: Informed consent was obtained from all subjects involved in this study.

Data Availability Statement: The data presented in this study are available on request from the corresponding author.

Acknowledgments: We thank Pietro Guida, Clinical Trials Office-Direzione Sanitaria Ente Ecclesiastico Ospedale Generale Regionale ‘F. Miulli’, for assistance in the statistical analysis.

Conflicts of Interest: The authors declare no conflict of interest.

References

- Buell, J.F.; Cherqui, D.; Geller, D.A.; O'Rourke, N.; Iannitti, D.; Dagher, I.; Koffron, A.J.; Thomas, M.; Gayet, B.; Han, H.S.; et al. The International Position on Laparoscopic Liver Surgery: The Louisville Statement, 2008. *Ann. Surg.* **2009**, *250*, 825–830. [\[CrossRef\]](#)
- Wakabayashi, G.; Cherqui, D.; Geller, D.A.; Buell, J.F.; Kaneko, H.; Han, H.S.; Asbun, H.; O'Rourke, N.; Tanabe, M.; Koffron, A.J.; et al. Recommendations for Laparoscopic Liver Resection: A Report from the Second International Consensus Conference Held in Morioka. *Ann. Surg.* **2015**, *261*, 619–629. [\[PubMed\]](#)
- Hilal, M.A.; Aldrighetti, A.L.; Dagher, I.; Aroori, S.; Belli, A.A.G.; Besselink, M.; Briceno, J.; Gayet, B.; Hondt, M.D.; Lesurtel, M.; et al. The Southampton Consensus Guidelines for Laparoscopic Liver Surgery. *Ann. Surg.* **2018**, *268*, 11–18. [\[CrossRef\]](#)
- Giulianotti, P.C. Robotics in General Surgery. *Arch. Surg.* **2003**, *138*, 777. [\[CrossRef\]](#) [\[PubMed\]](#)
- Liu, R.; Wakabayashi, G.; Kim, H.-J.; Choi, G.-H.; Yiengpruksawan, A.; Fong, Y.; He, J.; Boggi, U.; Troisi, R.I.; Efanov, M.; et al. International Consensus Statement on Robotic Hepatectomy Surgery in 2018. *World J. Gastroenterol.* **2019**, *25*, 1432–1444. [\[CrossRef\]](#) [\[PubMed\]](#)
- Dalsgaard, T.; Jensen, M.D.; Hartwell, D.; Mosgaard, B.J.; Jørgensen, A.; Jensen, B.R. Robotic Surgery Is Less Physically Demanding Than Laparoscopic Surgery: Paired Cross Sectional Study. *Ann. Surg.* **2020**, *271*, 106–113. [\[CrossRef\]](#) [\[PubMed\]](#)
- Kingham, T.P.; Leung, U.; Kuk, D.; Gönen, M.; D'Angelica, M.I.; Allen, P.J.; Dematteo, R.P.; Laudone, V.P.; Jarnagin, W.R.; Fong, Y. Robotic Liver Resection: A Case-Matched Comparison. *World J. Surg.* **2016**, *40*, 1422–1428. [\[CrossRef\]](#)
- Choi, G.H.; Chong, J.U.; Han, D.H.; Choi, J.S.; Lee, W.J. Robotic Hepatectomy: The Korean Experience and Perspective. *Hepatobil. Surg. Nutr.* **2017**, *6*, 230–238. [\[CrossRef\]](#)
- Morel, P.; Jung, M.; Cornateanu, S.; Buehler, L.; Majno, P.; Toso, C.; Buchs, N.C.; Rubbia-Brandt, L.; Hagen, M.E. Robotic versus Open Liver Resections: A Case-Matched Comparison. *Int. J. Med. Robot. Comput. Assist. Surg.* **2017**, *13*, e1800. [\[CrossRef\]](#)
- Sucandy, I.; Giovannetti, A.; Ross, S.; Rosemurgy, A. Institutional First 100 Case Experience and Outcomes of Robotic Hepatectomy for Liver Tumors. *Am. Surg.* **2020**, *86*, 200–207. [\[CrossRef\]](#)
- Guan, R.; Chen, Y.; Yang, K.; Ma, D.; Gong, X.; Shen, B.; Peng, C. Clinical Efficacy of Robot-Assisted versus Laparoscopic Liver Resection: A Meta Analysis. *Asian J. Surg.* **2019**, *42*, 19–31. [\[CrossRef\]](#) [\[PubMed\]](#)
- Tsilimigras, D.I.; Moris, D.; Vagios, S.; Merath, K.; Pawlik, T.M. Safety and Oncologic Outcomes of Robotic Liver Resections: A Systematic Review. *J. Surg. Oncol.* **2018**, *117*, 1517–1530. [\[CrossRef\]](#) [\[PubMed\]](#)
- Ciria, R.; Berardi, G.; Alconchel, F.; Briceño, J.; Choi, G.H.; Wu, Y.M.; Sugioka, A.; Troisi, R.I.; Salloum, C.; Soubrane, O.; et al. The Impact of Robotics in Liver Surgery: A Worldwide Systematic Review and Short-Term Outcomes Meta-Analysis on 2,728 Cases. *J. Hepatobil. Pancreat. Sci.* **2020**, *29*, 181–197. [\[CrossRef\]](#)
- Lafaro, K.J.; Stewart, C.; Fong, A.; Fong, Y. Robotic Liver Resection. *Surg. Clin. N. Am.* **2020**, *100*, 265–281. [\[CrossRef\]](#)
- Feldbrügge, L.; Ortiz Galindo, S.A.; Frisch, O.; Benzing, C.; Krenzien, F.; Riddermann, A.; Kästner, A.; Nevermann, N.F.; Malinka, T.; Schöning, W.; et al. Safety and Feasibility of Robotic Liver Resection after Previous Abdominal Surgeries. *Surg. Endosc.* **2022**, *36*, 2842–2849. [\[CrossRef\]](#)
- Delvecchio, A.; Conticchio, M.; Riccelli, U.; Ferraro, V.; Ratti, F.; Gelli, M.; Anelli, F.M.; Laurent, A.; Vitali, G.C.; Magistri, P.; et al. Laparoscopic versus Open Liver Resection for Hepatocellular Carcinoma in Elderly Patients: A Propensity Score Matching Analysis. *HPB* **2022**, *24*, 933–941. [\[CrossRef\]](#)
- Dindo, D.; Clavien, P.A. What Is a Surgical Complication? *World J. Surg.* **2008**, *32*, 942–944. [\[CrossRef\]](#)
- Idrees, K.; Bartlett, D.L. Robotic Liver Surgery. *Surg. Clin. N. Am.* **2010**, *90*, 761–774. [\[CrossRef\]](#)
- Casciola, L.; Patriti, A.; Ceccarelli, G.; Bartoli, A.; Ceribelli, C.; Spaziani, A. Robot-Assisted Parenchymal-Sparing Liver Surgery Including Lesions Located in the Posterosuperior Segments. *Surg. Endosc.* **2011**, *25*, 3815–3824. [\[CrossRef\]](#) [\[PubMed\]](#)
- Kitisin, K.; Packiam, V.; Bartlett, D.L.; Tsung, A. A Current Update on the Evolution of Robotic Liver Surgery. *Minerva Chir.* **2011**, *66*, 281–293. [\[PubMed\]](#)
- Montalti, R.; Scuderi, V.; Patriti, A.; Vivarelli, M.; Troisi, R.I. Robotic versus Laparoscopic Resections of Posterosuperior Segments of the Liver: A Propensity Score-Matched Comparison. *Surg. Endosc.* **2016**, *30*, 1004–1013. [\[CrossRef\]](#) [\[PubMed\]](#)
- Szold, A.; Bergamaschi, R.; Broeders, I.; Dankelman, J.; Forgione, A.; Langø, T.; Melzer, A.; Mintz, Y.; Morales-Conde, S.; Rhodes, M.; et al. European Association of Endoscopic Surgeons (EAES) Consensus Statement on the Use of Robotics in General Surgery. *Surg. Endosc.* **2015**, *29*, 253–288. [\[CrossRef\]](#) [\[PubMed\]](#)
- Daskalaki, D.; Gonzalez-Heredia, R.; Brown, M.; Bianco, F.M.; Tzvetanov, I.; Davis, M.; Kim, J.; Benedetti, E.; Giulianotti, P.C. Financial Impact of the Robotic Approach in Liver Surgery: A Comparative Study of Clinical Outcomes and Costs between the Robotic and Open Technique in a Single Institution. *J. Laparoendosc. Adv. Surg. Tech.* **2017**, *27*, 375–382. [\[CrossRef\]](#)
- Chen, P.D.; Wu, C.Y.; Hu, R.H.; Chen, C.N.; Yuan, R.H.; Liang, J.T.; Lai, H.S.; Wu, Y.M. Robotic Major Hepatectomy: Is There a Learning Curve? *Surgery* **2017**, *161*, 642–649. [\[CrossRef\]](#) [\[PubMed\]](#)

25. Gravetz, A.; Sucandy, I.; Wilfong, C.; Patel, N.; Spence, J.; Ross, S.; Rosemurgy, A. Single-Institution Early Experience and Learning Curve with Robotic Liver Resections. *Am. Surg.* **2019**, *85*, 115–119. [[CrossRef](#)]
26. Heemskerk, J.; Van Gemert, W.G.; De Vries, J.; Greve, J.; Bouvy, N.D. Learning Curves of Robot-Assisted Laparoscopic Surgery Compared with Conventional Laparoscopic Surgery: An Experimental Study Evaluating Skill Acquisition of Robot-Assisted Laparoscopic Tasks Compared with Conventional Laparoscopic Tasks in Inexperienced. *Surg. Laparosc. Endosc. Percutaneous Tech.* **2007**, *17*, 171–174. [[CrossRef](#)] [[PubMed](#)]
27. Liu, L.; Wang, Y.; Wu, T.; Lin, J.; Deng, L.; Jiang, J.; An, T. Robotic versus Laparoscopic Major Hepatectomy for Hepatocellular Carcinoma: Short-Term Outcomes from a Single Institution. *BMC Surg.* **2022**, *22*, 432. [[CrossRef](#)] [[PubMed](#)]
28. Milone, M.; De'Angelis, N.; Beghdadi, N.; Brunetti, F.; Manigrasso, M.; De Simone, G.; Servillo, G.; Vertaldi, S.; De Palma, G.D. Conversions Related to Adhesions in Abdominal Surgery. Robotic versus Laparoscopic Approach: A Multicentre Experience. *Int. J. Med. Robot. Comput. Assist. Surg.* **2021**, *17*, e2186. [[CrossRef](#)] [[PubMed](#)]
29. Quijano, Y.; Vicente, E.; Ielpo, B.; Duran, H.; Diaz, E.; Fabra, I.; Malave, L.; Ferri, V.; Plaza, C.; Lindemann, J.L.; et al. Hepatobilio-Pancreatic Robotic Surgery: Initial Experience from a Single Center Institute. *J. Robot. Surg.* **2017**, *11*, 355–365. [[CrossRef](#)] [[PubMed](#)]
30. Machado, M.A.C.; Lobo-Filho, M.M.; Mattos, B.H.; Ardengh, A.O.; Makdissi, F.F. Robotic Liver Resection. Report of the First 50 Cases. *Arq. Gastroenterol.* **2021**, *58*, 514–519. [[CrossRef](#)] [[PubMed](#)]
31. Fruscione, M.; Pickens, R.; Baker, E.H.; Cochran, A.; Khan, A.; Ocuin, L.; Iannitti, D.A.; Vrochides, D.; Martinie, J.B. Robotic-Assisted versus Laparoscopic Major Liver Resection: Analysis of Outcomes from a Single Center. *HPB* **2019**, *21*, 906–911. [[CrossRef](#)]
32. Quijano, Y.; Vicente, E.; Ielpo, B.; Duran, H.; Diaz, E.; Fabra, I.; Olivares, S.; Ferri, V.; Ortega, I.; Malavé, L.; et al. Robotic Liver Surgery: Early Experience from a Single Surgical Center. *Surg. Laparosc. Endosc. Percutaneous Tech.* **2016**, *26*, 66–71. [[CrossRef](#)] [[PubMed](#)]
33. Bilimoria, K.Y.; Liu, Y.; Paruch, J.L.; Zhou, L.; Kmiecik, T.E.; Ko, C.Y.; Cohen, M.E. Development and Evaluation of the Universal ACS NSQIP Surgical Risk Calculator: A Decision Aid and Informed Consent Tool for Patients and Surgeons. *J. Am. Coll. Surg.* **2013**, *217*, 833–842.e3. [[CrossRef](#)] [[PubMed](#)]
34. Lee, K.F.; Cheung, Y.S.; Chong, C.C.N.; Wong, J.; Fong, A.K.W.; Lai, P.B.S. Laparoscopic and Robotic Hepatectomy: Experience from a Single Centre. *ANZ J. Surg.* **2016**, *86*, 122–126. [[CrossRef](#)] [[PubMed](#)]
35. Guerra, F.; Guadagni, S.; Pesi, B.; Furbetta, N.; Di Franco, G.; Palmeri, M.; Annecchiarico, M.; Eugeni, E.; Coratti, A.; Patriti, A.; et al. Outcomes of Robotic Liver Resections for Colorectal Liver Metastases. A Multi-Institutional Analysis of Minimally Invasive Ultrasound-Guided Robotic Surgery. *Surg. Oncol.* **2019**, *28*, 14–18. [[CrossRef](#)]

Disclaimer/Publisher's Note: The statements, opinions and data contained in all publications are solely those of the individual author(s) and contributor(s) and not of MDPI and/or the editor(s). MDPI and/or the editor(s) disclaim responsibility for any injury to people or property resulting from any ideas, methods, instructions or products referred to in the content.