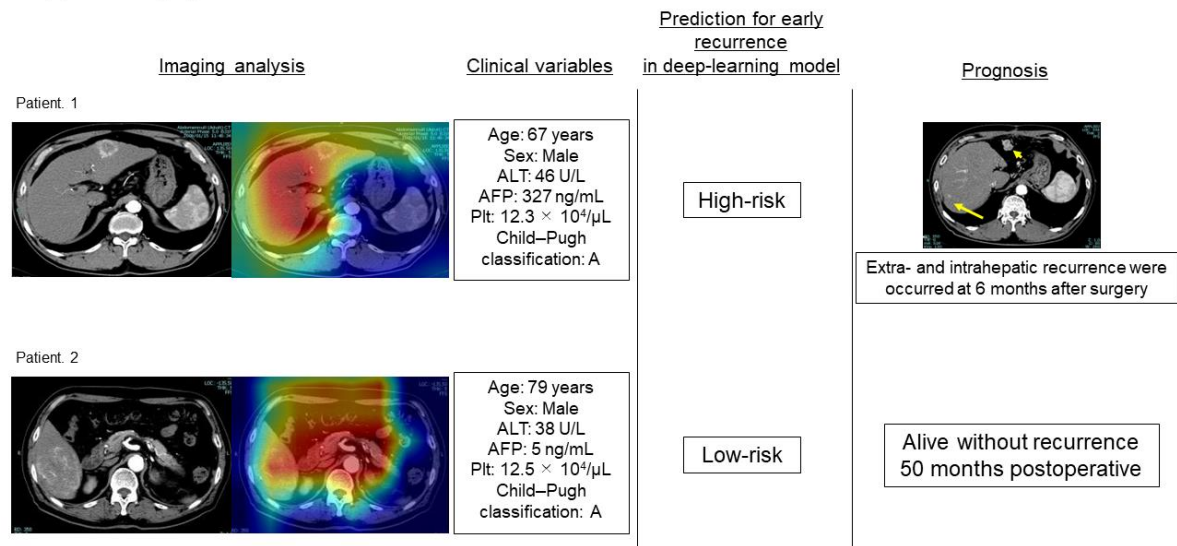


Supplementary figure



**Figure S1.** Preoperative clinical variables, including saliency maps and corresponding postoperative prognosis of two patients. In Patient 1 who was categorized into the high-risk group based on the DL model, intrahepatic recurrence (arrow) and peritoneal dissemination (short arrow) were detected in contrast-enhanced computed tomography at 6 months postoperative. Meanwhile, Patient 2, who was categorized into the low-risk group, has achieved recurrence-free survival for >2 years.