

Supplementary data:

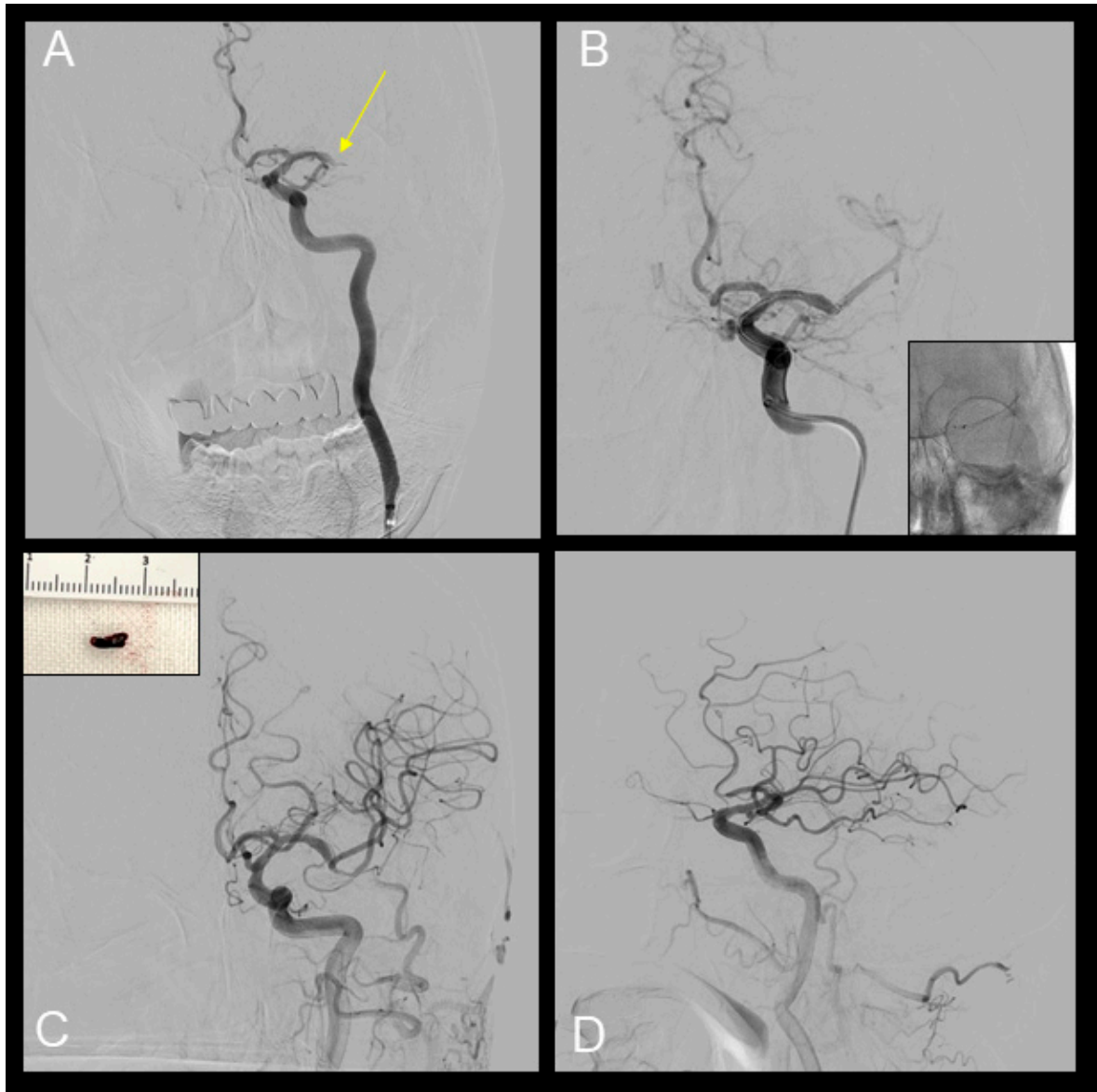

Figure S1. Mechanical thrombectomy of the left M1 occlusion. The Solitaire X stent device (4 mm × 40 mm; eV3, Irvine, CA, USA) and AXS Catalyst 6 aspiration catheter (Stryker Japan KK, Tokyo, Japan). (A) Left M1 occlusion (arrow). (B) The immediate flow restoration of one trunk of the left middle cerebral artery is achieved after deploying the stent retriever. (C, D) Final angiography shows full recanalization (modified thrombolysis in cerebral infarction grade 3) and the retrieved thrombus (C, Inset).

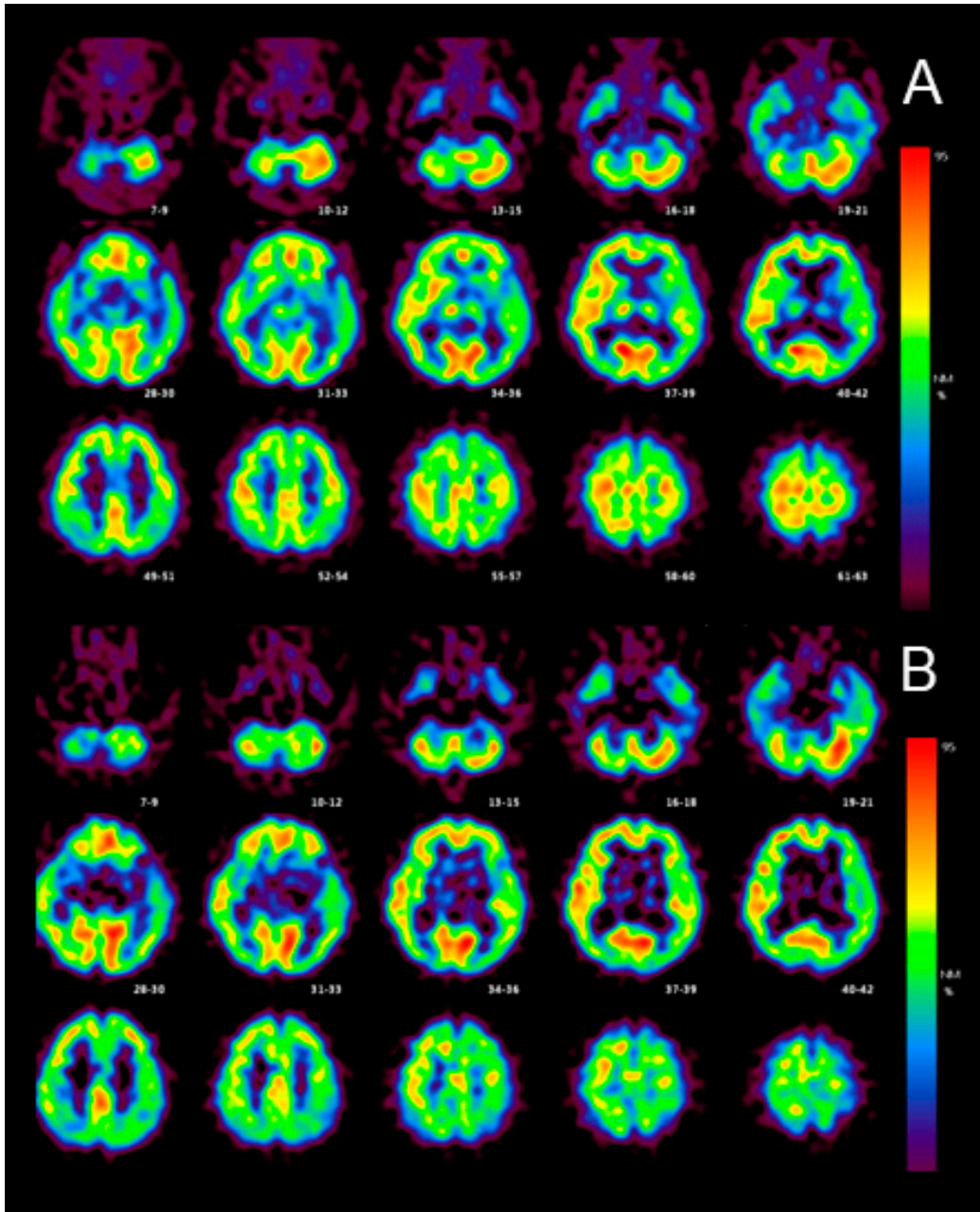


Figure S2. Original IMZ-SPECT images during the early phase (A) and late phase post-stroke (B).