

Review

A Review of MDA-5 Dermatomyositis and Associated Interstitial Lung Disease

Sambhawana Bhandari ^{1,*}, Lisa Zickuhr ^{1,†}, Maun Ranjan Baral ², Sanjeev Bhalla ³, Heather Jones ⁴, Robert Bucelli ⁵ and Deepali Sen ^{1,†}

¹ Division of Rheumatology, Department of Medicine, Washington University School of Medicine in St. Louis, St. Louis, MO 63110, USA; zickuhr@wustl.edu (L.Z.); dsen@wustl.edu (D.S.)

² Division of Hospital Medicine, Department of Medicine, Washington University School of Medicine in St. Louis, St. Louis, MO 63110, USA; maun@wustl.edu

³ Department of Radiology, Washington University in St. Louis, St. Louis, MO 63110, USA; sanjeevbhalla@wustl.edu

⁴ Meramec Dermatology, St. Louis, MO 63110, USA; hjones@meramecdermatology.com

⁵ Department of Neurology, Washington University in St. Louis, St. Louis, MO 63110, USA; bucellir@wustl.edu

* Correspondence: bhandaris@wustl.edu

† These authors contributed equally to this work.

Abstract: Anti-melanoma differentiation-associated gene 5 (MDA-5) dermatomyositis (DM) is noteworthy for its association with rapidly progressive interstitial lung disease (RP-ILD), vasculopathy, and distinctive cutaneous features. First identified in a Japanese cohort in 2005, MDA-5 DM carries a significant mortality risk, emphasizing the crucial need for early diagnosis. This review explores the pathogenesis, clinical presentation, diagnosis, management, and prognosis of MDA-5 DM and ILD and includes new research and recommendations regarding disease management.

Keywords: MDA-5 DM; MDA-5 DM ILD; MDA-5 antibody; RP-ILD; rapidly progressing interstitial lung disease



Citation: Bhandari, S.; Zickuhr, L.; Baral, M.R.; Bhalla, S.; Jones, H.; Bucelli, R.; Sen, D. A Review of MDA-5 Dermatomyositis and Associated Interstitial Lung Disease. *Rheumato* **2024**, *4*, 33–48. <https://doi.org/10.3390/rheumato4010004>

Academic Editor: Bruce M. Rothschild

Received: 31 January 2024

Revised: 10 February 2024

Accepted: 19 February 2024

Published: 28 February 2024



Copyright: © 2024 by the authors. Licensee MDPI, Basel, Switzerland. This article is an open access article distributed under the terms and conditions of the Creative Commons Attribution (CC BY) license (<https://creativecommons.org/licenses/by/4.0/>).

1. Introduction

Idiopathic inflammatory myopathies (IIMs) are a rare group of autoimmune diseases marked by a heterogeneous yet characteristic clinical spectrum of muscle inflammation, as well as rashes, arthritis, and other systemic findings. They often present alongside myositis-specific and myositis-associated antibodies (Abs). These Abs are associated with specific phenotypes and carry diagnostic and prognostic significance [1].

Anti-melanoma differentiation-associated gene 5 (MDA-5) dermatomyositis (DM) is a subtype of IIM that may present with rapidly progressive interstitial lung disease (RP-ILD), inflammatory arthritis, vasculopathy, and unique cutaneous manifestations [2,3]. It was first described by Sato et al. in 2005, based on a Japanese cohort with clinically amyopathic DM and RP-ILD [4]. People with MDA-5 DM suffer high mortality rates, emphasizing the importance of early clinical recognition, diagnosis, and treatment. The disease is more common in middle-aged women; however, mortality rates are higher among men [5–7]. Studies from the United States (US) have demonstrated that the condition favors women with a prevalence ranging from 56 to 73% and a mean age of 43 to 47 years at the time of diagnosis. When considering racial demographics, observations demonstrate a higher prevalence among individuals identifying as White, with percentages ranging from 48 to 87.5% [6,8].

2. Pathogenesis

Anti-melanoma differentiation-associated gene 5 is a retinoic acid-inducible gene-1 (RIG-1)-like receptor that functions in physiologic defenses against double-stranded ri-

bonucleic acid (dsRNA) viruses. Under normal circumstances, the MDA-5 receptor is a cytoplasmic pattern recognition receptor that binds viral dsRNA and triggers downstream type 1 interferon responses to suppress viral replication. For example, viral-MDA-5 complexes activate the mitochondrial antiviral signaling protein, which triggers the translocation of transcription factors such as interferon regulatory factors 3 and 7 into the nucleus. These transcription factors coordinate type 1 interferon production and, ultimately, virus-induced cell injury and lysis to prevent viral replication. The sequence naturally releases viral-MDA-5 complexes extracellularly, exposing them as antigens to antigen-presenting cells and lymphocytes and activating the adaptive immune response [2].

This antiviral defense cascade is thought to function atypically in cases of MDA-5 DM (Figure 1). Individuals with the HLA-DRB1 and WDFY4 haplotypes are genetically susceptible to developing MDA-5 DM. Among these individuals, antigen-presenting cells recognize viral-MDA-5 complexes but aberrantly prompt the production of auto-Abs against MDA-5 instead of activating protective adaptive immunity [2]. Both the dsRNA viral defense and MDA-5 DM pathogenesis pathways share underlying mechanisms, proposing viral infection as a potential trigger for MDA-5 DM [9].

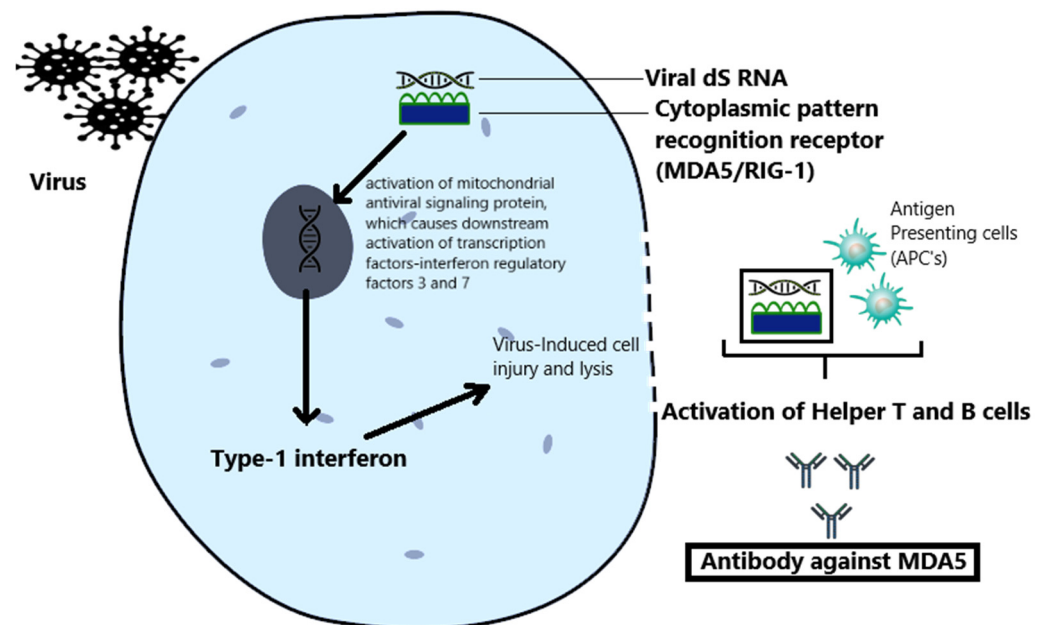


Figure 1. The proposed pathogenesis of MDA-5 DM. Infection with dsRNA viruses triggers an antiviral interferon response and the production of viral-MDA-5 complexes that turn on adaptive immunity. Among genetically susceptible people, the downstream type 1 interferon response and viral-MDA-5 complexes can activate T and B cells that aberrantly produce auto-Abs against MDA-5 and spur the generation of autoimmune MDA-5 DM.

Elevated levels of interferon type 1 play a central role in the vasculopathy and fibrosis of MDA-5 DM. Regarding vasculopathy, interferon type 1 increases the production of endothelin, which vasoconstricts vessels and contributes to the development of skin ulcers and digital necrosis observed among people with MDA-5 DM. Interferon type 1 also damages endothelial cells and triggers the release of factors like von Willebrand factor, which activate the coagulation cascade and the production of microthrombi, advancing the pathogenesis of vasculopathy. Moreover, it contributes to the fibrosis observed within MDA-5 DM through the activation of macrophages, the secretion of transforming growth factor- β , and the development of pulmonary fibrosis in the form of ILD [9].

3. Clinical Manifestations

Anti-MDA-5 DM was initially considered to be an amyopathic form of IIM associated with severe ILD, particularly in the Japanese population. Subsequent observations have

revealed a variety of manifestations that also include cutaneous and musculoskeletal presentations such as inverse Gottron's papules and inflammatory arthritis [2].

In 2020, Allenbach et al. categorized the manifestations of MDA-5 DM in the form of clusters.

- Cluster 1, MDA-5 RP-ILD type, presents primarily with lung disease and mechanic's hands. This phenotype has a poor prognosis and increased need for intensive care.
- Cluster 2, MDA-5 rheumatic DM type, is more common in women, presents with inflammatory arthralgias and arthritis, and has a positive prognosis. This phenotype has a lower incidence of skin lesions, myositis, and RP-ILD.
- Cluster 3, MDA-5 vasculopathy DM type, carries an intermediate prognosis and is associated with the cutaneous vasculopathy findings of Raynaud's phenomenon, digital necrosis, and calcinosis alongside an increased incidence of myositis [10].

4. Lung Involvement

Interstitial lung disease is a common manifestation in MDA-5 DM. In a study by Koga et al, 94% of patients from a Japanese cohort with MDA-5 DM had ILD, and 71% had RP-ILD. The mortality rate was 41%, and the most common cause was RP-ILD [11]. Studies conducted in the US have shown varied MDA-5 ILD incidences and prognoses. A cohort by Hall et al. reported milder cases of ILD with good response to immunosuppressive therapy [5]. On the contrary, a study by Moghadam-Kia et al. showed a higher incidence of ILD (50%), the majority (87.5%) of which developed RP-ILD and suffered a high mortality rate (72%) [12]. A potential consequence of lung fibrosis, pneumomediastinum, is a known, life-threatening complication of MDA-5 DM RP-ILD, occurring in 8% of patients with MDA-5 DM and associated with the use of non-invasive pressure ventilation [2,6].

Organizing pneumonia (OP), non-specific interstitial pneumonia (NSIP), and usual interstitial pneumonia (UIP) are radiographic patterns of ILD described in MDA-5 DM (Figure 2). In a study of 329 patients by Chen et al., OP was the most common (43.2%), followed by NSIP (26.4%) and combined NSIP+OP (18.5%). UIP was the least common pattern in this study (0.6%). Patients with MDA-5 RP-ILD showed a higher prevalence of NSIP+OP and a lower prevalence of NSIP compared to people with MDA-5 ILD (not RP-ILD) [13].

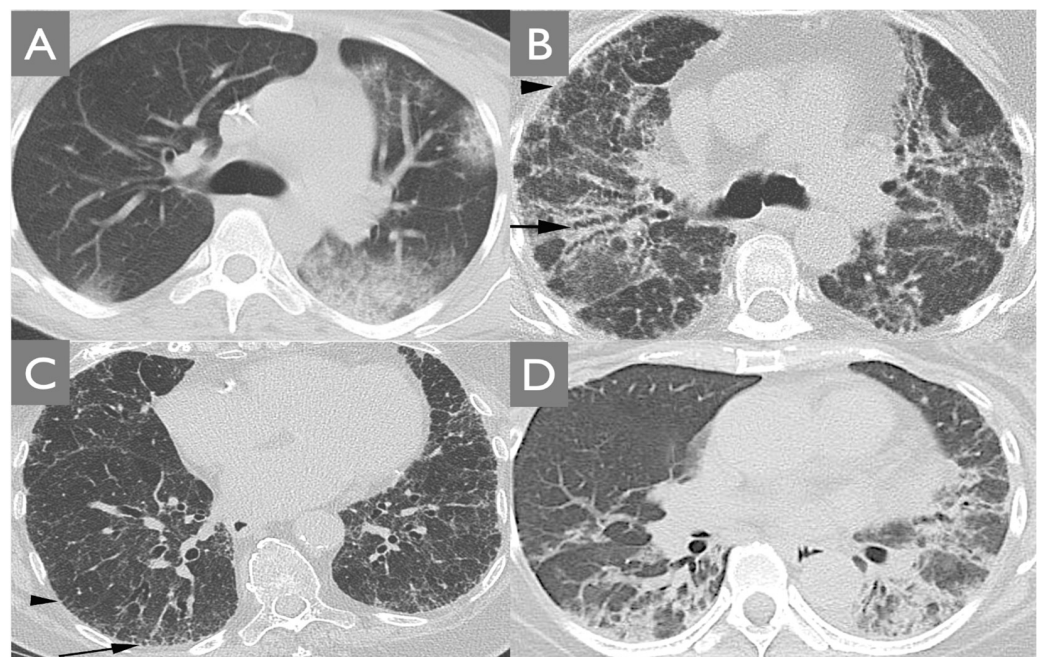


Figure 2. Radiographic patterns of ILD associated with MDA-5 DM. (A) The organizing pneumonia (OP) pattern presents with peripheral areas of ground glass and consolidation. (B) The non-specific

interstitial pneumonia (NSIP) contains varicoid traction bronchiectasis surrounded by ground-glass opacity (arrow) and peripheral reticulation (arrowhead). (C) The usual interstitial pneumonia pattern manifests with reticulation (arrowhead) and honeycombing (arrow). (D) MDA-5 DM RP-ILD most commonly presents with a combination of NSIP + OP patterns.

5. Skin Manifestations

MDA-5 DM presents with the classical cutaneous signs of DM, including Gottron's papules, shawl sign, and heliotrope rash (Figure 3) [14]. Additionally, MDA-5 DM manifests with an inverse Gottron's sign (Figures 4 and 5B) that appears as keratotic papules in the skin folds of the palms and fingers [15]. The underlying vasculopathy of MDA-5 DM can cause digital necrosis, mucocutaneous ulcerations, and ulcerated Gottron's papules (Figure 5). Necrosis can rapidly expand, causing complications such as gangrene and digital amputation [16]. Calcinosis is another well-described finding associated with longer disease duration and fingertip ulcers [17]. Less commonly, case reports demonstrate diffuse ichthyosis, perinasal edema, and erythema [18,19].

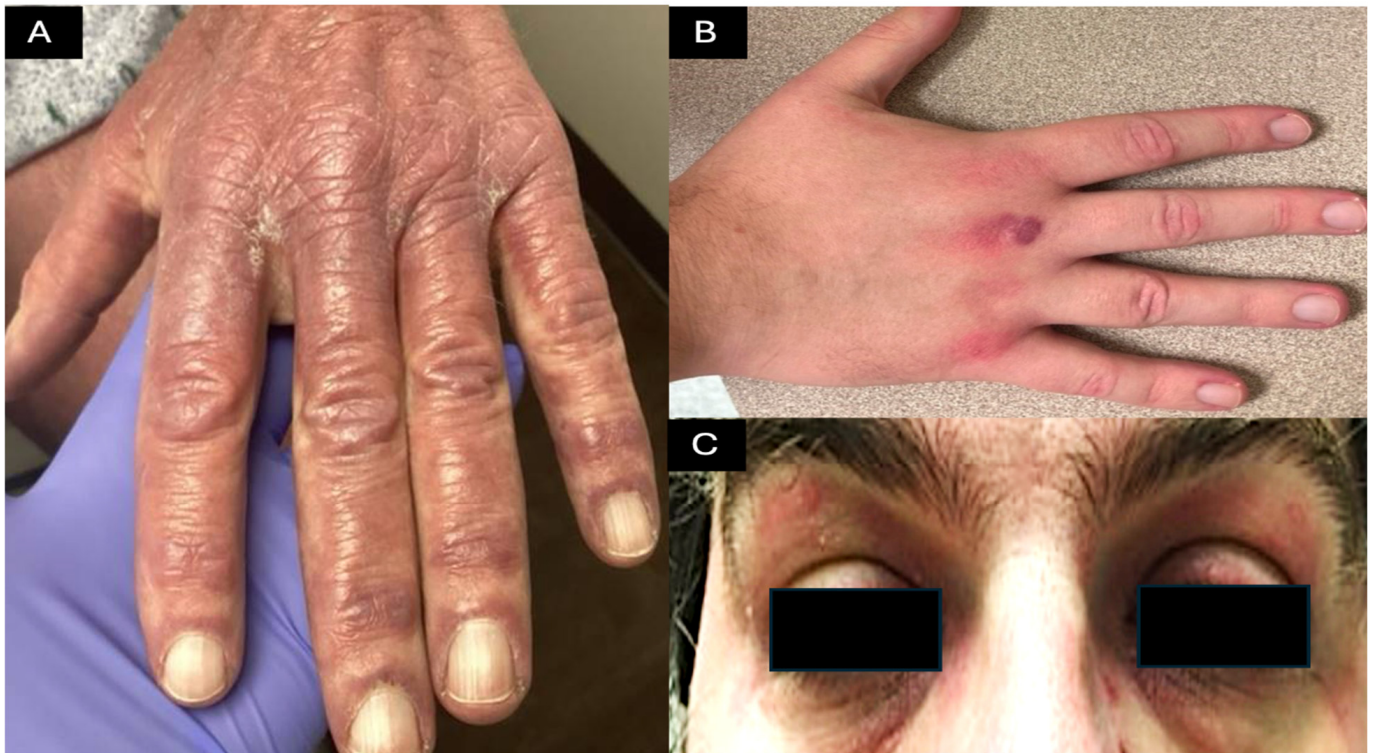

Figure 3. Classic features of dermatomyositis: (A,B) Gottron's papules appear as violaceous papules on the skin overlying the joints on the dorsum of the hand. (C) Heliotrope rash manifests as plaques on the upper eyelids and may be associated with periorbital edema. These skin findings are a form of interface dermatitis and present with a violaceous hue in skin of color (A) while appearing more erythematous in fair skin tones (B,C).

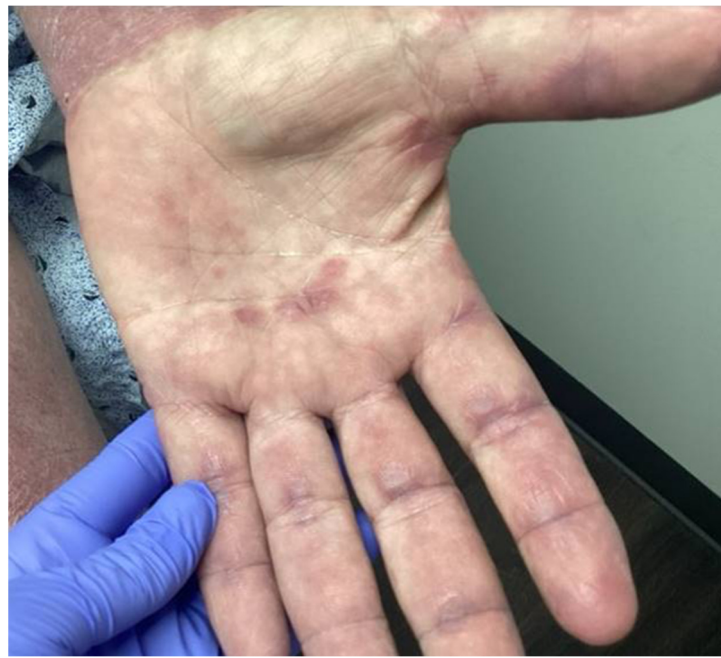

Figure 4. Inverse Gottron's sign: unique to MDA-5 DM, inverse Gottron's sign presents as keratotic, palmar papules in the skin folds of the palms and fingers.

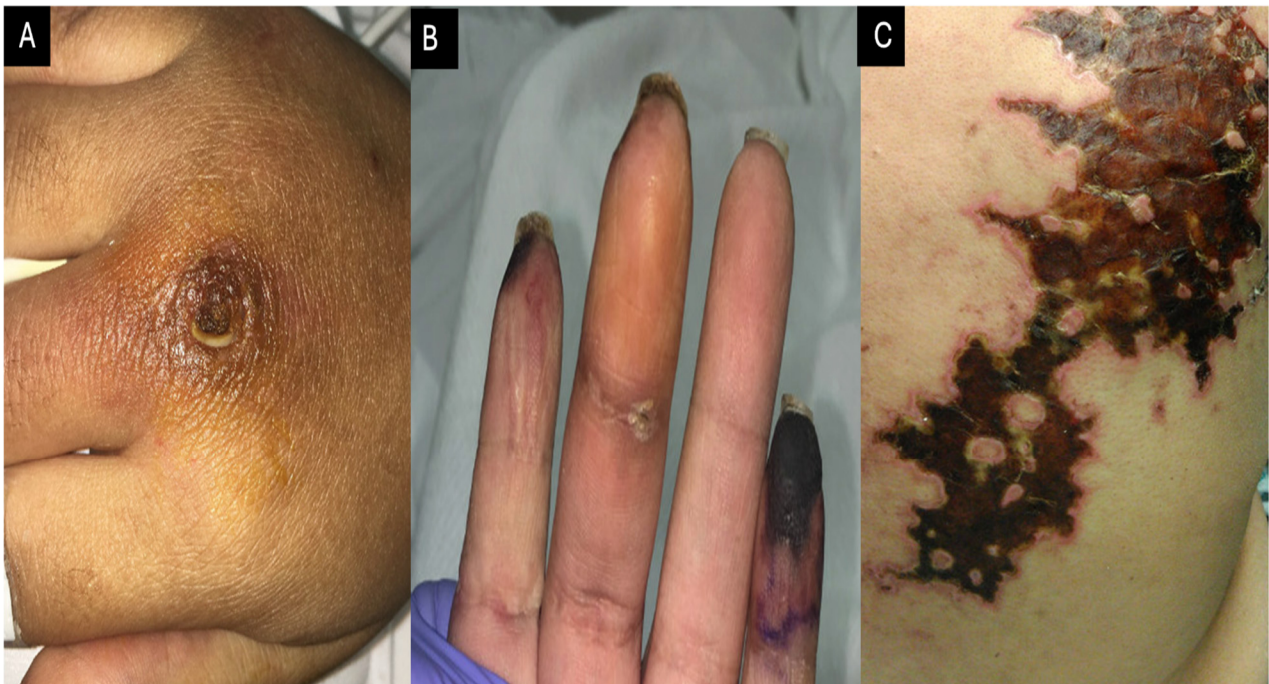

Figure 5. Cutaneous vasculopathy in MDA-5 DM: The vasculopathy of MDA-5 DM causes ulcerated Gottron's papules (A) as well as digital (B) and mucocutaneous (C) necrosis. Additionally, image B depicts inverse Gottron's papules on the palmar aspect of the third proximal interphalangeal joint.

6. Muscle Involvement

The degree of inflammatory muscle disease is heterogeneous among patient populations. Initial observations of MDA-5 DM described muscle involvement as amyopathic in 80% of Japanese patients [4]. Compared to the Japanese population, at times, US cohort data demonstrate similar amyopathic DM prevalences and, at other times, show higher rates of

inflammatory myositis with MDA-5 DM [5,8]. A Brazilian study reported an incidence of amyopathic DM similar to that of Japanese patients (80%) [20].

7. Inflammatory Arthritis

Individuals with MDA-5 auto-Abs may present with a symmetric inflammatory polyarthropathy in small joints, which is frequently clinically indistinguishable from rheumatoid arthritis [5].

8. Others

The characterization of MDA-5 is relatively recent, and new signs and symptoms are being discovered. For example, one case report describes fever of unknown origin and autoimmune hepatitis as the first presenting features of MDA-5 DM [21].

9. Similarity to COVID-19

SARS-CoV-2 and MDA-5 DM share similarities in their pathogenic mechanisms. While SARS-CoV-2 is classified as a single-stranded RNA virus, it evolves into a dsRNA virus early during the infection cycle, thereby activating MDA-5 and its downstream type 1 interferon signaling [22]. Both SARS-CoV-2 infection and MDA-5 DM exhibit endothelial injury and thrombotic manifestations, especially in cases of severe disease [9]. Additionally, the imaging findings of ground-glass opacities and predominantly lower lung subpleural consolidations are common between the two diseases [23]. Instances of MDA-5 DM have been reported in case studies following infection or immunization for SARS-CoV-2, further supporting a proposed shared pathogenic mechanism [24,25].

10. Association with Cancer

The potential association between anti-MDA-5 Abs and malignancy has been explored through multiple cohort studies, revealing varying outcomes in different populations. Japanese cohort studies have not found any association between anti-MDA-5 Abs and malignancy [11]. Conversely, a single case report presented a potential link between anti-MDA-5 Abs and cervical cancer [26]. Meanwhile, a French cohort study reported a 7.6% association between malignancy and MDA-5 DM, which was much lower than the prevalence of paraneoplastic cases of MDA-5 negative DM [10].

11. Diagnosis

Suspicion of MDA-5 DM should arise when patients present with characteristic skin rashes, vasculopathy, inflammatory arthritis, and RP-ILD. Clinical diagnosis can be supported with the detection of anti-MDA-5 Abs using various laboratory methods, including immunoprecipitation, immunoassay, or enzyme-linked immunosorbent assay [2]. Ro52 Abs, commonly identified in individuals positive for anti-Jo-1, are present in 27–55% of those with positive anti-MDA-5 Abs. Studies have shown that the levels of Ro52 Abs are inversely related to survival time, emphasizing their potential prognostic significance [27,28]. Antinuclear Abs are often elevated as well, while Jo-1 Abs, strongly associated with the antisynthetase syndrome, appear to not be detected in MDA-5 DM patients [2,5].

As in all cases of IIM, any person with suspected or confirmed MDA-5 DM should undergo screening for ILD. Screening includes high-resolution computed tomography (HRCT) in combination with pulmonary function testing (PFT) [29]. HRCT findings (mainly NSIP+OP or OP patterns) can progress within weeks in cases of RP-ILD; therefore, the timing of surveillance imaging and PFT studies should reflect patients' risk factors for RP-ILD. For example, we recommend screening a patient with features characteristic of cluster 1, such as mechanic's hands, along with an older age and elevated ferritin, for lung involvement more frequently than someone with characteristics of cluster 2 (e.g., a woman with MDA-5 DM and inflammatory arthritis). Progression within the first 3 months is significant for RP-ILD, and we recommend very close monitoring during this period.

Because of heterogeneous muscle involvement among people with MDA-5 DM, muscular diagnostic evaluation results may vary. Electromyography can be normal or show muscle irritability, and magnetic resonance imaging of the proximal muscles might show muscle edema [5]. When present, histopathologic features of muscle biopsy are often subtle, mild, and include the absence of perifascicular fiber atrophy, features of vasculopathy such as membrane attack complex deposition on capillaries as well as capillary rarefaction, and minimal inflammation in the perimysium (Figure 6) [30]. These findings appear at distinct foci within the muscle tissue, at times necessitating multiple biopsies to detect histopathology [31,32].

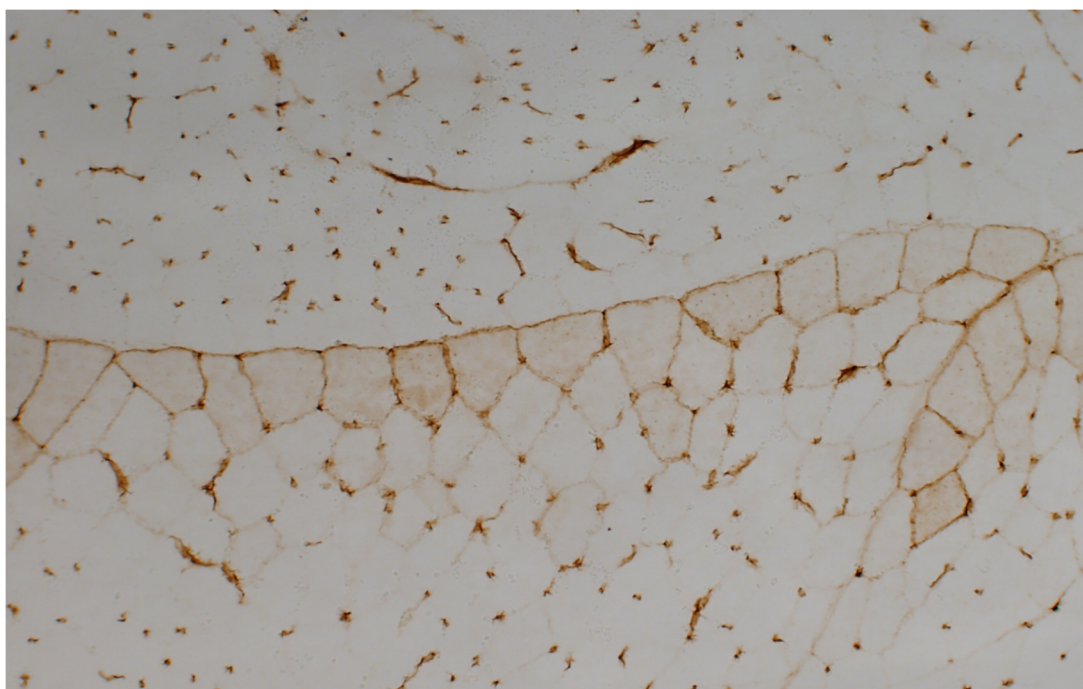


Figure 6. Histopathology of MDA-5 DM: Histopathological analysis of muscle tissue staining for membrane histocompatibility complex (MHC) class I reveals a distinctive perifascicular immune myopathy. Notably, a heightened expression of MHC class I occurs exclusively along the periphery of the fascicle, accentuating the subtle and mild histopathologic characteristics observed in MDA-5 DM.

12. Prognosis

Patients with MDA-5 DM have increased mortality at six months as well as at five years in comparison to patients with MDA-5 Ab-negative DM [11]. A study by Liu et al. investigated the difference in mortality rate specifically between patients with anti-MDA-5 and anti-Jo-1 Ab who presented with IIM and ILD. The mortality rate in the anti-MDA-5 Ab group (1.95/person-year [PY]) was much higher than that in the anti-Jo-1 Ab group (0.094/PY). Most mortalities occurred within the first three months of diagnosis [33]. Age greater than 45 years old at diagnosis and biomarkers (described below) have been associated with increased mortality, particularly among male patients aged older than 54 years old [8,34].

Fortunately, emerging data suggest that for patients with MDA-5 DM ILD who survive the initial acute illness, long-term prognosis may improve regarding ILD progression and survival rates. A Japanese study by Ida et al. showed a mortality rate of 25.9% during the first phase of treatment (induction). Patients who survived induction achieved subsequent five-year survival and relapse-free rates of 96.8% and 77.4%, respectively, with 7.9% of patients sustaining drug-free remission [35]. Similarly, the survival rate among 52 patients from the US with MDA-5 DM was 90%, 18% of whom were in drug-free remission following a median follow-up period of 3.5 years [6].

13. Biomarkers

Indicators of disease activity play a crucial role in managing MDA-5 DM in light of its propensity for severe disease. Various biomarkers have been reported as helpful for monitoring disease activity and treatment effects.

- (a) **Ferritin:** Serum ferritin is a marker of inflammation and macrophage activation. A high serum ferritin level (>1000 ng/mL) is closely associated with a high incidence of RP-ILD and mortality among people with MDA-5 DM [11,36,37].
- (b) **Anti-MDA-5 Ab:** Studies have shown that serum levels of anti-MDA-5 Abs are significantly higher in people who develop RP-ILD than in those who do not [8]. A decrease in anti-MDA-5 Ab levels has been associated with longer remission in some studies [38]. Another Japanese study suggests that monitoring anti-MDA-5 Ab levels could be useful in predicting the risk of relapse during the remission maintenance phase [35]. However, two US studies found no correlation between MDA-5 Ab titers and the disease course [5,6]. More studies are necessary to determine the clinical relevance of this potential association.
- (c) **Krebs von den Lungen-6 (KL-6):** Elevated serum KL-6 levels are produced by regenerating alveolar type II pneumocytes and are thought to be associated with impaired alveolar–capillary barriers. Reflecting the severity of ILD and its progression, they are associated with increased mortality in people with MDA-5 DM ILD [39]. This test is commercially available but not widely used in clinical practice.
- (d) **Type 1 interferon:** Studies have shown that the absolute type 1 interferon score is directly proportional to ILD, muscle inflammation, and skin disease activity among people with MDA-5 DM [40].
- (e) **Peripheral lymphocyte counts:** A decline in peripheral lymphocyte counts among individuals in MDA-5 DM ILD was associated with poor prognosis [41].
- (f) **Ro52 Ab:** A study revealed an inverse correlation between the levels of Ro52 Abs and survival time, underscoring the potential prognostic importance of these antibodies [28].

The field of rheumatology is in its early stages of identifying prognostic markers for MDA-5 DM. Additional markers under current investigation include C-reactive protein (CRP), Surfactant protein D, Serum Neopterin, and IL-10 levels [2,39,42]. We look forward to the results of these studies and learning how to best apply prognostic markers to patient care.

14. Management

Medical evidence lacks studies, particularly randomized controlled trials (RCTs), focused on the management of MDA-5 DM ILD. The prevailing consensus is to combine immunosuppressive therapies early in the disease trajectory because of the risk of RP-ILD, which contributes to substantial morbidity and mortality within the first three months of diagnosis [3,43]. In a comprehensive review of 134 studies conducted by Bueno et al. in 2020, a specialized task force formulated recommendations regarding the management of MDA-5 DM RP-ILD [43].

14.1. “Hit it Hard”/Triple Therapy

Consensus recommendations propose the primary utilization of combined immunosuppressive therapy with high-dose glucocorticoids and calcineurin inhibitors (CNIs) with or without cyclophosphamide (CYC) over step-up therapy as the initial choice for treatment [43]. In a study by Matsushita et al., the combination of 1 mg/kg Prednisone, Tacrolimus dosed to a target trough of 5–10 ng/mL, and intravenous (IV) CYC over a mean of 6.8 months resulted in RP-ILD remission in 12 of 12 studied cases [38]. In a cohort of 29 patients studied by Tsuji et al., the same treatment regimen yielded significantly higher six-month survival rates compared to the step-up treatment group (89% versus 33%, $p < 0.0001$) [44]. Nakashima et al. employed a similar treatment approach using cy-

cyclosporine instead of tacrolimus, observing an astonishing survival rate of 75% among 14 patients with MDA-5 DM ILD. This stands in stark contrast to a group of 14 historical controls with anti-MDA-5 Ab who underwent conventional step-up therapy with a lower survival rate of 28.6% [45].

On the other hand, a recent study by Ida et al. suggests that triple therapy may not be needed for all MDA-5 DM cases and that disease severity could guide a more nuanced approach to induction. They classified patients as “non severe” if they had ILD (not RP-ILD) or a ferritin < 1000 ng/mL and found that six-month survival was similar with or without triple therapy induction [35]. Additional outcomes studies will help clinicians best tailor induction therapy to their patients’ MDA-5 DM manifestations. For the time being, our current practice is to initiate triple therapy in patients who have ILD or evidence of high inflammatory markers including ferritin.

Calcineurin inhibitors: Calcineurin inhibitors are a component of first-line triple therapy for MDA-5 DM RP-ILD. Go et al. studied 47 people with MDA-5-positive or MDA-5-negative DM ILD and demonstrated a survival advantage with early cyclosporine treatment. Even after adjusting for factors such as age, degree of dyspnea, and clinically amyopathic DM status, the survival benefit of early cyclosporine treatment remained statistically significant, with a hazard ratio of 0.057 (95% confidence interval 0.007–0.472). Furthermore, the early treatment group demonstrated stabilized ILD on HRCT [46].

Data support the use of either cyclosporine or tacrolimus for MDA-5 DM ILD and RP-ILD at doses of 3–5 mg/kg/day of cyclosporine (target trough 150–200 ng/mL) or 0.075 mg/kg/day of tacrolimus (target trough 5–10 ng/mL) [44,47]. Clinicians must consider safety profile and patient comorbidities when choosing between cyclosporine and tacrolimus [43]. For example, adverse events like gingival hyperplasia and hirsutism, as well as hyperlipidemia, are greater among people taking cyclosporine [48].

Glucocorticoids: The dose of steroids used in many studies is intravenous (IV) methylprednisolone pulse (1000 mg for 3 days) vs. 0.75–1 mg/kg of Prednisone for 4 weeks followed by a gradual taper every 2–4 weeks [2,3,38,45]. High-dose glucocorticoids are a common component of induction protocols in many inflammatory conditions.

Intravenous Cyclophosphamide: In the context of triple therapy, studies propose the administration of IV CYC in doses ranging from 300 to 1000 mg/m² every 2–4 weeks, with a recommended total of one to six doses [45,47].

14.2. Other Therapies Described in the Literature

Rituximab: Rituximab (RTX) presents a treatment option for many with MDA-5 DM ILD. A retrospective case series of 11 people with MDA-5 DM, 8 of whom had RP-ILD, who were treated with RTX demonstrated a favorable response in 73% of the cohort. Furthermore, 18% of cases with mild ILD achieved complete remission, and 55% benefited from improvement in lung HRCT and/or PFTs. About one-fourth (27%) succumbed during the follow-up period, with two patients dying from worsening ILD and one from concomitant RP-ILD and lung infection [27]. In another study by Mao et al., RTX infusion showed pronounced and prolonged B-cell depletion associated with a significant decrease in MDA-5 Ab titers, which may be associated with a greater chance of ILD remission [27,42]. Doses of RTX administered in clinical studies include 375 mg/m² at 0 and 14 days and 100 mg weekly for 4 weeks, providing evidence supporting a variety of dosing schedules that can be tailored to patients’ specific needs.

JAK inhibitors: Tofacitinib is beneficial as an adjunct to glucocorticoid therapy in cases of ILD (not RP-ILD) associated with anti-MDA-5 Ab positivity, particularly in the early stages. Tofacitinib has demonstrated efficacy, safety, and good tolerability, along with survival benefits. Survival six months after the onset of ILD was found to be significantly higher among people with MDA-5 DM ILD who received tofacitinib (18 of 18, 100%) compared to those in the control group who did not receive tofacitinib therapy (25 of 32, 78%) ($p = 0.04$). Additionally, studies show improvement in HRCT and PFT findings among people with MDA-5 DM ILD who take tofacitinib [49].

Plasma exchange: Plasma exchange (PE) can provide salvage therapy when people with MDA-5 DM RP-ILD fail to respond to the aforementioned conventional therapies. For example, Shirakashi et al. studied individuals with MDA-5 RP-ILD who experienced accelerated disease progression despite triple therapy. PE emerged as a crucial intervention, with a cumulative survival rate of 62.5% for PE recipients ($N = 8$), in stark contrast to a 0% survival rate for those without PE ($N = 5$). Patients who continued to survive at the six-month mark exhibited noteworthy reductions in KL-6, ferritin, and anti-MDA-5 Ab titers compared to baseline levels. Factors that predicted a benefit from PE included elevated serum ferritin levels, advanced age, severe pulmonary dysfunction, and higher HRCT scores [50]. Similarly, research by Abe et al. focused on individuals with RP-ILD resistant to standard immunosuppressive therapies such as oral prednisolone, IV methylprednisolone pulses, IV CYC, and CNIs. The one-year survival rate in the PE group ($N = 6$) (100%) was significantly higher than the non-PE group ($N = 4$) (25%) [51].

Intravenous Immunoglobulin: A study by Femia et al. investigated the clinical response of refractory cutaneous DM in patients with classic and amyopathic DM treated with intravenous immunoglobulin (IVIG). All patients showed improvement, with 8/13 achieving a complete clinical response. IVIG had a rapid effect on cutaneous erosions and ulcerations [52]. This favorable response to IVIG has also been supported in other case reports [53].

Antifibrotic therapy: In a prospective study by Li et al., 30 people with RP-ILD (both anti-MDA-5 Ab positive (84.6%) and negative DM) received the antifibrotic treatment pirfenidone (target dose of 1800 mg/d) alongside standard treatment, while 27 retrospective controls did not. The pirfenidone group showed a trend towards lower mortality (36.7% vs. 51.9%, $p = 0.2226$). Subgroup analysis revealed no impact on people with acute ILD (defined as duration of ILD less than three months) but significantly improved survival in subacute ILD (defined as duration of ILD three-to-six months) (90% vs. 44.4%, $p = 0.0450$), suggesting that pirfenidone may enhance prognosis for subacute ILD related to amyopathic DM (including subacute MDA-5 DM ILD) [54].

Others: Mycophenolate mofetil and polymyxin B hemoperfusion are treatment alternatives mentioned in the literature [26,43,55]. However, per consensus recommendations, methotrexate, leflunomide, infliximab, and azathioprine should not be used for induction therapy [43]. This slightly differs from the American College of Rheumatology's guidelines for treating ILD in systemic autoimmune rheumatic diseases, with the latter providing a conditional recommendation for azathioprine as a first-line option for ILD treatment and reinforcing the advice to avoid methotrexate, leflunomide, and infliximab as first-line options [29]. Table 1 presents a summary of the details of dosages and common side effects.

Lung transplantation: Lung transplantation emerges as a promising treatment avenue for individuals in the advanced stages of MDA-5-DM RP-ILD, especially when initial immunosuppression fails. There is a speculative notion that DM ILD is triggered by factors like viral infections or smoking, causing a disruption in self-tolerance and prompting an autoimmune reaction. According to this view, if a patient undergoes lung transplantation, the removal of the source of autoantigens would lead to the vanishing of the anti-MDA-5 Abs and the prevention of a recurrence of ILD symptoms [56]. Bueno et al. and recent other studies recommend early referral for transplant eligibility assessment at the time of ILD diagnosis [43,57,58].

In a report of two cases of MDA-5 DM RP-ILD by Lian et al., one patient showcased successful rehabilitation, marked by a gradual reduction and subsequent negativity of the anti-MDA-5 Ab in the days following lung transplantation. Conversely, the second patient succumbed to respiratory failure, attributed to a flare of MDA-5 DM RP-ILD in the transplanted lungs. Diffuse ground-glass opacities appeared in the HRCT images of both the native and transplanted lungs alongside elevated anti-MDA-5 Ab titers in the early post-lung transplantation phase. These cases suggest that achieving a decline in, or complete clearance of, the anti-MDA-5 Ab may be necessary to prevent the recurrence of DM and RP-ILD in patients after transplantation [59]. Although not yet studied, the use of

PE in the peri-transplant period might be an important adjunct therapy because it facilitates the clearance of anti-MDA-5 Abs.

Table 1. A comprehensive overview of the dosages and common side effects for therapies used in MDA-5 DM ILD.

Medications	Dose *	Side Effects
Calcineurin inhibitors	Cyclosporine: 3–5 mg/kg/day (target trough 150–200 ng/mL) Tacrolimus: 0.075 mg/kg/day (target trough 5–10 ng/mL) [44,47]	Cyclosporine: Hyperglycemia, gingival hyperplasia, thrombotic microangiopathy, hepatotoxicity, hyperkalemia, hypertension, hirsutism, hyperlipidemia, nephrotoxicity Tacrolimus: Similar to cyclosporine, reduced risk of gingival hyperplasia and hirsutism
Glucocorticoids	IV methylprednisolone pulse (1000 mg for 3 days) or 0.75–1 mg/kg Prednisone for 4 weeks followed by gradual taper every 2–4 weeks [2,3,38,45]	May lead to increased risk of infections, osteoporosis, hyperglycemia, hypertension, mood changes, weight gain
Cyclophosphamide	300–1000 mg/m ² IV every 2–4 weeks, recommended total of one to six doses [45,47]	Bone marrow suppression, infection risk, infertility, hemorrhagic cystitis
Rituximab	375 mg/m ² at 0 and 14 days or 100 mg weekly for 4 weeks [27,42]	Infusion-related reactions, hypogammaglobulinemia and increased infection risk, reactivation of hepatitis B, progressive multifocal leukoencephalopathy
JAK inhibitors	Tofacitinib: 5 mg twice daily [49]	Bone marrow suppression, increased cardiovascular risk, gastrointestinal perforation, increased risk of infections, liver enzyme abnormalities
Plasma exchange	1–3 times/week for 3–15 weeks (1–1.3 volumes of plasma removed per session and replaced with fresh frozen plasma) [50]	Vascular access related-bleeding, infection, thrombosis, replacement-related complications: dyspnea, pruritus, urticaria, fever, tachycardia
Intravenous immunoglobulin	2 g/kg every 4 weeks, given as 1 g/kg/day for 2 consecutive days [52]	Generally well tolerated but potential for headache, nausea, allergic reactions, elevated liver enzymes, chest pain, tachycardia, hypertension
Antifibrotic Therapy	Pirfenidone: target dose of 1800 mg/day (started at 200 mg tid and was increased to the target dose of 600 mg tid over a 2-week period [54])	Nausea, fatigue, rash, diarrhea, elevated liver enzymes

* Trough levels (if applicable).

Extracorporeal membrane oxygenation can transitionally support patients waiting for a clinical response to intensive immunosuppressive therapy or lung transplantation [57,59]. It is regarded as the ultimate therapeutic recourse for hypoxic respiratory failure when standard treatments prove ineffective, serving exclusively as an interim measure until a definitive resolution of the underlying cause of respiratory failure can be implemented [43].

Prognosis after lung transplantation is varied. Some studies report survival with a good prognosis of more than 12 years post lung transplantation [56]. However, complications including infections and DM flare with RP-ILD post-transplant have also been described [57,59]. The recurrence of disease post-transplantation and monitoring guidelines (imaging and Ab measurement) are intriguing topics that require larger studies, preferably RCTs with multi-center collaborations.

15. Summary of Treatment Guidelines

Figure 7 below is a flowchart that summarizes treatment guidelines.

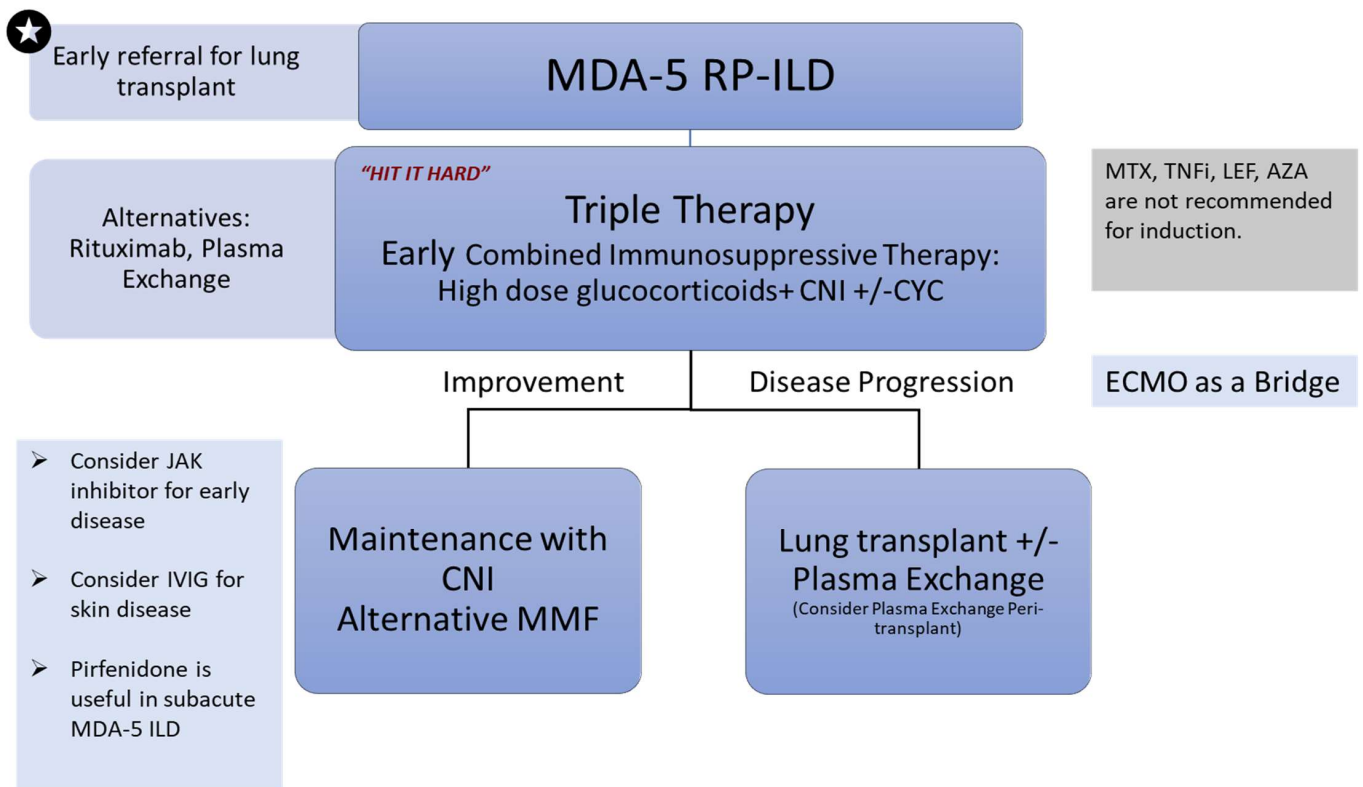


Figure 7. Summary of MDA-5 RP-ILD management. Following the diagnosis of MDA-5 RP-ILD, combination immunosuppressive therapy is recommended, along with early referral to a lung transplant center. The administration of high-dose glucocorticoids in conjunction with calcineurin antagonists (CNIs)+/– cyclophosphamide (CYC) is the recommended combination therapy, with rituximab and plasma exchange as alternatives. Extracorporeal membrane oxygenation (ECMO) is used as a bridge to lung transplant in severe cases. Maintenance with CNI/Mycophenolate mofetil (MMF) is advised. Janus kinase (JAK) inhibitors for early disease, intravenous immunoglobulin for skin disease, and pirfenidone for subacute MDA-5 DM ILD are recommended.

16. Conclusions and Future Directions

Anti-melanoma differentiation-associated gene 5 DM is a subtype of IIM that presents with a wide range of manifestations, including RP-ILD, inflammatory arthritis, vasculopathy, and unique cutaneous findings. Early diagnosis and treatment are essential for patient outcomes because of MDA-5 DM's association with RP-ILD and high mortality rates, particularly in the first six months of the disease.

Findings of characteristic skin manifestations and vasculopathy should alert clinicians to the possibility of RP-ILD. If ILD is found in this setting, early treatment should be prescribed even while awaiting serologies. RP-ILD can progress in weeks, and we recommend the frequent monitoring of clinical symptoms, ferritin levels, and chest imaging following diagnosis and treatment initiation. The prognoses associated with different phenotypic clusters of MDA-5 DM, as well as markers like ferritin and Ro52 Abs, may help with risk stratification and allow for a more tailored approach to monitoring and therapy.

Triple therapy, combining CNIs, glucocorticoids, and other immunosuppressants, benefits survival among people with MDA-5 DM RP-ILD and should be instituted as early as possible when this condition is suspected. Further studies are needed to understand whether patients with milder phenotypes can be treated safely with less aggressive regimens. Recent data suggest that a subset of patients may achieve drug-free remission over time.

Some people with MDA-5 DM RP-ILD progress despite aggressive immunosuppression, prompting the consideration of early referral for lung transplantation in the setting of

RP-ILD. The management of patients in the post-transplant period remains challenging because of the paucity of data on long-term outcomes, relapse rates, and the best strategies for monitoring and treating relapse in patients who have undergone lung transplantation. For those awaiting transplantation, therapies such as immunomodulation and PE should be instituted in discussion with the transplant team.

Recent studies have significantly enhanced our understanding of disease manifestations and therapeutics in MDA-5 DM. Further studies are needed to better understand etiopathogenesis, especially the role of anti-MDA-5 Ab. Clinicians would most benefit from discovering biomarkers that can predict which patients are at risk of RP-ILD, thereby helping to direct the intensity of treatment. Further studies are also needed to consolidate treatment guidelines, especially in reference to the different phenotypes of MDA-5 DM.

MDA-5 DM remains a challenging disease to diagnose and manage, in part because of its varied manifestations. Therefore, an enhanced awareness of MDA-5 DM, increased multidisciplinary approaches to care, and the early application of evidence-based therapeutics could help improve patient outcomes.

Author Contributions: Conceptualization, S.B. (Sambhawana Bhandari), L.Z. and D.S.; writing—original draft preparation, S.B. (Sambhawana Bhandari), L.Z., S.B. (Sanjeev Bhalla), M.R.B., H.J., R.B. and D.S.; writing—S.B. (Sambhawana Bhandari), L.Z., M.R.B. and D.S. All authors have read and agreed to the published version of the manuscript.

Funding: This research received no external funding.

Institutional Review Board Statement: Not applicable.

Informed Consent Statement: Written informed consent has been obtained for pictures containing patient-identifying information.

Data Availability Statement: Not applicable.

Conflicts of Interest: The authors declare no conflicts of interest.

Abbreviations

DM	Dermatomyositis
ILD	Interstitial lung disease
RP-ILD	Rapidly progressive interstitial lung disease
IIMs	Idiopathic inflammatory myopathies
MDA-5	Anti-melanoma differentiation-associated gene 5
Ab	antibody
RIG-1	Retinoic acid-inducible gene-1
IFIH1	Interferon-induced helicase C domain-containing protein 1
ds RNA	double-stranded ribonucleic acid
ELISA	Enzyme-linked immunosorbent assay
HRCT	High resolution computed tomography
CNI	Calcineurin inhibitor
JAK	Janus kinase
IVIG	Intravenous immunoglobulin
ECMO	Extracorporeal membrane oxygenation
RCT	Randomized controlled trial
PFT	Pulmonary function test

References

1. Lundberg, I.E.; Fujimoto, M.; Vencovsky, J.; Aggarwal, R.; Holmqvist, M.; Christopher-Stine, L.; Mammen, A.L.; Miller, F.W. Idiopathic inflammatory myopathies. *Nat. Rev. Dis. Primer.* **2021**, *7*, 86. [[CrossRef](#)]
2. Mehta, P.; Machado, P.M.; Gupta, L. Understanding and managing anti-MDA 5 dermatomyositis, including potential COVID-19 mimicry. *Rheumatol. Int.* **2021**, *41*, 1021–1036. [[CrossRef](#)]

3. McPherson, M.; Economidou, S.; Liampas, A.; Zis, P.; Parperis, K. Management of MDA-5 antibody positive clinically amyopathic dermatomyositis associated interstitial lung disease: A systematic review. *Semin. Arthritis Rheum.* **2022**, *53*, 151959. [CrossRef] [PubMed]
4. Autoantibodies to a 140-kd polypeptide, CADM-140, in Japanese patients with clinically amyopathic dermatomyositis. *Arthritis Rheum.* **2005**, *52*, 1571–1576. [CrossRef]
5. Hall, J.C.; Casciola-Rosen, L.; Samedy, L.; Werner, J.; Owoyemi, K.; Danoff, S.K.; Christopher-Stine, L. Anti-Mda5-Associated Dermatomyositis: Expanding the Clinical Spectrum. *Arthritis Care Res.* **2013**, *65*, 1307–1315. [CrossRef]
6. Tiniakou, E.; Mecoli, C.A.; Kelly, W.; Albayda, J.; Paik, J.; Adler, B.; Lin, C.T.; Mammen, A.L.; Danoff, S.K.; Casciola-Rosen, L.; et al. Anti-MDA5-positive dermatomyositis and remission in a single referral centre population. *Clin. Exp. Rheumatol.* **2023**, *41*, 309–315. Available online: <https://www.clinexprheumatol.org/abstract.asp?a=19287> (accessed on 23 January 2024). [CrossRef]
7. Cheng, L.; Xu, L.; Xu, Y.; Yuan, F.; Li, J.; Wu, M.; Da, Z.; Wei, H.; Zhou, L.; Yin, S.; et al. Gender differences in patients with anti-MDA5-positive dermatomyositis: A cohort study of 251 cases. *Clin. Rheumatol.* **2024**, *43*, 339–347. [CrossRef] [PubMed]
8. Moghadam-Kia, S.; Oddis, C.V.; Sato, S.; Kuwana, M.; Aggarwal, R. Antimelanoma Differentiation-associated Gene 5 Antibody: Expanding the Clinical Spectrum in North American Patients with Dermatomyositis. *J. Rheumatol.* **2017**, *44*, 319–325. [CrossRef] [PubMed]
9. Nombel, A.; Fabien, N.; Coutant, F. Dermatomyositis with Anti-MDA5 Antibodies: Bioclinical Features, Pathogenesis and Emerging Therapies. *Front. Immunol.* **2021**, *12*, 773352. Available online: <https://www.frontiersin.org/articles/10.3389/fimmu.2021.773352> (accessed on 7 January 2024). [CrossRef]
10. Allenbach, Y.; Uzunhan, Y.; Toquet, S.; Leroux, G.; Gallay, L.; Marquet, A.; Meyer, A.; Guillaud, C.; Limal, N.; Gagnadoux, F.; et al. Different phenotypes in dermatomyositis associated with anti-MDA5 antibody. *Neurology* **2020**, *95*, e70–e78. [CrossRef] [PubMed]
11. Koga, T.; Fujikawa, K.; Horai, Y.; Okada, A.; Kawashiri, S.-Y.; Iwamoto, N.; Suzuki, T.; Nakashima, Y.; Tamai, M.; Arima, K.; et al. The diagnostic utility of anti-melanoma differentiation-associated gene 5 antibody testing for predicting the prognosis of Japanese patients with DM. *Rheumatology* **2012**, *51*, 1278–1284. [CrossRef]
12. Moghadam-Kia, S.; Oddis, C.V.; Sato, S.; Kuwana, M.; Aggarwal, R. Anti-Melanoma Differentiation-Associated Gene 5 Is Associated with Rapidly Progressive Lung Disease and Poor Survival in US Patients with Amyopathic and Myopathic Dermatomyositis. *Arthritis Care Res.* **2015**, *68*, 689–694. [CrossRef]
13. Chen, X.; Jiang, W.; Jin, Q.; Peng, Q.; Zhang, L.; Lin, S.; Lu, X.; Liu, M.; Wang, Y.; Song, A.; et al. Clinical, radiological and pathological features of anti-MDA5 antibody-associated interstitial lung disease. *RMD Open* **2023**, *9*, e003150. [CrossRef] [PubMed]
14. Alqahtani, N.; Aleissa, M. Cutaneous Features of Anti-MDA-5 Antibody-Positive Amyopathic Dermatomyositis in a Sudanese Patient. *Case Rep. Dermatol.* **2021**, *13*, 481–485. [CrossRef] [PubMed]
15. Suda, T. Inverse Gottron's sign in anti-MDA5 dermatomyositis. *QJM Int. J. Med.* **2023**, head250. [CrossRef] [PubMed]
16. Charbit, L.; Bursztejn, A.-C.; Mohamed, S.; Kaminsky, P.; Lerondeau, B.; Barbaud, A.; Deibener-Kaminsky, J.; Schmutz, J.-L. Nécroses digitales étendues au cours d'une dermatomyosite avec anticorps anti-MDA-5. *Ann. Dermatol. Vénéréologie* **2016**, *143*, 537–542. [CrossRef] [PubMed]
17. Valenzuela, A.; Chung, L.; Casciola-Rosen, L.; Fiorentino, D. Identification of clinical features and autoantibodies associated with calcinosis in dermatomyositis. *JAMA Dermatol.* **2014**, *150*, 724–729. [CrossRef] [PubMed]
18. Girard, C.; Vincent, T.; Bessis, D. Dermatomyositis and acute interstitial lung disease associated with MDA-5 antibodies: An atypical case. *Ann. Dermatol. Venereol.* **2013**, *140*, 628–634. [CrossRef] [PubMed]
19. Molina, E.; Christopher-Stine, L.; Albayda, J. On the Nose: Anti-MDA-5 Dermatomyositis Manifesting as Perinasal Swelling. *Case Rep. Dermatol.* **2022**, *14*, 1–5. [CrossRef] [PubMed]
20. Truzzi, N.C.C.; Hoff, L.S.; Borges, I.B.P.; de Souza, F.H.C.; Shinjo, S.K. Clinical manifestations, outcomes, and antibody profile of Brazilian adult patients with dermatomyositis: A single-center longitudinal study. *Adv. Rheumatol. Lond. Engl.* **2022**, *62*, 41. [CrossRef]
21. Mangal, V.; Hegde, A.; Hasvi, J.; Harikrishnan, P.; Kumar, A.; Goel, N.; Menon, A.S. Fever of Unknown Origin and Hepatitis as the Initial Presentation of Anti-MDA-5 Positive Dermatomyositis: A Case Report. *Mediterr. J. Rheumatol.* **2022**, *33*, 361–367. [CrossRef] [PubMed]
22. Li, Y.; Renner, D.M.; Comar, C.E.; Whelan, J.N.; Reyes, H.M.; Cardenas-Diaz, F.L.; Truitt, R.; Tan, L.H.; Dong, B.; Alysandratos, K.D.; et al. SARS-CoV-2 induces double-stranded RNA-mediated innate immune responses in respiratory epithelial-derived cells and cardiomyocytes. *Proc. Natl. Acad. Sci. USA* **2021**, *118*, e2022643118. [CrossRef] [PubMed]
23. Wang, Y.; Du, G.; Zhang, G.; Matucci-Cerinic, M.; Furst, D.E. Similarities and differences between severe COVID-19 pneumonia and anti-MDA-5-positive dermatomyositis-associated rapidly progressive interstitial lung diseases: A challenge for the future. *Ann. Rheum. Dis.* **2022**, *81*, e192. [CrossRef] [PubMed]
24. Wang, S.; Noumi, B.; Malik, F.; Wang, S. A Rare Case of MDA-5-Positive Amyopathic Dermatomyositis with Rapidly Progressive Interstitial Lung Disease Following COVID-19 mRNA Vaccination—A Case Report. *Sn Compr. Clin. Med.* **2023**, *5*, 18. [CrossRef] [PubMed]
25. Anderle, K.; Machold, K.; Kiener, H.P.; Bormann, D.; Hoetzenecker, K.; Geleff, S.; Prosch, H.; Laccone, F.; Heil, P.M.; Petzelbauer, P.; et al. COVID-19 as a putative trigger of anti-MDA5-associated dermatomyositis with acute respiratory distress syndrome (ARDS) requiring lung transplantation, a case report. *BMC Rheumatol.* **2022**, *6*, 42. [CrossRef] [PubMed]

26. Ichiyasu, H.; Sakamoto, Y.; Yoshida, C.; Sakamoto, K.; Fujita, R.; Nakayama, G.; Okabayashi, H.; Saeki, S.; Okamoto, S.; Kohrog, H. Rapidly progressive interstitial lung disease due to anti-MDA-5 antibody-positive clinically amyopathic dermatomyositis complicated with cervical cancer: Successful treatment with direct hemoperfusion using polymyxin B-immobilized fiber column therapy. *Respir. Med. Case Rep.* **2016**, *20*, 51–54. [\[CrossRef\]](#)
27. Ge, Y.; Li, S.; Tian, X.; He, L.; Lu, X.; Wang, G. Anti-melanoma differentiation-associated gene 5 (MDA5) antibody-positive dermatomyositis responds to rituximab therapy. *Clin. Rheumatol.* **2021**, *40*, 2311–2317. [\[CrossRef\]](#)
28. Wang, H.; Chen, X.; Du, Y.; Wang, L.; Wang, Q.; Wu, H.; Liu, L.; Xue, J. Mortality risk in patients with anti-MDA5 dermatomyositis is related to rapidly progressive interstitial lung disease and anti-Ro52 antibody. *Arthritis Res. Ther.* **2023**, *25*, 127. [\[CrossRef\]](#)
29. Interstitial Lung Disease Clinical Practice Guidelines. Available online: <https://rheumatology.org/interstitial-lung-disease-guideline> (accessed on 17 January 2024).
30. Nguyen, M.; Do, V.; Yell, P.C.; Jo, C.; Liu, J.; Burns, D.K.; Wright, T.; Cai, C. Distinct tissue injury patterns in juvenile dermatomyositis auto-antibody subgroups. *Acta Neuropathol. Commun.* **2020**, *8*, 125. [\[CrossRef\]](#)
31. Yasin, S.A.; Schutz, P.W.; Deakin, C.T.; Sag, E.; Varsani, H.; Simou, S.; Marshall, L.R.; Tansley, S.L.; McHugh, N.J.; Holton, J.L.; et al. Histological heterogeneity in a large clinical cohort of juvenile idiopathic inflammatory myopathy: Analysis by myositis autoantibody and pathological features. *Neuropathol. Appl. Neurobiol.* **2019**, *45*, 495–512. [\[CrossRef\]](#)
32. Allenbach, Y.; Leroux, G.; Suárez-Calvet, X.; Preusse, C.; Gallardo, E.; Hervier, B.; Rigolet, A.; Hie, M.; Pehl, D.; Limal, N.; et al. Dermatomyositis With or Without Anti-Melanoma Differentiation-Associated Gene 5 Antibodies: Common Interferon Signature but Distinct NOS2 Expression. *Am. J. Pathol.* **2016**, *186*, 691–700. [\[CrossRef\]](#)
33. Liu, C.H.; Kor, C.T.; Hung, M.H.; Hsiao, K.H.; Cheng, Y.H.; Tien, Y.C. Differences in the Clinical Characteristics and 1-Year Mortality Rates of Patients with Dermatomyositis with anti-Jo-1 and anti-MDA5 Antibodies. *J. Immunol. Res.* **2023**, *2023*, 2988422. [\[CrossRef\]](#)
34. He, S.; Zhou, Y.; Fan, C.; Ma, J.; Chen, Y.; Wu, W.; Zhang, X. Differences in sex- and age-associated mortality in patients with anti-MDA5-positive dermatomyositis. *Mod. Rheumatol.* **2023**, *33*, 975–981. [\[CrossRef\]](#)
35. Ida, I.; Furuta, S.; Fujiwara, M.; Hiraguri, M.; Hirose, K.; Ikeda, K.; Iwamoto, T.; Kagami, S.-I.; Kobayashi, Y.; Kurasawa, K.; et al. Short-term and long-term outcomes of patients with anti-melanoma differentiation-associated gene 5 antibody-positive dermatomyositis. *Rheumatology* **2024**, keae011. [\[CrossRef\]](#) [\[PubMed\]](#)
36. Yang, Q.; Lyu, K.; Li, J.; Zhang, P.; Guan, W.; Zhang, L.; Han, L.; Liu, S.; Li, T. Anti-melanoma differentiation-associated 5 gene antibody-positive dermatomyositis exhibit three clinical phenotypes with different prognoses. *Clin. Exp. Rheumatol.* **2022**, *40*, 304–308. Available online: <https://www.clinexprheumatol.org/abstract.asp?a=17825> (accessed on 17 December 2023). [\[CrossRef\]](#)
37. Li, X.; Liu, Y.; Cheng, L.; Huang, Y.; Yan, S.; Li, H.; Zhan, H.; Li, Y. Roles of biomarkers in anti-MDA5-positive dermatomyositis, associated interstitial lung disease, and rapidly progressive interstitial lung disease. *J. Clin. Lab. Anal.* **2022**, *36*, e24726. [\[CrossRef\]](#)
38. Matsushita, T.; Mizumaki, K.; Kano, M.; Yagi, N.; Tennichi, M.; Takeuchi, A.; Okamoto, Y.; Hamaguchi, Y.; Murakami, A.; Hasegawa, M.; et al. Antimelanoma differentiation-associated protein 5 antibody level is a novel tool for monitoring disease activity in rapidly progressive interstitial lung disease with dermatomyositis. *Br. J. Dermatol.* **2017**, *176*, 395–402. [\[CrossRef\]](#) [\[PubMed\]](#)
39. Gono, T.; Masui, K.; Nishina, N.; Kawaguchi, Y.; Kawakami, A.; Ikeda, K.; Kirino, Y.; Sugiyama, Y.; Tanino, Y.; Nunokawa, T.; et al. Risk Prediction Modeling Based on a Combination of Initial Serum Biomarker Levels in Polymyositis/Dermatomyositis-Associated Interstitial Lung Disease. *Arthritis Rheumatol.* **2021**, *73*, 677–686. [\[CrossRef\]](#) [\[PubMed\]](#)
40. Tabata, M.M.; Hodgkinson, L.M.; Wu, T.T.; Li, S.; Huard, C.; Zhao, S.; Bennett, D.; Johnson, J.; Tierney, C.; He, W.; et al. The Type I Interferon Signature Reflects Multiple Phenotypic and Activity Measures in Dermatomyositis. *Arthritis Rheumatol.* **2023**, *75*, 1842–1849. [\[CrossRef\]](#)
41. Ren, F.-P.; Chen, Q.; Yao, S.-S.; Feng, L.; Xue, X.-Y.; Zhao, W.-C.; Wang, D.; Zhao, Z.-L.; Gu, S.-W.; Li, T.; et al. Characteristics and prognostic implications of peripheral blood lymphocyte subsets in patients with anti-MDA5 antibody positive dermatomyositis-interstitial lung disease. *BMC Pulm. Med.* **2023**, *23*, 411. [\[CrossRef\]](#)
42. Mao, M.-M.; Xia, S.; Guo, B.-P.; Qian, W.-P.; Zheng, Z.-X.; Peng, X.-M.; Chen, R.-C.; Luo, Q.; Han, Q. Ultra-low dose rituximab as add-on therapy in anti-MDA5-positive patients with polymyositis /dermatomyositis associated ILD. *Respir. Med.* **2020**, *172*, 105983. [\[CrossRef\]](#) [\[PubMed\]](#)
43. Romero-Bueno, F.; del Campo, P.D.; Trallero-Araguás, E.; Ruiz-Rodríguez, J.; Castellvi, I.; Rodríguez-Nieto, M.; Martínez-Becerra, M.; Sanchez-Pernaute, O.; Pinal-Fernandez, I.; Solanich, X.; et al. Recommendations for the treatment of anti-melanoma differentiation-associated gene 5-positive dermatomyositis-associated rapidly progressive interstitial lung disease. *Semin. Arthritis Rheum.* **2020**, *50*, 776–790. [\[CrossRef\]](#) [\[PubMed\]](#)
44. Tsuji, H.; Nakashima, R.; Hosono, Y.; Imura, Y.; Yagita, M.; Yoshifuji, H.; Hirata, S.; Nojima, T.; Sugiyama, E.; Hatta, K.; et al. Multicenter Prospective Study of the Efficacy and Safety of Combined Immunosuppressive Therapy With High-Dose Glucocorticoid, Tacrolimus, and Cyclophosphamide in Interstitial Lung Diseases Accompanied by Anti-Melanoma Differentiation-Associated Gene 5-Positive Dermatomyositis. *Arthritis Rheumatol.* **2020**, *72*, 488–498. [\[CrossRef\]](#) [\[PubMed\]](#)
45. Nakashima, R.; Hosono, Y.; Mimori, T. Clinical significance and new detection system of autoantibodies in myositis with interstitial lung disease. *Lupus* **2016**, *25*, 925–933. [\[CrossRef\]](#) [\[PubMed\]](#)
46. Go, D.J.; Park, J.K.; Kang, E.H.; Kwon, H.M.; Lee, Y.J.; Song, Y.W.; Lee, E.B. Survival benefit associated with early cyclosporine treatment for dermatomyositis-associated interstitial lung disease. *Rheumatol. Int.* **2016**, *36*, 125–131. [\[CrossRef\]](#)

47. Fujisawa, T. Management of Myositis-Associated Interstitial Lung Disease. *Medicina* **2021**, *57*, 347. [[CrossRef](#)] [[PubMed](#)]
48. Krämer, B.K.; Montagnino, G.; del Castillo, D.; Margreiter, R.; Sperschneider, H.; Olbricht, C.J.; Krüger, B.; Ortuño, J.; Köhler, H.; Kunzendorf, U.; et al. Efficacy and safety of tacrolimus compared with cyclosporin A microemulsion in renal transplantation: 2 year follow-up results. *Nephrol. Dial. Transplant.* **2005**, *20*, 968–973. [[CrossRef](#)] [[PubMed](#)]
49. Chen, Z.; Wang, X.; Ye, S. Tofacitinib in Amyopathic Dermatomyositis—Associated Interstitial Lung Disease. *N. Engl. J. Med.* **2019**, *381*, 291–293. [[CrossRef](#)] [[PubMed](#)]
50. Shirakashi, M.; Nakashima, R.; Tsuji, H.; Tanizawa, K.; Handa, T.; Hosono, Y.; Akizuki, S.; Murakami, K.; Hashimoto, M.; Yoshifuji, H.; et al. Efficacy of plasma exchange in anti-MDA5-positive dermatomyositis with interstitial lung disease under combined immunosuppressive treatment. *Rheumatology* **2020**, *59*, 3284–3292. [[CrossRef](#)]
51. Abe, Y.; Kusaoi, M.; Tada, K.; Yamaji, K.; Tamura, N. Successful treatment of anti-MDA5 antibody-positive refractory interstitial lung disease with plasma exchange therapy. *Rheumatology* **2020**, *59*, 767–771. [[CrossRef](#)]
52. Femia, A.N.; Eastham, A.B.; Lam, C.; Merola, J.F.; Qureshi, A.A.; Vleugels, R.A. Intravenous immunoglobulin for refractory cutaneous dermatomyositis: A retrospective analysis from an academic medical center. *J. Am. Acad. Dermatol.* **2013**, *69*, 654–657. [[CrossRef](#)]
53. Stager, K.; Wise, L. MDA-5 dermatomyositis complicated by interstitial lung disease and cutaneous ulcers: Successful treatment with corticosteroids, mycophenolate mofetil and intravenous immunoglobulin. *BMJ Case Rep.* **2020**, *13*, e236431. [[CrossRef](#)]
54. Li, T.; Guo, L.; Chen, Z.; Gu, L.; Sun, F.; Tan, X.; Chen, S.; Wang, X.; Ye, S. Pirfenidone in patients with rapidly progressive interstitial lung disease associated with clinically amyopathic dermatomyositis. *Sci. Rep.* **2016**, *6*, 33226. [[CrossRef](#)] [[PubMed](#)]
55. Okabayashi, H.; Ichiyasu, H.; Hirooka, S.; Akaike, K.; Kojima, K.; Jodai, T.; Sakamoto, Y.; Ideguchi, H.; Hamada, S.; Yoshida, C.; et al. Clinical effects of direct hemoperfusion using a polymyxin B-immobilized fiber column in clinically amyopathic dermatomyositis-associated rapidly progressive interstitial pneumonias. *BMC Pulm. Med.* **2017**, *17*, 134. [[CrossRef](#)]
56. Leclair, V.; Labirua-Iturburu, A.; Lundberg, I.E. Successful Lung Transplantation in a Case of Rapidly Progressive Interstitial Lung Disease Associated with Antimelanoma Differentiation-associated Gene 5 Antibodies. *J. Rheumatol.* **2018**, *45*, 581–583. [[CrossRef](#)] [[PubMed](#)]
57. Huang, K.; Levy, R.D.; Avina-Zubieta, J.A. Successful lung transplant in rapid progressive interstitial lung disease associated with anti-melanoma differentiation associated gene 5. *Rheumatology* **2020**, *59*, 2161–2163. [[CrossRef](#)] [[PubMed](#)]
58. Rapidly progressive interstitial lung disease due to anti-melanoma differentiation associated protein-5 requiring a bilateral lung transplant, and complicated by kennel cough. *Respir. Med. Case Rep.* **2019**, *28*, 100886. [[CrossRef](#)]
59. Lian, Q.-Y.; Chen, A.; Zhang, J.-H.; Xu, X.; Huang, D.-X.; Luo, Q.; He, J.-X.; Ju, C.-R. Lung transplantation for anti-MDA5-positive dermatomyositis-associated rapid progressive interstitial lung disease: Report of two cases and review of the literature. *Clin. Rheumatol.* **2023**, *42*, 941–947. [[CrossRef](#)]

Disclaimer/Publisher’s Note: The statements, opinions and data contained in all publications are solely those of the individual author(s) and contributor(s) and not of MDPI and/or the editor(s). MDPI and/or the editor(s) disclaim responsibility for any injury to people or property resulting from any ideas, methods, instructions or products referred to in the content.