






Review

Complications in Acute Myocardial Infarction: Navigating Challenges in Diagnosis and Management

Errol Moras ¹, Shreyas Yakkali ², Kruti D. Gandhi ¹, Hafeez Ul Hassan Virk ³, Mahboob Alam ⁴, Syed Zaid ⁴, Nitin Barman ⁵, Hani Jneid ⁶, Saraschandra Vallabhajosyula ⁷, Samin K. Sharma ⁸ and Chayakrit Krittanawong ^{9,*}

- ¹ Department of Medicine, Icahn School of Medicine at Mount Sinai, Mount Sinai Morningside-Mount Sinai West, New York, NY 10025, USA; errol.moras@mountsinai.org (E.M.); kruti.gandhi@mountsinai.org (K.D.G.)
- ² Department of Medicine, Jacobi Medical Center/ Albert Einstein College of Medicine, New York, NY 10461, USA; shreyasyakkali1998@gmail.com
- ³ Harrington Heart & Vascular Institute, Case Western Reserve University, University Hospitals Cleveland Medical Center, Cleveland, OH 44106, USA
- ⁴ Section of Cardiology, Baylor College of Medicine, Houston, TX 77030, USA; syed.zaid@bcm.edu (S.Z.)
- ⁵ Cardiac Catheterization Laboratory, Mount Sinai Morningside Hospital, New York, NY 10025, USA; nitin.barman@mountsinai.org
- ⁶ Division of Cardiology, University of Texas Medical Branch, Houston, TX 77555, USA
- ⁷ Lifespan Cardiovascular Institute, Rhode Island Hospital, Warren Alpert Medical School of Brown University, Providence, RI 02903, USA; svallabhajosyula@lifespan.org
- ⁸ Cardiac Catheterization Laboratory, Mount Sinai Heart, The Mount Sinai Hospital, New York, NY 10029, USA
- ⁹ Cardiology Division, NYU Langone Health/NYU School of Medicine, 550 First Avenue, New York, NY 10016, USA
- * Correspondence: chayakrit.krittanawong@va.gov

Abstract: In recent decades, significant advancements in pharmacological, catheter-based, and surgical reperfusion technologies have markedly improved outcomes for individuals undergoing acute myocardial infarction. Despite these remarkable progressions, a segment of patients, particularly those with extensive infarctions or delays in revascularization, remains vulnerable to the onset of mechanical complications associated with myocardial infarction. These complications, spanning mechanical, electrical, ischemic, inflammatory, and thromboembolic events, pose substantial risks of morbidity, mortality, and increased utilization of hospital resources. The management of patients experiencing these complications is intricate, necessitating collaborative efforts among various specialties. Timely identification, accurate diagnosis, hemodynamic stabilization, and decision-making support are crucial for guiding patients and their families in choosing between definitive treatments or palliative care. This review underscores the critical importance of promptly identifying and initiating therapy to reduce prolonged periods of cardiogenic shock and the potential for fatality. By presenting key clinical and diagnostic insights, this review aims to further improve early diagnosis and offer an updated perspective on current management strategies for the diverse range of complications associated with acute myocardial infarction.

Keywords: AMI; myocardial infarction



Citation: Moras, E.; Yakkali, S.; Gandhi, K.D.; Virk, H.U.H.; Alam, M.; Zaid, S.; Barman, N.; Jneid, H.; Vallabhajosyula, S.; Sharma, S.K.; et al. Complications in Acute Myocardial Infarction: Navigating Challenges in Diagnosis and Management. *Hearts* **2024**, *5*, 122–141. <https://doi.org/10.3390/hearts5010009>

Academic Editor: Diego Franco Jaime

Received: 19 February 2024

Revised: 7 March 2024

Accepted: 12 March 2024

Published: 13 March 2024



Copyright: © 2024 by the authors. Licensee MDPI, Basel, Switzerland. This article is an open access article distributed under the terms and conditions of the Creative Commons Attribution (CC BY) license (<https://creativecommons.org/licenses/by/4.0/>).

1. Introduction

Acute coronary syndromes (ACS) involve a range of patients, usually categorized according to their electrocardiogram (ECG) at presentation and the presence or absence of cardiac troponin elevation. This classification distinguishes between acute myocardial infarction (AMI) and unstable angina (UA). AMI is characterized by cardiomyocyte necrosis during acute myocardial ischemia, including myocardial infarction (MI) caused by atherothrombotic events (Type 1 MI) as well as other potential causes of myocardial ischemia and myocyte necrosis (Type 2–5 MI) [1]. Annually, over 3 million individuals

worldwide experience AMI. A recent study of 19,781 coronary artery disease (CAD) patients revealed a 23.3% prevalence of MI, while, in the United States, AMI has shown a declining trend in hospitalizations over the past decade, with an overall prevalence of 3% and an in-hospital mortality rate of 7.7% [2–4]. Although mechanical complications following myocardial infarction are rare, they continue to play a significant role in determining outcomes.

Over the last decade, there has been a temporal decline in the proportion of patients presenting with AMI, and typical patients with mechanical complications tend to be older, show a female sex preponderance, have a history of heart failure and chronic kidney disease, and are often delayed in presenting with their first AMI [5,6]. Reperfusion therapies, especially primary percutaneous coronary intervention (PCI), have significantly reduced the occurrence of mechanical complications in AMI [7]. Despite the low incidence, in the past two decades, patients with mechanical issues faced over a 4-fold increase in inpatient mortality compared to individuals without such issues, and overall mortality rates have not significantly decreased [8]. Moreover, the treatment choices involving surgery and percutaneous interventions often involve intricate procedures and demand the skills of multidisciplinary teams. The urgency and time-critical nature of these complications underscore the importance of promptly identifying and initiating therapy to minimize prolonged periods of cardiogenic shock and the risk of potential fatality. This review aims to highlight significant clinical and diagnostic observations that can aid in the prompt identification of mechanical complications while providing an overview of current strategies for management (Figure 1).

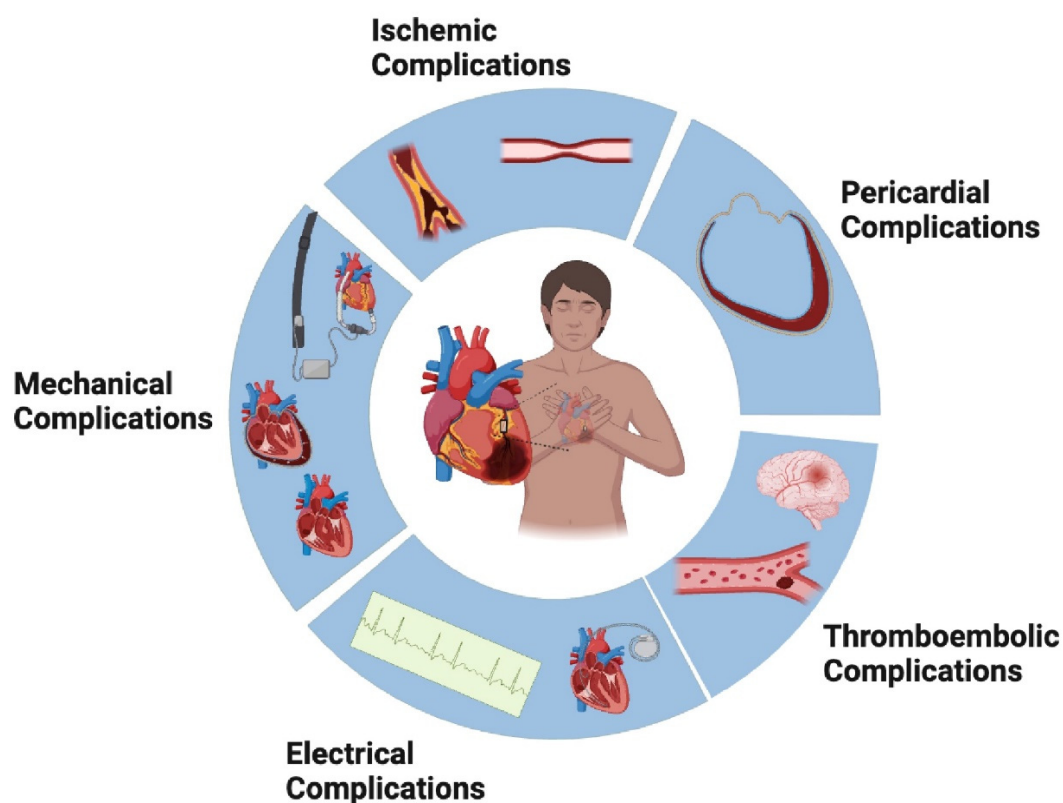


Figure 1. Complications of Acute Myocardial Infarction.

2. Mechanical Complications

2.1. Papillary Muscle Rupture and Ischemic Mitral Regurgitation

Clinical Presentation: Papillary Muscle Rupture (PMR) remains the predominant cause of acute severe mitral regurgitation (MR) following MI, accounting for over half of such cases [9,10]. Typically, PMR occurs within the initial 7 days post-MI, with a median

presentation time of 13 h according to the SHOCK (Should We Emergently Revascularize Occluded Coronaries for Cardiogenic Shock) trial registry [11]. Patients presenting with PMR are often older, with a higher prevalence of hypertension and a lower likelihood of diabetes or a history of prior MI. In terms of coronary anatomy, single-vessel occlusion is a common occurrence in PMR, and the right coronary artery (RCA) is more frequently affected than the left circumflex artery (LCX), with the left anterior descending artery (LAD) being less commonly involved. The anterolateral papillary muscle, receiving blood supply from both the LAD and LCX, is somewhat shielded against single-vessel occlusion. In contrast, the posteromedial papillary muscle relies on the dominant RCA or LCX, rendering it more prone to potential engagement. Acute pulmonary edema is the prevailing clinical presentation in PMR cases. In the setting of acute severe mitral regurgitation and elevated left atrial (LA) pressures, examination findings might not consistently demonstrate the anticipated holosystolic murmur, contrary to the conventional expectation [12].

Ischemic mitral regurgitation (IMR) represents a consequential manifestation of changes in the geometry of the left ventricle or atrium following MI. This type of secondary MR typically involves the tethering of the posterior leaflet, attributed to either isolated annular dilatation or excessive leaflet motion dysfunction [13]. IMR can emerge early during MI, presenting with a spectrum of severity ranging from mild dyspnea and coughing to overt symptoms of congestive cardiac failure and hemodynamic compromise. Notably, even transient ischemia can precipitate reversible IMR if the ischemic condition is promptly resolved. In the era of primary PCI, there has been a notable shift in managing IMR, underscoring the importance of early revascularization to mitigate permanent IMR and improve long-term outcomes following acute MI. It is worth noting that a pansystolic murmur in the mitral area, often radiating to the left axillary line, is frequently observed in patients with IMR, highlighting its clinical significance and diagnostic relevance [14].

Management: Acute pulmonary edema, a frequently observed manifestation in instances of PMR, can be confirmed through chest radiography. While Transthoracic Echocardiography (TTE) may reveal PMR findings, transesophageal echocardiography (TEE) might be necessary. Detectable indicators in imaging consist of a rapidly moving ruptured papillary muscle extending into the LA, prolapsed or flail leaflets, a V-shaped mitral regurgitation signal in spectral Doppler tracing diverging from the usual rounded pattern, or a distinct regurgitant jet. Given the urgency of this condition, additional imaging modalities are often unnecessary [15]. The initial strategy for addressing this involves managing acute pulmonary edema through interventions such as noninvasive or invasive ventilation, as needed. Facilitating vasodilation and decreasing afterload can help alleviate MR and enhance the forward flow in the left ventricle (LV). However, relying solely on medical management results in mortality rates approaching 50%, underscoring the general recommendation for early surgical intervention [16]. The most frequent approach is mitral valve replacement (MVR), although, in certain instances, mitral valve repair (MVr) may be feasible. Previous studies indicate that there is no substantial difference in inpatient mortality rates between MVR or MVr. Surviving beyond 30 days, patients with PMR exhibit 5-year mortality rates comparable to those of individuals who experience MI without PMR [17]. In patients with IMR where MR occurs due to papillary muscle dysfunction and not rupture, the treatment options may include conservative measures or surgical interventions, such as replacement or repair with or without CABG. In some cases, only revascularization with CABG or PCI may be considered. The acute course of IMR is typically associated with significant hemodynamic compromise, leading to a higher incidence of patients requiring mechanical circulatory support (MCS) and ventilatory assistance, prompting urgent or salvage interventions. Surgical intervention remains the established gold standard in managing IMR. Alternatively, mitral transcatheter edge-to-edge repair (TEER) has been explored as a treatment option in patients deemed high-risk for surgery. Preliminary findings from limited case series indicate the viability of the technique, showing a decrease in MR, enhanced hemodynamics, and continued functional improvement for a duration of up to 1 year [18,19].

2.2. Ventricular Septal Rupture

Clinical Presentation: In the absence or delay of reperfusion, the onset of Ventricular Septal Rupture (VSR) exhibits a bimodal pattern, including an elevated risk in the first 24 h and a subsequent peak at 3 to 5 days [20]. However, data from the SHOCK trial registry and the GUSTO-I (Global Utilization of t-PA and Streptokinase for Occluded Coronary Arteries) trial reveal a shorter median time for VSR onset, recorded at 16 h and 1 day, respectively. Instances of VSR beyond 2 weeks following an MI are infrequent [21,22]. Women, elderly individuals, those with chronic kidney disease (CKD), and individuals with diabetes, hypertension, a history of cigarette smoking, or a previous MI are at a heightened risk of VSR. Revascularization through PCI is linked to a reduced occurrence of VSR compared to thrombolytic therapy. Additionally, VSR is less common in patients undergoing primary PCI compared to delayed intervention and is more prevalent in those with anterior MI [23,24]. The onset of VSR initially leads to a left-to-right shunt, subsequently leading to overload of the left atrium and ventricle. The direction of the ongoing shunt depends on the functioning of both the ventricles, as well as the pulmonary and systemic vascular resistance. Individuals with VSR may manifest symptoms such as dyspnea, chest pain, and other signs of cardiogenic shock. Although acute pulmonary edema is less common, a distinctive harsh pansystolic murmur at the left sternal border and a potentially palpable thrill are usual findings upon examination. However, in cases of cardiogenic shock, the murmur may not be audible [20].

Management: TTE is often the initial diagnostic choice, typically sufficient for identifying the presence, location, and size of a VSR. TTE can also assess the shunt flow, chamber enlargement and any underlying dysfunction. If TTE images are suboptimal, a TEE can be performed for better visualization. During coronary angiography, suspicion of VSR can be confirmed through a left ventriculogram, which illustrates the flow of contrast from left to right. The ventricular septum can be supplied by the LAD artery, the dominant RCA, or the dominant LCX. Individuals who have experienced an anterior MI are at a higher risk of developing VSR, typically resulting in uncomplicated apical defects. In contrast, inferior or lateral MIs are more likely to lead to basal defects [20,24,25]. Temporary measures such as medical therapy using inotropes and diuretics are employed until more definitive treatment is initiated. Unstable patients may necessitate the use of an Intra-Aortic Balloon Pump (IABP) or Extracorporeal Membrane Oxygenation (ECMO). In a multicenter European registry study that investigated the utilization of the Impella device as a temporary mechanical circulatory support in 28 patients with post-MI VSR, it was found that, although Impella demonstrated feasibility in addressing the interventricular shunt in these patients, it was associated with a high mortality rate of 75%, with 50% of cases experiencing severe bleeding [26]. Notably, patients who did not undergo surgical repair did not survive. According to the GUSTO-I trial, relying solely on medical therapy resulted in a 30-day mortality rate of 94%, which was twice as high as that observed in patients undergoing surgery [22]. Surgical intervention is the conclusive treatment for VSR, although the optimal timing remains uncertain. Two established surgical techniques for treating VSR involve either trimming and suturing the infarcted myocardium or using the infarct exclusion method, where a larger patch is sewn over the defect and infarcted area onto healthy myocardium [27,28]. Surgical intervention has demonstrated a significant decrease in in-hospital mortality rates, dropping from 90% to 33–45% [29]. However, early surgical repair of VSD has presented challenges, with a high 30-day operative mortality rate of 40% persisting over the last two decades. This risk endures due to the delicate nature of infarcted myocardium in the early stages post-MI, making surgical intervention challenging and increasing the likelihood of recurrent septal defects. Conversely, a prolonged duration allows the heart to acclimate to the hemodynamic consequences of the sudden left-to-right shunt, providing time for scar maturation at the defect's edges. However, this approach comes with the potential risk of rupture extension and death while awaiting surgery. In a study led by Ronco et al., delayed surgery seemed to be associated with enhanced survival rates. Consequently, early surgery is recommended for all patients with severe heart failure that does not promptly respond

to aggressive therapy. Still, in cases where patients positively respond to aggressive heart failure therapy, consideration may be given to delayed elective surgical repair [30,31].

In modern medical practice, for individuals deemed high-risk for surgery, there are now minimally invasive percutaneous techniques which can be performed under general anesthesia, guided by both TEE and fluoroscopy. Measurements obtained through TEE or balloon sizing play a crucial role in determining the appropriate size for the device. By utilizing both arterial and venous access, the defect is typically traversed from left to right, allowing for the insertion of a long sheath through which the occluder device can be positioned precisely at the location of the VSR [32,33]. Due to the intricacies involving the defect's size and shape, hemodynamic stability, and various patient factors, decisions on the optimal timing and method of closure should be made through heart team discussions.

2.3. Free Wall Rupture

Clinical Presentation: Originally, three classifications were assigned to Free Wall Rupture (FWR): type 1 rupture is characterized by an abrupt tear, typically occurring within the first 24 h of a MI; type 2 rupture entails a more gradual tear accompanied by localized myocardial erosion; and type 3 rupture presents as the perforation of a thin-walled aneurysm, typically occurring more than 7 days after an MI [34]. In the context of mechanical complications following AMI, several risk factors have been identified. Patients with characteristics such as transmural MI, a single-vessel MI, the first occurrence of MI with poor collateral circulation, anterior and lateral MIs, hypertension, delayed thrombolysis (beyond 14 h), a preference for fibrinolysis over PCI, the use of nonsteroidal anti-inflammatory drugs, being female, and being over the age of 70 are at an increased risk of developing FWR [35]. Individuals experiencing FWR may exhibit symptoms such as dyspnea, chest pain, hemodynamic instability, or even cardiogenic shock. In more than 80% of instances, patients also present with cardiac tamponade. FWR episodes occurring beyond the initial week may also be associated with activities involving straining, such as coughing or vomiting. Clinical examinations might uncover significant findings such as an elevated jugular venous pulse, diminished heart sounds, or pulsus paradoxus, suggesting the potential presence of cardiac tamponade. Although less common, acute pulmonary edema may also be observed [35,36].

Management: A TTE can reveal the presence of pericardial tamponade physiology or effusion and confirm the presence of clots or exudative material within the pericardial space, diagnostic of FWR. The initial management approach for FWR is identical to that for acute cardiac tamponade. Pericardiocentesis may be considered as a temporary measure if persistent hypotension is observed. However, this may be limited at times due to a thrombus. The identification of a hemopericardium strongly supports the diagnosis of FWR. To sustain hemodynamic stability during the interim period, mechanical support using either an IABP or ECMO may be deemed necessary [37,38]. Surgery represents the definitive treatment for FWR, with the goal of closing the tear and preventing the recurrence of rupture or the development of a pseudoaneurysm, all while preserving ventricular geometry. Various techniques, including sutured and sutureless approaches employing adhesives or surgical glues, can be utilized. Closing the rupture line using sutures in a linear fashion is possible when there is an ample supply of non-ischemic myocardium. However, it becomes difficult when confronted with a substantial necrotic area. An alternative approach is to directly suture a patch over the rupture and infarcted myocardium, with the possibility of using surgical glue to attach the patch to healthy myocardium, especially in the absence of active bleeding. The less common method involves infarct excision coupled with either direct suture or patch closure [38]. When surgery is not a viable option for patients, medical management might be the only available course of action. Nevertheless, the mortality rates for patients treated solely with medical approaches during their hospital stay are exceptionally elevated, reaching up to 90%, in stark contrast to the approximately 50% mortality rate observed in those who undergo surgery [23].

2.4. True and Pseudoaneurysms

A pseudoaneurysm occurs when the ventricular wall ruptures, but it is confined by the pericardium and fibrous tissue, lacking myocardial tissue. Conversely, a true aneurysm is a noncontractile bulge originating from the ventricle that involves all the layers of the myocardial wall.

Clinical Features: Individuals with pseudoaneurysms may manifest symptoms such as dyspnea, chest pain, palpitations, or cardiac tamponade or may even be identified incidentally [39]. In contrast, true aneurysms typically arise within the initial two weeks following an MI due to myocardial necrosis. Modern revascularization methods have mitigated the extent of myocardial necrosis, consequently reducing the occurrence of true aneurysms [40]. Authentic aneurysms may exhibit symptoms such as angina, heart failure, ventricular tachycardia, or the presence of a LV thrombus. During a physical examination, one may observe a distinct diffuse apical impulse or the existence of a third or fourth heart sound. ECG results displaying Q waves align with the location of the aneurysm, and there might be prolonged ST-segment elevation [41]. In contrast, pseudoaneurysms usually reveal heart failure as the predominant symptom, although they can also exhibit angina or be asymptomatic.

Management: TTE is commonly the initial imaging method employed. A pseudoaneurysm is usually identified by a narrow neck, in contrast to a true aneurysm, which typically exhibits a wider neck. Differentiating between a pseudoaneurysm and a true aneurysm can be challenging at times. In such cases, further assessment using cardiac computed tomography or magnetic resonance imaging becomes valuable for both discerning between the two pathologies and elucidating the anatomical details. Cardiac MRI, due to its superior spatial resolution, exhibits greater sensitivity and specificity in detecting pseudoaneurysms compared to TTE. Specifically, the lack of delayed enhancement within the aneurysm's sac on cardiac MRI, coupled with the presence of delayed enhancement in the pericardium, strongly indicates the presence of a pseudoaneurysm [42]. Additionally, pseudoaneurysms tend to appear more frequently on the posterior or lateral wall, while true aneurysms are more prone to occur on the anterior wall or apex [43]. Pseudoaneurysms pose a significant risk of expanding and rupturing, necessitating surgical intervention. Recommended surgical methods encompass directly closing the defect with sutures or utilizing a patch closure over an area of viable myocardium [44]. A more specific consideration for true aneurysms involves the use of preventive anticoagulation to minimize the risk of systemic embolization associated with LV thrombus. However, the optimal management strategy remains uncertain. Apart from this aspect, the medical management aligns with conventional heart failure treatment. The Coronary Artery Surgery Study (CASS) registry demonstrated comparable outcomes between patients receiving medical treatment and those opting for surgery, a 90% survival rate at one year and a 71% survival rate at four years, showing no significant difference compared to surgically treated patients with equivalent left ventricular dysfunction [45]. Currently, the recommendation is to simultaneously remove an aneurysm while performing coronary artery bypass grafting (CABG), particularly in instances of a sizable aneurysm. This is especially advocated when there is a risk of rupture, the presence of a significant thrombus, or if the aneurysm contributes to recurrent arrhythmias [46].

2.5. Left Ventricular Failure and Cardiogenic Shock

Clinical Presentation: The incidence of cardiogenic shock following a MI is approximately 6% in cases of ST-segment elevation myocardial infarction (STEMI) and around 3% in non-ST-segment elevation myocardial infarction (NSTEMI). Several risk factors contribute to the development of cardiogenic shock post-MI, including anterior MI, left bundle branch block (LBBB), a history of prior MI, the presence of three-vessel disease, advanced age, hypertension, diabetes mellitus, and the occurrence of other mechanical complications. Cardiogenic shock can rapidly ensue after an MI, with around 50% of STEMI patients experiencing it within 6 h and 75% within 24 h. For NSTEMI, cardiogenic shock typically

arises between 72 to 96 h post-MI. Clinically, cardiogenic shock is characterized by new chest pain, a cold and wet physiological state, hypotension, tachycardia, dyspnea, jugular venous distension, rales, and the emergence of a new murmur [47].

Management: TTE plays a pivotal role in providing a comprehensive view of cardiac function and structural abnormalities, aiding in the identification of factors contributing to cardiogenic shock. Additionally, pulmonary artery catheterization (PAC) proves valuable, particularly when the cardiac index (CI) falls below 2.2 and the pulmonary capillary wedge pressure (PCWP) exceeds 18, indicative of compromised cardiac output and increased left ventricular filling pressures. Beyond these cardiac-specific measures, the assessment of end-organ perfusion status, including the presence of lactic acidosis and acute kidney injury (AKI), is crucial in confirming the systemic impact of cardiogenic shock and guiding appropriate interventions. Patients facing mechanical complications post-myocardial infarction are particularly susceptible to progressing towards refractory cardiogenic shock. In the SHOCK trial registry, these cases represented 12% of individuals presenting with cardiogenic shock. For individuals in such conditions, mechanical circulatory support options include Impella, IABP, and ECMO. In the IABP-SHOCK2 trial, which included patients experiencing cardiogenic shock following acute myocardial infarction and undergoing early revascularization, the use of intra-aortic balloon pump support did not result in a decrease in 30-day mortality [48]. Despite the implementation of MCS, refractory cardiogenic shock still carries a notably high mortality rate, ranging between 40% to 50%. A meta-analysis focusing on the use of ECMO in cardiogenic shock revealed a survival rate to discharge of only 43%. Despite these findings, recent guidelines from the International Society for Heart and Lung Transplantation/Heart Failure Society of America and the European Society of Cardiology endorsed Extracorporeal life support (ECLS) with class II-C and IIa-C recommendations, respectively [49,50]. However, the recently published ECLS-SHOCK trial, the largest prospective randomized study on ECLS to date, comparing early unselective ECLS implantation with medical management in AMI-CS, demonstrated no significant differences in 30-day mortality or secondary efficacy outcomes among the 417 patients analyzed. The results remained consistent across all specified subgroups. Notably, ECLS did not contribute to faster or improved hemodynamic stabilization, and it was associated with a higher incidence of complications, including peripheral ischemic vascular complications (11% vs. 3.8%) and moderate/severe bleeding [51].

The perceived inefficacy of MCS in addressing cardiogenic shock associated with acute myocardial infarction is linked to issues such as delays in commencing therapy, delays in identifying patients, and a lack of standardized protocols for decision-making [52–54]. The selection of primary endpoints for future research on MCS in cardiogenic shock is currently a subject of discussion. Although short-term all-cause mortality is conventionally viewed as the gold standard, experts propose the exploration of continuous hierarchical composite endpoints, including rates of patients alive and free from organ support, global rank scores, or days spent alive and outside the hospital. It is essential to incorporate the absence of myocardial recovery and device failure as integral components of the primary endpoint when assessing MCS. Subsequent randomized controlled trials may center on customized interventions designed for specific stages of cardiogenic shock (D/E) [55].

2.6. Right Ventricular Myocardial Infarction

Clinical Presentation: Right ventricular myocardial infarction (RVMI) frequently co-exists with the acute infarction of the inferior wall of the left ventricle, observed in over one-third of these instances. The primary cause of the majority of right ventricular infarcts is a blockage of the proximal right coronary artery. The suspicion of right ventricular myocardial infarction (RVMI) becomes pronounced when a patient exhibits hypotension, elevated jugular venous pressure (distended neck veins), and clear lung fields, alongside indications of an inferior wall infarction and ST-elevation in lead V4R on the 12-lead ECG [56].

Management: In general, the management approach for patients with RVMI aligns with that for acute STEMI. This involves the early administration of dual oral antiplatelet

therapy (combining aspirin with a platelet P2Y₁₂ receptor blocker) and statin therapy, along with anticoagulants. However, caution is advised when considering drugs that reduce preload such as nitrates or diuretics, beta blockers, or that decrease contractility such as calcium channel blockers. Swift initiation of reperfusion, particularly through primary PCI, is crucial and should be prioritized [57]. For patients exhibiting signs of low cardiac output, clear lung fields, and normal or low jugular venous pressure, administering small boluses of normal saline is recommended. It is advised to avoid medications that reduce preload, such as nitrates or opioids. In cases where persistent hypotension persists despite efforts to optimize right ventricular preload with normal saline boluses, the addition of dopamine is suggested. Patients primarily experiencing RVMI do not show improvement with afterload-reducing therapy using either an IABP or vasodilating agents. However, in some instances where there is increased right ventricular afterload due to LV dysfunction, the hemodynamic profile is influenced by biventricular dysfunction. In such scenarios, the use of an IABP or, in rare cases, vasodilating agents, may enhance the hemodynamic profile. Recognizing that bradycardia and atrioventricular desynchrony can swiftly exacerbate the hemodynamic status of patients with RVMI, early interventions to correct these electrical abnormalities are crucial. The criteria for employing atropine and temporary transvenous pacing mirror those for the broader population of patients with myocardial infarction [58].

2.7. Dynamic Left Ventricular Outflow Tract Obstruction

Clinical Presentation: Historically, dynamic left ventricular outflow tract (LVOT) obstruction was considered characteristic of hypertrophic obstructive cardiomyopathy, particularly in cases with isolated asymmetric septal hypertrophy and systolic anterior motion (SAM) of the mitral valve. However, recent studies have highlighted the occurrence of dynamic LVOT obstruction during acute coronary insufficiency in ventricles without substantial myocardial hypertrophy. In these instances, the LVOT gradient was observed to resolve upon the resolution of the ischemic syndrome [59]. In individuals presenting with hemodynamic instability and potential STEMI, it is crucial to conduct a clinical examination to identify signs consistent with subaortic stenosis. If the patient is hypotensive, a bisferiens pulse may not be apparent, and the apex could be silent. While MR features may be more prominent, the presence of a sustained apical heave and a distinct ejection murmur, particularly audible in the left third intercostal space, should raise suspicion of LVOT obstruction [60].

Management: If a murmur indicative of LVOT obstruction is identified, an echocardiogram should be promptly conducted. However, to avoid delays in the early diagnosis and relief of coronary occlusions, catheterization may be the initial diagnostic approach. If coronary catheterization reveals no significant lesions, an assessment of left ventriculography and catheter pullback gradients can be useful. Despite the absence of significant coronary lesions, hypotension may persist due to increasing gradients across the LVOT. Regardless of the coronary anatomy and interventions performed, a repeat echocardiogram should be considered if an ejection murmur is detected along with hemodynamic compromise [60]. Intravenous fluids can be beneficial by increasing intravascular volume and LV volumes, thereby reducing mitral SAM. Coronary revascularization is essential for improving the contractility of apical segments and mitigating basal hypercontractility. In scenarios where LVOT obstruction is not suspected, the escalation of inotropic agents may be considered, with further decompensation potentially attributed to STEMI-related LV dysfunction. Even in the absence of significant coronary lesions, this escalation could elevate wall stress in the subendocardium enough to cause the leakage of cardiac biomarkers indicative of MI. The use of an IABP has the potential to induce or worsen LVOT obstruction by reducing afterload. Phenylephrine, by selectively improving vascular tone, may help reduce LVOT obstruction. β -blockers can be advantageous in reducing LVOT gradients by diminishing basal hypercontractility, enhancing LV filling and size, and lowering heart rate. Non dihydropyridine calcium channel blockers may be considered if beta blockers are con-

traindicated. Targeting a heart rate below 60 to 70 beats per minute should ensure adequate cardiac inhibition and a reduction in LVOT obstruction [61,62].

3. Electrical Complications

The primary mechanism behind arrhythmias is re-entry, which arises from the electrical irregularities within the ischemic myocardium. Arrhythmias related to reperfusion occur due to the removal of various ions such as potassium, lactate, and metabolic substances which have accumulated in the ischemic area. These arrhythmias result in unfavorable hemodynamic effects, particularly in patients with LV dysfunction, as they exhibit a relatively consistent stroke volume and depend on variations in heart rate to adjust cardiac output. Prior to the establishment of coronary care units, primary ventricular arrhythmias were the primary cause of mortality in individuals experiencing AMI [63].

3.1. Atrial Tachyarrhythmias

Clinical Presentation: Among individuals experiencing AMI, sinus tachycardia and various atrial tachyarrhythmias, including atrial extrasystoles, atrial flutter (AFL), atrial fibrillation (AF), and paroxysmal supraventricular tachycardias (SVT), are relatively common, affecting over one-third of AMI patients. Both sinus tachycardia and SVTs are considered adverse prognostic features due to their detrimental impact on myocardial oxygen consumption and supply. They often coexist with other negative prognostic factors such as LV dysfunction, congestive heart failure, atrial distention, and hypoxemia [64]. Various factors can induce sinus tachycardia, including ongoing pain, anxiety, LV failure, fever, pericarditis, hypovolemia, pulmonary embolism (PE), and the use of heart-stimulating drugs such as atropine, epinephrine, or dopamine. This condition leads to an increase in myocardial oxygen usage and a decrease in the time available for coronary perfusion, thereby exacerbating myocardial ischemia. When sinus tachycardia persists, it might indicate ongoing heart failure, signaling a concerning prognosis with an increased risk of mortality [65]. AFL and AF typically occur temporarily due to increased sympathetic stimulation of the atria, ventricular failure, pericardial inflammation, and ischemic injury to the atria. The increased ventricular rate and decreased contribution of the LA to LV filling result in a notable decrease in cardiac output. As a result, AF is linked to heightened mortality and an increased risk of stroke, particularly in patients with anterior wall MI [66,67].

Management: In the management of SVTs, the first measures include identifying and addressing potential triggers, such as stress, discomfort, LV failure, hypotension, and atrial distension. When dealing with sinus tachycardia, intravenous administration of β -adrenergic blockers is advised for individuals lacking signs of cardiac failure or contraindications [68]. In situations where cardiac failure is suspected, the therapy should be guided by invasive hemodynamic monitoring. The primary strategy for addressing AF consists of controlling the heart rate using intravenous diltiazem or esmolol. In situations of hemodynamic instability, prompt transthoracic cardioversion may be necessary. If AF has endured for more than 48 h, or if the duration is uncertain, cardioversion ideally should be preceded by TEE to eliminate the possibility of a LA thrombus. For patients stable in terms of hemodynamics, cardioversion can be accomplished through pharmacological means (utilizing amiodarone, procainamide, or ibutilide) or via electrical cardioversion. To prevent thromboembolic complications, therapeutic anticoagulation is essential for at least 3 weeks before and an additional 4 weeks after cardioversion, particularly if AF has persisted for more than 48 h. Cardioversion can be carried out without anticoagulation if the AF's duration is less than 48 h. Digoxin remains the preferred medication for atrial fibrillation or flutter in individuals with severe left ventricular dysfunction, while employing overdrive atrial pacing techniques may prove beneficial for stubborn cases of atrial flutter. Additionally, intravenously administered procainamide may be employed for chemical cardioversion or to prevent the recurrence of atrial arrhythmias. Other class IA agents may be considered for long-term therapy if needed. However, caution is recommended

with class IC agents due to potential adverse effects on survival in patients treated for ventricular arrhythmias after acute myocardial infarction (AMI) [69,70].

3.2. Ventricular Tachyarrhythmias

Clinical Presentation: Non-sustained ventricular tachycardia (NSVT) occurring early after presentation does not appear to be associated with an elevated risk of mortality. Ventricular tachycardia that arises later in the course of AMI is more common in individuals with transmural infarction and LV dysfunction. Additionally, it is more likely to be sustained, leading to significant hemodynamic deterioration and an increased risk of both short-term and long-term mortality. Ventricular fibrillation (VF) can manifest in three scenarios among hospitalized AMI patients. Primary VF occurs suddenly without prior signs or symptoms of LV failure. Secondary VF typically marks the culmination of a progressive decline associated with LV failure and cardiogenic shock. Late VF, appearing more than 48 h after AMI, is primarily observed in patients with extensive infarcts and LV dysfunction [71,72].

Management: Promptly halting persistent ventricular tachycardia in patients with AMI through cardioversion or defibrillation is essential. This not only enhances LV function but also aids in averting progression into ventricular fibrillation. Focus should be given to actively correcting electrolyte imbalances, such as hypokalemia, hypocalcemia, and hypomagnesemia. The use of magnesium supplementation has been linked to a significant decrease in ventricular ectopic activity, and it is generally well-tolerated with minimal side effects [73]. Patients experiencing recurrent or refractory VT may be candidates for specialized interventions, such as the implantation of an automatic implantable cardioverter-defibrillator (AICD) or surgical procedures. Numerous trials incorporating individuals who have experienced AMI in their study cohorts have demonstrated noteworthy reductions in mortality for patients randomly assigned to implantable cardioverter-defibrillator (ICD) placement compared to those receiving conventional medical treatment. Currently, the proactive recommendation for ICD implantation post-AMI applies to patients with a left ventricular ejection fraction (LVEF) below 35%, at least 40 days after AMI, and exhibiting New York Heart Association (NYHA) class II or III symptoms. Swift efforts to achieve revascularization through angioplasty or CABG can effectively manage refractory VT. The treatment of VF involves rapid, unsynchronized electrical countershock, delivering at least 200 to 300 joules. Intravenous amiodarone can be employed to interrupt recurrent episodes successfully. In instances where synchronized cardiac electrical activity is restored but contraction remains ineffective, extensive myocardial ischemia or necrosis, or rupture of the ventricular free wall or septum, is the usual culprit [74,75].

3.3. Bradyarrhythmia's

Clinical Presentation: Sinus bradycardia commonly presents in individuals with infero-posterior wall MI and is usually associated with increased vagal tone. Ischemic injury at different levels of the conduction system can lead to atrioventricular (AV) and intraventricular blocks. The prevalence of AV block, excluding bundle branch block (BBB), in patients experiencing AMI is estimated to range from 12 to 25% [76]. Second-degree AV block, especially Type I, typically does not affect survival and is frequently linked to RCA occlusion, arising from ischemia in the AV node. Type II second-degree block often originates below the His bundle [77]. Complete (third-degree) AV block (CHB) may occur in patients with anterior wall myocardial infarction (AWMI) and inferior wall myocardial infarction (IWMI) [78]. CHB in IWMI is typically transient and results from intranodal or supra-nodal lesions. In AWMI, CHB may arise suddenly post-AMI, often preceded by intraventricular block and Type II AV block. Patients with AWMI and CHB may exhibit unstable escape rhythms with wide QRS complexes and rates below 40 bpm, leading to ventricular asystole. CHB in AWMI is associated with extensive septal necrosis involving the bundle branches [79]. Intraventricular block, pre-existing BBB or divisional blocks less frequently result in CHB in individuals with STEMI. Isolated fascicular blocks are less prone

to advancing to CHB. Nevertheless, a standalone right bundle branch block (RBBB) can advance to AV block, particularly when coupled with anteroseptal infarction, heightening the risk of mortality in patients with AWMi [80]. Bi-fascicular block, such as RBBB with left anterior or posterior fascicular block, or with left bundle branch block (LBBB), combined with first-degree AV block, poses an elevated risk of progressing to CHB, severe pump failure, and heightened mortality. This situation often necessitates temporary pacing.

Management: The management of first-degree AV block typically does not require specific intervention. However, caution is advised when using beta blockers and calcium antagonists (excluding nifedipine) due to the potential exacerbation of ischemic injury upon discontinuation during an AMI. If first-degree AV block coincides with sinus bradycardia and hypotension, the administration of atropine may be contemplated. Intravenous administration of atropine is advised, starting with low doses between 0.3 mg and 2.0 mg. The use of high atropine doses should be approached cautiously, as it may eliminate vagal overactivity, potentially revealing latent sympathetic hyperactivity and leading to sinus tachycardia and ventricular arrhythmias [81]. Continuous electrocardiographic monitoring is imperative to detect any potential progression to higher degrees of block.

In the case of second-degree AV block, targeted therapy with atropine is deemed appropriate if the patient displays symptoms, experiences a ventricular rate below 50 bpm, develops premature ventricular contractions (PVCs), or manifests BBBs [82]. In individuals experiencing infero-posterior MI, the approach to managing proximal conduction disturbances is typically more conservative compared to those with AWMi and conduction system disease. In cases of acute AWMi with CHB, temporary pacing is advantageous in averting transient hypotension and asystole. However, practical observations indicate that almost all patients with CHB tend to have better outcomes with temporary pacing, even in the absence of a confirmed survival advantage [83]. The 2018 ACC/AHA/HRS guidelines endorse careful consideration and recommend avoiding early permanent pacing (<72 h) in patients with acute myocardial infarction and AV blocks [84]. However, if CHB persists during the hospitalization of a patient with AMI, particularly in situations of markedly impaired sinus node function, or if there are instances of intermittent type II second- or third-degree block, permanent pacemaker (PPM) insertion may be required. Prophylactic pacing is recommended for patients with BBB who are considered at high risk for developing high-degree AV block [85].

4. Ischemic Complications

Clinical features: Differentiating between post-infarction angina or recurrent angina and non-ischemic causes presents a significant challenge for clinicians. Recurrent post-infarction angina may arise due to reasons such as extension of the infarct, reinfarction in a different area, or re-occlusion of the artery related to the initial infarction [86]. The extension of the infarct, marked by transient nonperfusion, results in additional myocardial necrosis, while infarct expansion involves an increase in the proportion of the left ventricle's surface area occupied by necrotic myocardium. This expansion leads to thinning of the infarcted wall, cavity dilatation, and distortion of ventricular topography. Clinical features indicative of infarct extension encompasses chest pain, increased congestive heart failure, hypotension, and ECG ST-T wave changes. While infarct extension occurs less frequently, its ramifications, notably ventricular dilatation, can have a substantial impact on the patient's trajectory post-infarction by placing increased work demands on the surviving myocardium. On the other hand, infarct expansion, a more common complication, can result in cardiac dysfunction through acute LV dilatation [87]. Studies utilizing precordial ST-segment mapping, indicate that acute transmural myocardial infarct extension happens in approximately 80 percent of patients within six days following an AMI [88].

Management: The recurrence of infarction within the initial 18 to 24 h following AMI should raise strong suspicions when there is a repeated ST-segment elevation on the ECG. Beyond this timeframe, the diagnosis of recurrent infarction can be established through the re-elevation of cardiac markers or the emergence of new Q waves on the

ECG. Post-infarction angina is a significant concern due to its correlation with increased morbidity and mortality. Urgent catheterization and PCI are recommended when the 12-lead ECG reveals ST-segment re-elevation. In situations where PCI is not available, repeat fibrinolysis may be considered. Hemodynamically stable symptomatic patients are managed with nitroglycerine and beta-blockade. However, if hypotension, heart failure, or ventricular arrhythmias develop during recurrent ischemia, urgent catheterization and revascularization are warranted [89].

5. Pericardial Complications

Clinical features: In the contemporary era marked by primary PCI, instances of early infarct-associated pericarditis have become relatively uncommon, typically surfacing within the initial 4 days after AMI and often displaying a transient nature. Late pericarditis, linked to Dressler syndrome, tends to manifest around 1–2 weeks post-AMI. Pericardial effusion, infrequently encountered, is more prevalent in cases of late or failed reperfusion or when confronted with larger infarct sizes. Early pericarditis arises due to transmural necrosis, leading to inflammation of the adjacent pericardium, while Dressler syndrome's pathophysiology likely involves a hypersensitivity immune reaction following the release of cardiac antigens during AMI [90]. Diagnostic criteria for pericarditis encompass pleuritic chest pain, pericardial friction rub, suggestive ECG changes, and new or worsening pericardial effusion. Although electrocardiogram changes may be overshadowed by those attributable to AMI, persistent upright T waves and new-onset positive T waves may be observed. Inflammatory markers often rise, and troponin levels may increase due to epicardial involvement [91]. Notably, pericarditis associated with a larger infarct size does not carry independent prognostic significance.

Management: The management of early post-infarction pericarditis typically involves aspirin administered every 8–12 h, tailored to the clinical case, with prolonged treatment beyond 5–7 days rarely necessary. Late pericarditis is first-line treated with aspirin (500–1000 mg every 6–8 h) until symptomatic improvement, followed by a tapering regimen. Colchicine, as an adjunct, is often administered at a dosage of 0.5 mg every 12 h for a duration of 3 months. Despite its association with a larger infarct size, pericarditis does not independently affect prognosis. In the presence of left ventricular thrombus, AF, or other indications, the use of antithrombotic and/or anticoagulants in patients with post-infarction pericarditis, with or without pericardial effusion, appears to be safe. Overall, the management approach is tailored to the specific clinical presentation and timing of pericarditis in the post-AMI setting [92–94].

6. Thromboembolic Complications

Clinical features: Clinically apparent systemic embolism following an MI is estimated to occur in approximately 2% of cases, with the presence of mural thrombus noted in around 5% of cases, particularly elevated in patients experiencing AAMI [95]. The manifestations of systemic embolism often include strokes, although patients may also encounter limb ischemia, renal infarction, and mesenteric ischemia. The majority of systemic embolic events occur within the initial 10 days post-AMI. Historical data from both pre-thrombolytic and thrombolytic eras indicate that LV thrombus was present in 7–46% of acute myocardial infarction cases [96,97]. Glueck et al.'s study, based on 151 autopsied cases, revealed a common occurrence of embolic phenomena in myocardial infarction patients, and this occurrence was significantly reduced with the administration of anticoagulant drugs [98]. In a study conducted by Latucca et al., the impact of anticoagulation therapy on the evolution of left ventricular thrombus was quantified through sequential imaging. The presence of LV thrombus was linked to a notably elevated risk of major adverse cardiac events at 37.1% and mortality at 18.9%. Anticoagulant use was correlated with complete regression of LV thrombus in 62.3% of patients, with a median time of 103 days [99]. Although the highest risk for LV thrombus formation is within the first 3 months following AMI, the potential for cerebral emboli persists in patients with chronic LV dysfunction. Risk

factors for LV thrombus development include large infarct sizes, severe apical asynergy, LV aneurysm, and anterior myocardial infarction [100]. Another significant nonatherosclerotic contributor to AMI is coronary artery embolism (CE). In a study conducted by Shibata et al., the prevalence of CE in patients with de novo AMI was 2.9%, with AF being the common cause of CE. The all-cause death and cardiac death during follow-up of these patients were significantly higher in the CE group, which represents a high-risk subpopulation of patients with AMI requiring close follow-up [101].

Management: Given the often-unheralded nature of these thromboembolic events, the most effective medical approach involves the adequate management of high-risk groups. The timing of LV thrombus assessment is crucial, ensuring that assessment is not too soon after the onset of myocardial infarction to avoid missing LV thrombus formation. TTE is commonly used for assessment, but up to 46% of echocardiograms may be inconclusive. Delay enhancement cardiac magnetic resonance imaging (CMR) is now considered the gold standard for assessment. The treatment involves administering intravenous heparin for a duration of 3 to 4 days to achieve an activated partial thromboplastin time 1.5 to 2 times that of the control values. Subsequently, oral anticoagulation is recommended for a period ranging from 3 to 6 months for patients with mural thrombus and those with large akinetic areas [102].

7. Conclusions

The complications of AMI represent high-acuity, time-sensitive conditions associated with elevated morbidity and mortality rates. Early recognition and decisive intervention remain the cornerstones in the quest for optimal patient outcomes. Given the dramatic presentations associated with complications and the urgent need for intervention, early revascularization has become the standard of care, resulting in a reduced incidence of complications of less than 0.1%. Furthermore, emphasizing patient-centered planning and the judicious timing of appropriate interventions, including surgical procedures, percutaneous technologies, and mechanical circulatory support involvement, holds the potential to significantly enhance both disease- and patient-centered outcomes (Table 1). As a result, a multidisciplinary heart team emerges as a crucial entity in guiding the care of patients post-AMI with complications.

Table 1. Summary of Major Complications of Acute Myocardial Infarction.

Complication	Presentation	Diagnosis	Management
Mechanical Complications			
Papillary Muscle Rupture Ischemic Mitral Regurgitation	Typically, 7 days post-MI. Most common clinical presentation: acute pulmonary edema. Most commonly involved territory: RCA.	CXR: acute pulmonary edema. TTE, TEE: ruptured papillary muscle, flail leaflets, and regurgitant jet.	Management of acute pulmonary edema. Surgical intervention: mitral valve replacement.
Ventricular Septal Rupture	Heightened risk in the initial 24 h. Secondary peak at 3 to 5 days. Symptoms: chest pain, dyspnea, and signs of cardiogenic shock.	TTE, TEE: presence, location, and size of the rupture. Coronary angiogram: confirm VSR suspicion via left ventriculogram.	Medical therapy: inotropes/diuretics. Unstable patients: IABP/ECMO. Surgical intervention: trimming and suturing the infarcted myocardium using a larger patch. Percutaneous techniques: for high-risk surgery patients, guided by TEE and fluoroscopy.

Table 1. Cont.

Complication	Presentation	Diagnosis	Management
Free Wall Rupture	Type 1: Sudden tear within 24 h. Type 2: gradual tear with localized erosion. Type 3: perforation of a thin-walled aneurysm after 7 days. Symptoms: chest pain, restlessness, hemodynamic instability, and cardiac tamponade.	TTE: pericardial effusion, tamponade physiology, or hemopericardium.	Addressing acute tamponade: pericardiocentesis. If hypotensive: IABP/ECMO. Definitive: surgical management.
True and Pseudoaneurysms	Usually within 2 weeks post-MI. Pseudoaneurysm symptoms: chest pain, dyspnea, or cardiac tamponade. True aneurysms manifest as angina, heart failure, ventricular tachycardia, or a visible apical impulse.	TTE: pseudoaneurysms show narrow neck and posterior/lateral location and true aneurysms seen as wider neck and anterior/apical location. Cardiac CT or MRI.	Pseudoaneurysm: surgical direct closure. True aneurysms: anticoagulation Large aneurysm: surgical resection during CABG.
LV Failure and Cardiogenic Shock	Symptoms: new chest pain, a cold and wet physiological state, hypotension, tachycardia, dyspnea, jugular venous distension, rales, and the emergence of a new murmur.	TTE: cardiac function, structural abnormalities. PAC.	Medical: diuretics. Refractory shock: IABP/Impella/ECMO.
Right Ventricular Myocardial Infarction	Symptoms: hypotension, elevated jugular venous pressure, clear lung fields, indications of inferior wall infarction.	ECG: ST-elevation in lead V4R. Angiogram: blockage of the proximal right coronary artery.	STEMI management: DAPT, statin, anticoagulation, primary PCI.
Dynamic Left Ventricular Outflow Tract Obstruction	Historically associated with hypertrophic obstructive cardiomyopathy. Other symptoms: hemodynamic instability, potential STEMI, and signs such as sustained apical heave and an ejection murmur.	TTE.	Intravenous fluids. Coronary revascularization. Inotropic agents. BB, CCB. Phenylephrine, IABP.
Electrical Complications			
Atrial Tachyarrhythmia	Afib and Aflutter are common.		Rate control: BB. Unstable: cardioversion. Anticoagulation.
Ventricular Tachyarrhythmia	NSVT—tolerable. VT, VFib—significant short-term and long-term mortality risks.	ECG.	Unstable Vt/VFib: rapid unsynchronized electrical countershock. Electrolyte replenishment. Recurrent or refractory ventricular tachycardia: CD.
Bradyarrhythmia	Commonly seen in infer posterior wall MI.	ECG: sinus bradycardia and AV blocks.	1st degree AVB: no intervention. 2nd degree AVB: atropine for symptomatic patients. Complete AVB: temporary pacing, PPM.
Ischemic Complications			
Post-infarction Angina	Suspicion of recurrent infarction within the initial 18 to 24 h post-AMI. Symptoms: chest pain, congestive heart failure, hypotension.	ECG: ST-T wave changes, new Q waves. Lab: cardiac biomarker elevation.	Urgent PCI. If PCI unavailable—fibrinolysis can be considered. Medical: BB, nitroglycerine.

Table 1. Cont.

Complication	Presentation	Diagnosis	Management
Pericardial Complications			
Post-infarction Pericarditis	Early infarct-associated pericarditis: initial 4 days after AMI. Dressler syndrome/late pericarditis: 1–2 weeks post-AMI. Symptoms: pleuritic chest pain, pericardial friction rub.	ECG: upright T waves and new-onset positive T waves. Lab: troponin, inflammatory markers.	Early post-infarction pericarditis: aspirin every 8–12 h. Late pericarditis: aspirin until symptomatic improvement.
Thromboembolic Complications			
Systemic Embolism and LV thrombus	Most frequently within the initial 10 days post-AMI. Signs: strokes, limb ischemia, renal infarction, and mesenteric ischemia	TTE. Cardiac MRI.	Anticoagulation.

Abbreviations: CXR: Chest X-Ray; TTE: Transthoracic Echocardiogram; TEE: Transesophageal Echocardiogram; ECG: Electrocardiogram; LV: Left Ventricle; RCA: Right Coronary Artery; PCI: Percutaneous Coronary Intervention; IABP: Intra-Aortic Balloon Pump; ECMO: Extracorporeal Membrane Oxygenation; CABG: Coronary Artery Bypass Grafting; CT: Computed Tomography; MRI: Magnetic Resonance Imaging; PAC: Pulmonary Artery Catheter; STEMI: ST-Elevation Myocardial Infarction.

Author Contributions: Conceptualization, E.M. and C.K.; methodology, E.M. and S.Y.; validation, N.B., H.J., S.V. and C.K.; data curation, E.M. and K.D.G.; writing—original draft preparation, E.M.; writing—review and editing, S.V., S.K.S., S.Z. and C.K.; supervision, H.U.H.V. and M.A.; project administration, E.M. and C.K. All authors have read and agreed to the published version of the manuscript.

Funding: This research received no external funding.

Conflicts of Interest: The authors declare no conflicts of interest.

References

1. Thygesen, K.; Alpert, J.S.; Jaffe, A.S.; Chaitman, B.R.; Bax, J.J.; Morrow, D.A.; White, H.D.; ESC Scientific Document Group. Fourth universal definition of myocardial infarction (2018). *Eur. Heart J.* **2019**, *40*, 237–269. [\[CrossRef\]](#)
2. Dyrbuś, K.; Gąsior, M.; Desperak, P.; Osadnik, T.; Nowak, J.; Banach, M. The prevalence and management of familial hypercholesterolemia in patients with acute coronary syndrome in the Polish tertiary centre: Results from the TERCET registry with 19,781 individuals. *Atherosclerosis* **2019**, *288*, 33–41. [\[CrossRef\]](#) [\[PubMed\]](#)
3. Kwok, C.S.; Abbas, K.S.; Qureshi, A.I.; Lip, G.Y.H. Outcomes for patients hospitalized with acute myocardial infarction and cerebral infarction in the United States: Insights from the National Inpatient Sample. *Intern. Emerg. Med.* **2023**, *18*, 375–383. [\[CrossRef\]](#) [\[PubMed\]](#)
4. Gerber, Y.; Weston, S.A.; Jiang, R.; Roger, V.L. The changing epidemiology of myocardial infarction in Olmsted County, Minnesota, 1995–2012. *Am. J. Med.* **2015**, *128*, 144–151. [\[CrossRef\]](#) [\[PubMed\]](#)
5. Rogers, W.J.; Frederick, P.D.; Stoeck, E.; Canto, J.G.; Ornato, J.P.; Gibson, C.M.; Pollack, C.V.; Gore, J.M.; Chandra-Strobos, N.; Peterson, E.D.; et al. Trends in presenting characteristics and hospital mortality among patients with ST elevation and non-ST elevation myocardial infarction in the National Registry of Myocardial Infarction from 1990 to 2006. *Am. Heart J.* **2008**, *156*, 1026–1034. [\[CrossRef\]](#) [\[PubMed\]](#)
6. French, J.K.; Hellkamp, A.S.; Armstrong, P.W.; Cohen, E.; Kleiman, N.S.; O'Connor, C.M.; Holmes, D.R.; Hochman, J.S.; Granger, C.B.; Mahaffey, K.W. Mechanical Complications After Percutaneous Coronary Intervention in ST-Elevation Myocardial Infarction (from APEX-AMI). *Am. J. Cardiol.* **2010**, *105*, 59–63. [\[CrossRef\]](#) [\[PubMed\]](#)
7. Bueno, H.; Martínez-Sellés, M.; Pérez-David, E.; López-Palop, R. Effect of thrombolytic therapy on the risk of cardiac rupture and mortality in older patients with first acute myocardial infarction†. *Eur. Heart J.* **2005**, *26*, 1705–1711. [\[CrossRef\]](#)
8. Salari, N.; Morddarvanjoghi, F.; Abdolmaleki, A.; Rasoulpoor, S.; Khaleghi, A.A.; Hezarkhani, L.A.; Shohaimi, S.; Mohammadi, M. The global prevalence of myocardial infarction: A systematic review and meta-analysis. *BMC Cardiovasc. Disord.* **2023**, *23*, 206. [\[CrossRef\]](#)
9. Chevalier, P.; Burri, H.; Fahrat, F.; Cucherat, M.; Jegaden, O.; Obadia, J.-F.; Kirkorian, G.; Touboul, P. Perioperative outcome and long-term survival of surgery for acute post-infarction mitral regurgitation. *Eur. J. Cardiothorac. Surg.* **2004**, *26*, 330–335. [\[CrossRef\]](#)

10. Calvo, F.E.; Figueras, J.; Cortadellas, J.; Soler-Soler, J. Severe mitral regurgitation complicating acute myocardial infarction: Clinical and angiographic differences between patients with and without papillary muscle rupture. *Eur. Heart J.* **1997**, *18*, 1606–1610. [[CrossRef](#)]
11. Thompson, C.R.; Buller, C.E.; Sleeper, L.A.; Antonelli, T.A.; Webb, J.G.; Jaber, W.A.; Abel, J.G.; Hochman, J.S. Cardiogenic shock due to acute severe mitral regurgitation complicating acute myocardial infarction: A report from the SHOCK Trial Registry. SHould we use emergently revascularize Occluded Coronaries in cardiogenic shock? *J. Am. Coll. Cardiol.* **2000**, *36*, 1104–1109. [[CrossRef](#)] [[PubMed](#)]
12. Durko, A.P.; Budde, R.P.J.; Geleijnse, M.L.; Kappetein, A.P. Recognition, assessment and management of the mechanical complications of acute myocardial infarction. *Heart* **2018**, *104*, 1216–1223. [[CrossRef](#)] [[PubMed](#)]
13. Vahanian, A.; Beyersdorf, F.; Praz, F.; Milojevic, M.; Baldus, S.; Bauersachs, J.; Capodanno, D.; Conradi, L.; De Bonis, M.; De Paulis, R.; et al. 2021 ESC/EACTS Guidelines for the management of valvular heart disease: Developed by the Task Force for the management of valvular heart disease of the European Society of Cardiology (ESC) and the European Association for Cardio-Thoracic Surgery (EACTS). *Eur. Heart J.* **2022**, *43*, 561–632. [[CrossRef](#)] [[PubMed](#)]
14. Hennessey, B.; Sabatovicz, N.; Del Trigo, M. Acute Ischaemic Mitral Valve Regurgitation. *J. Clin. Med.* **2022**, *11*, 5526. [[CrossRef](#)]
15. Whiting, P.C.; Morgan-Hughes, N.J. Transesophageal echocardiographic findings in papillary muscle rupture. *Anesth. Analg.* **2005**, *101*, 1292–1293. [[CrossRef](#)] [[PubMed](#)]
16. Bouma, W.; Wijdh-den Hamer, I.J.; Koene, B.M.; Kuijpers, M.; Natour, E.; Erasmus, M.E.; Jainandunsing, J.S.; van der Horst, I.C.C.; Gorman, J.H.; Gorman, R.C.; et al. Long-term survival after mitral valve surgery for post-myocardial infarction papillary muscle rupture. *J. Cardiothorac. Surg.* **2015**, *10*, 11. [[CrossRef](#)]
17. Russo, A.; Suri, R.M.; Grigioni, F.; Roger, V.L.; Oh, J.K.; Mahoney, D.W.; Schaff, H.V.; Enriquez-Sarano, M. Clinical outcome after surgical correction of mitral regurgitation due to papillary muscle rupture. *Circulation* **2008**, *118*, 1528–1534. [[CrossRef](#)]
18. Adamo, M.; Curello, S.; Chiari, E.; Fiorina, C.; Chizzola, G.; Magatelli, M.; Locantore, E.; Cuminetti, G.; Lombardi, C.; Manzato, A.; et al. Percutaneous edge-to-edge mitral valve repair for the treatment of acute mitral regurgitation complicating myocardial infarction: A single centre experience. *Int. J. Cardiol.* **2017**, *234*, 53–57. [[CrossRef](#)]
19. Estévez-Loureiro, R.; Arzamendi, D.; Freixa, X.; Cardenal, R.; Carrasco-Chinchilla, F.; Serrador-Frutos, A.; Pan, M.; Sabaté, M.; Diaz, J.; Hernández, J.M.; et al. Percutaneous Mitral Valve Repair for Acute Mitral Regurgitation After an Acute Myocardial Infarction. *J. Am. Coll. Cardiol.* **2015**, *66*, 91–92. [[CrossRef](#)]
20. Birnbaum, Y.; Fishbein, M.C.; Blanche, C.; Siegel, R.J. Ventricular septal rupture after acute myocardial infarction. *N. Engl. J. Med.* **2002**, *347*, 1426–1432. [[CrossRef](#)]
21. Menon, V.; Webb, J.G.; Hillis, L.D.; Sleeper, L.A.; Abboud, R.; Dzavik, V.; Slater, J.N.; Forman, R.; Monrad, E.S.; Talley, J.D.; et al. Outcome and profile of ventricular septal rupture with cardiogenic shock after myocardial infarction: A report from the SHOCK Trial Registry. SHould we emergently revascularize Occluded Coronaries in cardiogenic shock? *J. Am. Coll. Cardiol.* **2000**, *36*, 1110–1116. [[CrossRef](#)]
22. Crenshaw, B.S.; Granger, C.B.; Birnbaum, Y.; Pieper, K.S.; Morris, D.C.; Kleiman, N.S.; Vahanian, A.; Califf, R.M.; Topol, E.J. Risk factors, angiographic patterns, and outcomes in patients with ventricular septal defect complicating acute myocardial infarction. GUSTO-I (Global Utilization of Streptokinase and TPA for Occluded Coronary Arteries) Trial Investigators. *Circulation* **2000**, *101*, 27–32. [[CrossRef](#)] [[PubMed](#)]
23. Honda, S.; Asaumi, Y.; Yamane, T.; Nagai, T.; Miyagi, T.; Noguchi, T.; Anzai, T.; Goto, Y.; Ishihara, M.; Nishimura, K.; et al. Trends in the clinical and pathological characteristics of cardiac rupture in patients with acute myocardial infarction over 35 years. *J. Am. Heart Assoc.* **2014**, *3*, e000984. [[CrossRef](#)] [[PubMed](#)]
24. Jones, B.M.; Kapadia, S.R.; Smedira, N.G.; Robich, M.; Tuzcu, E.M.; Menon, V.; Krishnaswamy, A. Ventricular septal rupture complicating acute myocardial infarction: A contemporary review. *Eur. Heart J.* **2014**, *35*, 2060–2068. [[CrossRef](#)] [[PubMed](#)]
25. Moreyra, A.E.; Huang, M.S.; Wilson, A.C.; Deng, Y.; Cosgrove, N.M.; Kostis, J.B. MIDAS Study Group (MIDAS 13) Trends in incidence and mortality rates of ventricular septal rupture during acute myocardial infarction. *Am. J. Cardiol.* **2010**, *106*, 1095–1100. [[CrossRef](#)] [[PubMed](#)]
26. Delmas, C.; Barbosa, H.; David, C.-H.; Bouisset, F.; Piriou, P.-G.; Roubille, F.; Leick, J.; Pavlov, M.; Leurent, G.; Potapov, E.V.; et al. Impella for the Management of Ventricular Septal Defect Complicating Acute Myocardial Infarction: A European Multicenter Registry. *ASAIO J.* **2023**, *69*, e491. [[CrossRef](#)] [[PubMed](#)]
27. Daggett, W.M.; Guyton, R.A.; Mundth, E.D.; Buckley, M.J.; McEnany, M.T.; Gold, H.K.; Leinbach, R.C.; Austen, W.G. Surgery for post-myocardial infarct ventricular septal defect. *Ann. Surg.* **1977**, *186*, 260–271. [[CrossRef](#)]
28. David, T.E.; Dale, L.; Sun, Z. Postinfarction ventricular septal rupture: Repair by endocardial patch with infarct exclusion. *J. Thorac. Cardiovasc. Surg.* **1995**, *110*, 1315–1322. [[CrossRef](#)]
29. Singh, V.; Rodriguez, A.P.; Bhatt, P.; Alfonso, C.E.; Sakhuja, R.; Palacios, I.F.; Inglessis-Azuaje, I.; Cohen, M.G.; Elmariah, S.; O'Neill, W.W. Ventricular Septal Defect Complicating ST-Elevation Myocardial Infarctions: A Call for Action. *Am. J. Med.* **2017**, *130*, e863.e1–e863.e12. [[CrossRef](#)]
30. Ibanez, B.; James, S.; Agewall, S.; Antunes, M.J.; Bucciarelli-Ducci, C.; Bueno, H.; Caforio, A.L.P.; Crea, F.; Goudevenos, J.A.; Halvorsen, S.; et al. 2017 ESC Guidelines for the management of acute myocardial infarction in patients presenting with ST-segment elevation: The Task Force for the management of acute myocardial infarction in patients presenting with ST-segment elevation of the European Society of Cardiology (ESC). *Eur. Heart J.* **2018**, *39*, 119–177. [[CrossRef](#)]

31. Ronco, D.; Matteucci, M.; Kowalewski, M.; De Bonis, M.; Formica, F.; Jiritano, F.; Fina, D.; Folliguet, T.; Bonaros, N.; Russo, C.F.; et al. Surgical Treatment of Postinfarction Ventricular Septal Rupture. *JAMA Netw. Open* **2021**, *4*, e2128309. [\[CrossRef\]](#) [\[PubMed\]](#)
32. Faccini, A.; Butera, G. Techniques, Timing, and Prognosis of Transcatheter Post Myocardial Infarction Ventricular Septal Defect Repair. *Curr. Cardiol. Rep.* **2019**, *21*, 59. [\[CrossRef\]](#) [\[PubMed\]](#)
33. Calvert, P.A.; Cockburn, J.; Wynne, D.; Ludman, P.; Rana, B.S.; Northridge, D.; Mullen, M.J.; Malik, I.; Turner, M.; Khogali, S.; et al. Percutaneous closure of postinfarction ventricular septal defect: In-hospital outcomes and long-term follow-up of UK experience. *Circulation* **2014**, *129*, 2395–2402. [\[CrossRef\]](#) [\[PubMed\]](#)
34. Becker, A.E.; van Mantgem, J.P. Cardiac tamponade. A study of 50 hearts. *Eur. J. Cardiol.* **1975**, *3*, 349–358. [\[PubMed\]](#)
35. Slater, J.; Brown, R.J.; Antonelli, T.A.; Menon, V.; Boland, J.; Col, J.; Dzavik, V.; Greenberg, M.; Menegus, M.; Connery, C.; et al. Cardiogenic shock due to cardiac free-wall rupture or tamponade after acute myocardial infarction: A report from the SHOCK Trial Registry. Should we emergently revascularize occluded coronaries for cardiogenic shock? *J. Am. Coll. Cardiol.* **2000**, *36*, 1117–1122. [\[CrossRef\]](#) [\[PubMed\]](#)
36. Reardon, M.J.; Carr, C.L.; Diamond, A.; Letsou, G.V.; Safi, H.J.; Espada, R.; Baldwin, J.C. Ischemic left ventricular free wall rupture: Prediction, diagnosis, and treatment. *Ann. Thorac. Surg.* **1997**, *64*, 1509–1513. [\[CrossRef\]](#) [\[PubMed\]](#)
37. Formica, F.; Mariani, S.; Singh, G.; D'Alessandro, S.; Messina, L.A.; Jones, N.; Bamodu, O.A.; Sangalli, F.; Paolini, G. Postinfarction left ventricular free wall rupture: A 17-year single-centre experience. *Eur. J. Cardiothorac. Surg.* **2018**, *53*, 150–156. [\[CrossRef\]](#)
38. Matteucci, M.; Fina, D.; Jiritano, F.; Meani, P.; Blankesteijn, W.M.; Raffa, G.M.; Kowaleski, M.; Heuts, S.; Beghi, C.; Maessen, J.; et al. Treatment strategies for post-infarction left ventricular free-wall rupture. *Eur. Heart J. Acute Cardiovasc. Care* **2019**, *8*, 379–387. [\[CrossRef\]](#)
39. Yeo, T.C.; Malouf, J.F.; Oh, J.K.; Seward, J.B. Clinical profile and outcome in 52 patients with cardiac pseudoaneurysm. *Ann. Intern. Med.* **1998**, *128*, 299–305. [\[CrossRef\]](#)
40. Meizlish, J.L.; Berger, H.J.; Plankey, M.; Errico, D.; Levy, W.; Zaret, B.L. Functional left ventricular aneurysm formation after acute anterior transmural myocardial infarction. Incidence, natural history, and prognostic implications. *N. Engl. J. Med.* **1984**, *311*, 1001–1006. [\[CrossRef\]](#)
41. Tikiz, H.; Balbay, Y.; Atak, R.; Terzi, T.; Genç, Y.; Kütük, E. The effect of thrombolytic therapy on left ventricular aneurysm formation in acute myocardial infarction: Relationship to successful reperfusion and vessel patency. *Clin. Cardiol.* **2001**, *24*, 656–662. [\[CrossRef\]](#)
42. Konen, E.; Merchant, N.; Gutierrez, C.; Provost, Y.; Mickleborough, L.; Paul, N.S.; Butany, J. True versus False Left Ventricular Aneurysm: Differentiation with MR Imaging—Initial Experience. *Radiology* **2005**, *236*, 65–75. [\[CrossRef\]](#) [\[PubMed\]](#)
43. Tuan, J.; Kaivani, F.; Fewins, H. Left ventricular pseudoaneurysm. *Eur. J. Echocardiogr.* **2008**, *9*, 107–109. [\[CrossRef\]](#)
44. Atik, F.A.; Navia, J.L.; Vega, P.R.; Gonzalez-Stawinski, G.V.; Alster, J.M.; Gillinov, A.M.; Svensson, L.G.; Pettersson, B.G.; Lytle, B.W.; Blackstone, E.H. Surgical treatment of postinfarction left ventricular pseudoaneurysm. *Ann. Thorac. Surg.* **2007**, *83*, 526–531. [\[CrossRef\]](#) [\[PubMed\]](#)
45. Faxon, D.P.; Ryan, T.J.; Davis, K.B.; McCabe, C.H.; Myers, W.; Lesperance, J.; Shaw, R.; Tong, T.G. Prognostic significance of angiographically documented left ventricular aneurysm from the Coronary Artery Surgery Study (CASS). *Am. J. Cardiol.* **1982**, *50*, 157–164. [\[CrossRef\]](#) [\[PubMed\]](#)
46. Authors/Task Force members; Windecker, S.; Kolh, P.; Alfonso, F.; Collet, J.-P.; Cremer, J.; Falk, V.; Filippatos, G.; Hamm, C.; Head, S.J.; et al. 2014 ESC/EACTS Guidelines on myocardial revascularization: The Task Force on Myocardial Revascularization of the European Society of Cardiology (ESC) and the European Association for Cardio-Thoracic Surgery (EACTS) Developed with the special contribution of the European Association of Percutaneous Cardiovascular Interventions (EAPCI). *Eur. Heart J.* **2014**, *35*, 2541–2619. [\[CrossRef\]](#) [\[PubMed\]](#)
47. Hochman, J.S.; Buller, C.E.; Sleeper, L.A.; Boland, J.; Dzavik, V.; Sanborn, T.A.; Godfrey, E.; White, H.D.; Lim, J.; LeJemtel, T. Cardiogenic shock complicating acute myocardial infarction—etiologies, management and outcome: A report from the SHOCK Trial Registry. Should we emergently revascularize Occluded Coronaries for cardiogenic shock? *J. Am. Coll. Cardiol.* **2000**, *36*, 1063–1070. [\[CrossRef\]](#)
48. Thiele, H.; Zeymer, U.; Neumann, F.-J.; Ferenc, M.; Olbrich, H.-G.; Hausleiter, J.; Richardt, G.; Hennersdorf, M.; Empen, K.; Fuernau, G.; et al. Intraaortic Balloon Support for Myocardial Infarction with Cardiogenic Shock. *N. Engl. J. Med.* **2012**, *367*, 1287–1296. [\[CrossRef\]](#)
49. Bernhardt, A.M.; Copeland, H.; Deswal, A.; Gluck, J.; Givertz, M.M.; Bernhardt, A.M.; Gluck, J.; Garan, A.R.; Hall, S.; Hayanga, A.; et al. The International Society for Heart and Lung Transplantation/Heart Failure Society of America Guideline on Acute Mechanical Circulatory Support. *J. Heart Lung Transplant.* **2023**, *42*, e1–e64. [\[CrossRef\]](#)
50. Members, A.F.; McDonagh, T.A.; Metra, M.; Adamo, M.; Gardner, R.S.; Baumbach, A.; Böhm, M.; Burri, H.; Butler, J.; Čelutkienė, J.; et al. 2021 ESC Guidelines for the diagnosis and treatment of acute and chronic heart failure. *Eur. J. Heart Fail.* **2022**, *24*, 4–131. [\[CrossRef\]](#)
51. Thiele, H.; Zeymer, U.; Akin, I.; Behnes, M.; Rassaf, T.; Mahabadi, A.A.; Lehmann, R.; Eitel, I.; Graf, T.; Seidler, T.; et al. Extracorporeal Life Support in Infarct-Related Cardiogenic Shock. *N. Engl. J. Med.* **2023**, *389*, 1286–1297. [\[CrossRef\]](#) [\[PubMed\]](#)
52. Taleb, I.; Koliopoulou, A.G.; Tandar, A.; McKellar, S.H.; Tonna, J.E.; Nativi-Nicolau, J.; Alvarez Villela, M.; Welt, F.; Stehlik, J.; Gilbert, E.M.; et al. Shock Team Approach in Refractory Cardiogenic Shock Requiring Short-Term Mechanical Circulatory Support: A Proof of Concept. *Circulation* **2019**, *140*, 98–100. [\[CrossRef\]](#) [\[PubMed\]](#)

53. Kim, D.H. Mechanical Circulatory Support in Cardiogenic Shock: Shock Team or Bust? *Can. J. Cardiol.* **2020**, *36*, 197–204. [CrossRef] [PubMed]
54. Wilson-Smith, A.R.; Bogdanova, Y.; Roydhouse, S.; Phan, K.; Tian, D.H.; Yan, T.D.; Loforte, A. Outcomes of venoarterial extracorporeal membrane oxygenation for refractory cardiogenic shock: Systematic review and meta-analysis. *Ann. Cardiothorac. Surg.* **2019**, *8*, 1–8. [CrossRef] [PubMed]
55. Delmas, C.; Vandenbriele, C.; Pappalardo, F.; Roubille, F. What about current recommendations for extracorporeal life support in acute myocardial infarction-associated cardiogenic shock: Stay or go? or time to revise? *Eur. J. Heart Fail.* **2023**, *25*, 2102–2104. [CrossRef]
56. O'Rourke, R.A.; Dell'italia, L.J. Diagnosis and management of right ventricular myocardial infarction. *Curr. Probl. Cardiol.* **2004**, *29*, 6–47. [CrossRef]
57. Antman, E.M.; Anbe, D.T.; Armstrong, P.W.; Bates, E.R.; Green, L.A.; Hand, M.; Hochman, J.S.; Krumholz, H.M.; Kushner, F.G.; Lamas, G.A.; et al. ACC/AHA guidelines for the management of patients with ST-elevation myocardial infarction—executive summary: A report of the American College of Cardiology/American Heart Association Task Force on Practice Guidelines (Writing Committee to Revise the 1999 Guidelines for the Management of Patients with Acute Myocardial Infarction). *Circulation* **2004**, *110*, 588–636. [CrossRef]
58. Grothoff, M.; Elpert, C.; Hoffmann, J.; Zachrau, J.; Lehmkuhl, L.; de Waha, S.; Desch, S.; Eitel, I.; Mende, M.; Thiele, H.; et al. Right ventricular injury in ST-elevation myocardial infarction: Risk stratification by visualization of wall motion, edema, and delayed-enhancement cardiac magnetic resonance. *Circ. Cardiovasc. Imaging* **2012**, *5*, 60–68. [CrossRef]
59. Hrovatin, E.; Piazza, R.; Pavan, D.; Mimo, R.; Macor, F.; Dall'Aglio, V.; Burelli, C.; Cassin, M.; Canterin, F.A.; Brieda, M.; et al. Dynamic Left Ventricular Outflow Tract Obstruction in the Setting of Acute Anterior Myocardial Infarction: A Serious and Potentially Fatal Complication? *Echocardiography* **2002**, *19*, 449–455. [CrossRef]
60. Dynamic Left Ventricular Outflow Tract Obstruction in Acute Myocardial Infarction with Shock. Available online: <https://www.ahajournals.org/doi/epub/10.1161/CIRCULATIONAHA.107.711697> (accessed on 17 November 2023).
61. Brown, M.L.; Abel, M.D.; Click, R.L.; Morford, R.G.; Dearani, J.A.; Sundt, T.M.; Orszulak, T.A.; Schaff, H.V. Systolic anterior motion after mitral valve repair: Is surgical intervention necessary? *J. Thorac. Cardiovasc. Surg.* **2007**, *133*, 136–143. [CrossRef]
62. Cohen, R.; Rivagorda, J.; Elhadad, S. Asymmetric septal hypertrophy complicated by dynamic left ventricular obstruction after intra-aortic balloon counterpulsation placement in the setting of anterior myocardial infarction. *J. Invasive Cardiol.* **2006**, *18*, E207–E208. [PubMed]
63. Lee, T.H.; Goldman, L. The Coronary Care Unit Turns 25: Historical Trends and Future Directions. *Ann. Intern. Med.* **1988**, *108*, 887–894. [CrossRef] [PubMed]
64. Huizar, J.F.; Ellenbogen, K.A.; Tan, A.Y.; Kaszala, K. Arrhythmia-Induced Cardiomyopathy: JACC State-of-the-Art Review. *J. Am. Coll. Cardiol.* **2019**, *73*, 2328–2344. [CrossRef] [PubMed]
65. Mayuga, K.A.; Fedorowski, A.; Ricci, F.; Gopinathannair, R.; Dukes, J.W.; Gibbons, C.; Hanna, P.; Sorajja, D.; Chung, M.; Benditt, D.; et al. Sinus Tachycardia: A Multidisciplinary Expert Focused Review. *Circ. Arrhythmia Electrophysiol.* **2022**, *15*, e007960. [CrossRef] [PubMed]
66. Benjamin, E.J.; Wolf, P.A.; D'Agostino, R.B.; Silbershatz, H.; Kannel, W.B.; Levy, D. Impact of atrial fibrillation on the risk of death: The Framingham Heart Study. *Circulation* **1998**, *98*, 946–952. [CrossRef]
67. Kannel, W.B.; Benjamin, E.J. Status of the epidemiology of atrial fibrillation. *Med. Clin. N. Am.* **2008**, *92*, 17–40, ix. [CrossRef] [PubMed]
68. Lavie, C.J.; Gersh, B.J. Acute Myocardial Infarction: Initial Manifestations, Management, and Prognosis. *Mayo Clin. Proc.* **1990**, *65*, 531–548. [CrossRef]
69. 2023 ACC/AHA/ACCP/HRS Guideline for the Diagnosis and Management of Atrial Fibrillation: A Report of the American College of Cardiology/American Heart Association Joint Committee on Clinical Practice Guidelines | Journal of the American College of Cardiology. Available online: <https://www.jacc.org/doi/abs/10.1016/j.jacc.2023.08.017> (accessed on 12 January 2024).
70. Ding, W.Y.; Blomström-Lundqvist, C.; Fauchier, L.; Marin, F.; Potpara, T.S.; Boriani, G.; Lip, G.Y.H.; The ESC-EHRA EORP-AF Long-Term General Registry Investigators. Contemporary management of atrial fibrillation and the predicted vs. absolute risk of ischaemic stroke despite treatment: A report from ESC-EHRA EORP-AF Long-Term General Registry. *EP Eur.* **2023**, *25*, 277–282. [CrossRef]
71. Bhar-Amato, J.; Davies, W.; Agarwal, S. Ventricular Arrhythmia after Acute Myocardial Infarction: 'The Perfect Storm'. *Arrhythm. Electrophysiol. Rev.* **2017**, *6*, 134–139. [CrossRef]
72. Mont, L.; Cinca, J.; Blanch, P.; Blanco, J.; Figueras, J.; Brotons, C.; Soler-Soler, J. Predisposing Factors and Prognostic Value of Sustained Monomorphic Ventricular Tachycardia in the Early Phase of Acute Myocardial Infarction. *J. Am. Coll. Cardiol.* **1996**, *28*, 1670–1676. [CrossRef]
73. Zwerling, H.K. Does exogenous magnesium suppress myocardial irritability and tachyarrhythmias in the nondigitalized patient? *Am. Heart J.* **1987**, *113*, 1046–1053. [CrossRef] [PubMed]
74. Al-Khatib, S.M.; Stevenson, W.G.; Ackerman, M.J.; Bryant, W.J.; Callans, D.J.; Curtis, A.B.; Deal, B.J.; Dickfeld, T.; Field, M.E.; Fonarow, G.C.; et al. 2017 AHA/ACC/HRS Guideline for Management of Patients with Ventricular Arrhythmias and the Prevention of Sudden Cardiac Death. *Circulation* **2018**, *138*, e272–e391. [CrossRef]

75. Kusumoto, F.M.; Calkins, H.; Boehmer, J.; Buxton, A.E.; Chung, M.K.; Gold, M.R.; Hohnloser, S.H.; Indik, J.; Lee, R.; Mehra, M.R.; et al. HRS/ACC/AHA Expert Consensus Statement on the Use of Implantable Cardioverter-Defibrillator Therapy in Patients Who Are Not Included or Not Well Represented in Clinical Trials. *Circulation* **2014**, *130*, 94–125. [\[CrossRef\]](#) [\[PubMed\]](#)
76. Meine, T.J.; Al-Khatib, S.M.; Alexander, J.H.; Granger, C.B.; White, H.D.; Kilaru, R.; Williams, K.; Ohman, E.M.; Topol, E.; Califf, R.M. Incidence, predictors, and outcomes of high-degree atrioventricular block complicating acute myocardial infarction treated with thrombolytic therapy. *Am. Heart J.* **2005**, *149*, 670–674. [\[CrossRef\]](#) [\[PubMed\]](#)
77. Onodera, S.; Ito, M.; Odakura, H.; Yagi, T.; Namekawa, A.; Sato, T.; Nagashima, M.; Shinoda, S.; Suzuki, H. Atrioventricular block in acute inferior myocardial infarction. *Kokyu Junkan* **1992**, *40*, 255–260.
78. Alnsasra, H.; Ben-Avraham, B.; Gottlieb, S.; Ben-avraham, M.; Kronowski, R.; Iakobishvili, Z.; Goldenberg, I.; Strasberg, B.; Haim, M. High-grade atrioventricular block in patients with acute myocardial infarction. Insights from a contemporary multi-center survey. *J. Electrocardiol.* **2018**, *51*, 386–391. [\[CrossRef\]](#)
79. Harikrishnan, P.; Gupta, T.; Palaniswamy, C.; Kolte, D.; Khera, S.; Mujib, M.; Aronow, W.S.; Ahn, C.; Sule, S.; Jain, D.; et al. Complete Heart Block Complicating ST-Segment Elevation Myocardial Infarction. *JACC Clin. Electrophysiol.* **2015**, *1*, 529–538. [\[CrossRef\]](#)
80. Hauer, R.N.W.; Lie, K.I.; Liem, K.L.; Durrer, D. Long-term prognosis in patients with bundle branch block complicating acute anteroseptal infarction. *Am. J. Cardiol.* **1982**, *49*, 1581–1585. [\[CrossRef\]](#)
81. Scheinman, M.M.; Thorburn, D.; Abbott, J.A. Use of atropine in patients with acute myocardial infarction and sinus bradycardia. *Circulation* **1975**, *52*, 627–633. [\[CrossRef\]](#)
82. Brady, W.J.; Swart, G.; DeBehnke, D.J.; Ma, O.J.; Aufderheide, T.P. The efficacy of atropine in the treatment of hemodynamically unstable bradycardia and atrioventricular block: Prehospital and emergency department considerations. *Resuscitation* **1999**, *41*, 47–55. [\[CrossRef\]](#)
83. Yaqub, Y.; Perez-Verdia, A.; Jenkins, L.A.; Sehli, S.; Paige, R.L.; Nugent, K.M. Temporary Transvenous Cardiac Pacing in Patients with Acute Myocardial Infarction Predicts Increased Mortality. *Cardiol. Res.* **2012**, *3*, 1–7. [\[CrossRef\]](#) [\[PubMed\]](#)
84. Kusumoto, F.M.; Schoenfeld, M.H.; Barrett, C.; Edgerton, J.R.; Ellenbogen, K.A.; Gold, M.R.; Goldschlager, N.F.; Hamilton, R.M.; Joglar, J.A.; Kim, R.J.; et al. 2018 ACC/AHA/HRS Guideline on the Evaluation and Management of Patients with Bradycardia and Cardiac Conduction Delay: A Report of the American College of Cardiology/American Heart Association Task Force on Clinical Practice Guidelines and the Heart Rhythm Society. *Circulation* **2019**, *140*, e382–e482. [\[CrossRef\]](#) [\[PubMed\]](#)
85. Waltenberger, J.; Gelissen, M.; Bekkers, S.C.; Vainer, J.; van Ommen, V.; Eerens, F.; Ruiters, A.; Holthuisen, A.; Cuesta, P.; Strauven, R.; et al. Clinical Pacing Post-Conditioning During Revascularization After AMI. *JACC Cardiovasc. Imaging* **2014**, *7*, 620–626. [\[CrossRef\]](#) [\[PubMed\]](#)
86. Fioretti, P.; Brower, R.W.; Balakumaran, K. Early Post-Infarction Angina. Incidence and Prognostic Relevance. *Eur. Heart J.* **1986**, *7*, 73–77. [\[CrossRef\]](#) [\[PubMed\]](#)
87. Hutchins, G.M.; Bulkley, B.H. Infarct expansion versus extension: Two different complications of acute myocardial infarction. *Am. J. Cardiol.* **1978**, *41*, 1127–1132. [\[CrossRef\]](#)
88. Reid, P.R.; Taylor, D.R.; Kelly, D.T.; Weisfeldt, M.L.; Humphries, J.O.; Ross, R.S.; Pitt, B. Myocardial-infarct extension detected by precordial ST-segment mapping. *N. Engl. J. Med.* **1974**, *290*, 123–128. [\[CrossRef\]](#) [\[PubMed\]](#)
89. Williams, D.B.; Ivey, T.D.; Bailey, W.W.; Irey, S.J.; Rideout, J.T.; Stewart, D. Postinfarction angina: Results of early revascularization. *J. Am. Coll. Cardiol.* **1983**, *2*, 859–864. [\[CrossRef\]](#)
90. Dorfman, T.A.; Aqel, R. Regional Pericarditis: A Review of the Pericardial Manifestations of Acute Myocardial Infarction. *Clin. Cardiol.* **2009**, *32*, 115–120. [\[CrossRef\]](#)
91. Tofler, G.H.; Muller, J.E.; Stone, P.H.; Willich, S.N.; Davis, V.G.; Poole, W.K.; Robertson, T.; Braunwald, E. Pericarditis in acute myocardial infarction: Characterization and clinical significance. *Am. Heart J.* **1989**, *117*, 86–92. [\[CrossRef\]](#)
92. Indik, J.H.; Alpert, J.S. Post-myocardial infarction pericarditis. *Curr. Treat. Options Cardio Med.* **2000**, *2*, 351–355. [\[CrossRef\]](#)
93. Verma, B.R.; Montane, B.; Chetrit, M.; Khayata, M.; Furqan, M.M.; Ayoub, C.; Klein, A.L. Pericarditis and Post-cardiac Injury Syndrome as a Sequelae of Acute Myocardial Infarction. *Curr. Cardiol. Rep.* **2020**, *22*, 127. [\[CrossRef\]](#) [\[PubMed\]](#)
94. Doulaptsis, C.; Goetschalckx, K.; Masci, P.G.; Florian, A.; Janssens, S.; Bogaert, J. Assessment of Early Post-Infarction Pericardial Injury by CMR. *JACC Cardiovasc. Imaging* **2013**, *6*, 411–413. [\[CrossRef\]](#)
95. Hirsh, J.; Fuster, V.; Ansell, J.; Halperin, J.L. American Heart Association/American College of Cardiology Foundation Guide to Warfarin Therapy. *Circulation* **2003**, *107*, 1692–1711. [\[CrossRef\]](#) [\[PubMed\]](#)
96. Asinger, R.W.; Mikell, F.L.; Elspenger, J.; Hodges, M. Incidence of Left-Ventricular Thrombosis after Acute Transmural Myocardial Infarction. *N. Engl. J. Med.* **1981**, *305*, 297–302. [\[CrossRef\]](#)
97. Jugdutt, B.I.; Sivaram, C.A.; Wortman, C.; Trudell, C.; Penner, P. Prospective two-dimensional echocardiographic evaluation of left ventricular thrombus and embolism after acute myocardial infarction. *J. Am. Coll. Cardiol.* **1989**, *13*, 554–564. [\[CrossRef\]](#) [\[PubMed\]](#)
98. Glueck, H.I.; Ryder, H.W.; Wasserman, P. The Prevention of Thromboembolic Complications in Myocardial Infarction by Anticoagulant Therapy. *Circulation* **1956**, *13*, 884–895. [\[CrossRef\]](#) [\[PubMed\]](#)
99. Lattuca, B.; Bouziri, N.; Kerneis, M.; Portal, J.-J.; Zhou, J.; Hauguel-Moreau, M.; Mameri, A.; Zeitouni, M.; Guedeney, P.; Hammoudi, N.; et al. Antithrombotic Therapy for Patients with Left Ventricular Mural Thrombus. *J. Am. Coll. Cardiol.* **2020**, *75*, 1676–1685. [\[CrossRef\]](#)

100. Chen, M.; Liu, D.; Weidemann, F.; Lengenfelder, B.D.; Ertl, G.; Hu, K.; Frantz, S.; Nordbeck, P. Echocardiographic risk factors of left ventricular thrombus in patients with acute anterior myocardial infarction. *ESC Heart Fail.* **2021**, *8*, 5248–5258. [[CrossRef](#)]
101. Shibata, T.; Kawakami, S.; Noguchi, T.; Tanaka, T.; Asaumi, Y.; Kanaya, T.; Nagai, T.; Nakao, K.; Fujino, M.; Nagatsuka, K.; et al. Prevalence, Clinical Features, and Prognosis of Acute Myocardial Infarction Attributable to Coronary Artery Embolism. *Circulation* **2015**, *132*, 241–250. [[CrossRef](#)]
102. Delewi, R.; Zijlstra, F.; Piek, J.J. Left ventricular thrombus formation after acute myocardial infarction. *Heart* **2012**, *98*, 1743–1749. [[CrossRef](#)]

Disclaimer/Publisher’s Note: The statements, opinions and data contained in all publications are solely those of the individual author(s) and contributor(s) and not of MDPI and/or the editor(s). MDPI and/or the editor(s) disclaim responsibility for any injury to people or property resulting from any ideas, methods, instructions or products referred to in the content.