


Article

Efficacy and Safety of Monopolar Radiofrequency for Tightening the Skin of Aged Faces

JungMin Shin [†], Yeounkuk Sung [†], Soyoung Jin, Cho-Long Hwang, Hyunjung Kim, Dongkyun Hong, Kyung Eun Jung, Young-Joon Seo and Young Lee ^{*}

Department of Dermatology, Chungnam National University School of Medicine, Daejeon 35015, Republic of Korea; shahjm__@naver.com (J.S.); sungyk10@naver.com (Y.S.); syjin0623@naver.com (S.J.); kingcho1017@nate.com (C.-L.H.); caspase@hanmail.net (H.K.); chupee@hanmail.net (D.H.); jke0224@hanmail.net (K.E.J.); seoyj4u@gmail.com (Y.-J.S.)

^{*} Correspondence: resina20@gmail.com

[†] These authors contributed equally to this work.

Abstract: Background: Monopolar radiofrequency (RF) has emerged as a promising modality for tightening the skin of aged faces. Although many studies have assessed the efficacy of monopolar RF via the clinical evaluation of photographs, few have examined the long-term effectiveness and safety of this therapy using various skin testing devices. Methods: Twenty women with aged faces participated in this study. After a single monopolar RF treatment, three blinded dermatologists who were not involved in the treatment evaluated its clinical efficacy and safety after 4, 12, and 24 weeks. Skin firmness, fine wrinkles, skin pores, and skin tone were also measured using an indentometer (Courage+Khazaka Electronic GmbH, Köln, Germany) and a facial aging measurement device (Mark-Vu; PSI Plus, Suwon-si, Republic of Korea). Results: Skin laxity in the jowls and nasolabial folds showed significant improvement 12 weeks after the single monopolar RF treatment when evaluated by dermatologists, and this improvement lasted 24 weeks ($p < 0.05$). Moreover, the participants reported improvement at 4 weeks compared to baseline which lasted 24 weeks ($p < 0.05$). Skin firmness measured in the cheek increased 4 weeks after treatment and continued to improve during 24 weeks of follow-up ($p < 0.01$). Although there was a gradual increase in improvement in skin pores, fine wrinkles, and skin tones, there were no statistical differences compared to the baseline. No patients experienced pain during the treatment, and no burns, skin breakdown, or scarring occurred after treatment. Conclusions: A single monopolar RF treatment is effective for females with aged face. A significant improvement in the jowls and nasolabial folds and facial skin firmness was observed between the 4- and 24-week follow-ups without adverse effects.

Keywords: aging; facial laxity; monopolar radiofrequency; skin tightening



Citation: Shin, J.; Sung, Y.; Jin, S.; Hwang, C.-L.; Kim, H.; Hong, D.; Jung, K.E.; Seo, Y.-J.; Lee, Y. Efficacy and Safety of Monopolar Radiofrequency for Tightening the Skin of Aged Faces. *Cosmetics* **2024**, *11*, 71. <https://doi.org/10.3390/cosmetics11030071>

Academic Editors: Vasil Georgiev and Kazuhisa Maeda

Received: 7 March 2024

Revised: 18 April 2024

Accepted: 1 May 2024

Published: 3 May 2024



Copyright: © 2024 by the authors. Licensee MDPI, Basel, Switzerland. This article is an open access article distributed under the terms and conditions of the Creative Commons Attribution (CC BY) license (<https://creativecommons.org/licenses/by/4.0/>).

1. Introduction

The pursuit of youthful, rejuvenated skin has been a timeless endeavor, particularly in the context of facial aesthetics. As individuals age, the skin undergoes physiological changes characterized by decreased collagen production, the loss of elasticity, and the emergence of fine lines and wrinkles [1]. In response to these natural processes, various noninvasive and minimally invasive techniques aimed at restoring skin vitality and tightness have been developed in the fields of dermatology and cosmetic medicine [2,3].

Among these techniques, monopolar radiofrequency (RF) has emerged as a promising modality for tightening the skin of aged faces. The Food and Drug Administration subsequently approved RF therapy for treating facial skin in 2006. The applications of RF therapy have since expanded to the cosmetic treatment of cervical, abdominal, and femoral skin [4]. Monopolar RF utilizes electromagnetic waves to generate controlled heat within the dermal layers, stimulating collagen synthesis and remodeling while also promoting tissue contraction [5]. Its nonablative nature and ability to penetrate the skin make it an

attractive option for addressing laxity and wrinkles without the downtime associated with more invasive procedures [6,7].

The efficacy and safety of monopolar RF for tightening the skin of aged faces have garnered considerable attention in clinical practice and academic research. There are even reports combining regimens with monopolar RF and intense-focused ultrasound in facial lifting and tightening. Usually, subjective satisfactions are generally consistent with objective findings investigated by experts. However, few studies have evaluated the objective efficacy of monopolar RF using facial aging measurement devices. Moreover, there are few reports measuring skin firmness after monopolar RF treatment. In the present study, we critically evaluated the existing evidence for the utility of monopolar RF in facial rejuvenation and measured skin firmness, facial pores, fine wrinkles, and skin tone using a facial aging measurement device [8,9]. Moreover, we performed regular follow-ups for 6 months to determine how long the effect of a single monopolar RF treatment lasts.

2. Materials and Methods

2.1. Participants and Study Design

This prospective, evaluator-blinded cohort study was conducted at the department of dermatology of a tertiary university hospital. Twenty healthy female volunteers aged 42–60 years were enrolled. All participants had Fitzpatrick skin type III or IV with mild-to-moderate facial laxity. The degree of sagging in the face before and after treatment was divided into five groups, none (0 points), mild (1 point), moderate (2 points), severe (3 points), and very severe (4 points), using the Merz skin laxity scale [10–12]. The participants in grades 1 and 2 were enrolled in this study. The exclusion criteria were any previous treatment with topical retinoid cream, oral retinoids, or laser therapy in the last 2 months; inserting a filler into the face or a metal device into the body; and pregnancy or lactation. This study was approved by the Institutional Review Board of Chungnam National University Hospital (CNUH 2021-10-012). All participants provided written informed consent before the commencement of the study.

2.2. RF Therapy

The patients received a single monopolar RF treatment (Oligio; WONTECH Co., Ltd., Daejeon, Republic of Korea) on day 0. The monopolar RF was delivered with a 2 cm × 2 cm tip at a fluence of 6.78 MHz. A grounding pad was placed on the participants' lower backs. During treatment, thermal energy produced by RF was delivered in stamped mode with multiple passes with a 15–30% overlap of tips. In total, 600 shots were administered to the face, including 400 to the cheeks and lower crown, 100 to the chin, and 100 around the eye area. The treatment energy level (fluence at level) ranged from 3 (13 J/cm²) to 4 (16 J/cm²), according to the patient's feedback on pain during the treatment. No patients applied topical anesthetic cream prior to the treatment, and the patients were instructed to avoid using topical ointments, oral medications, or other laser treatments during the study period.

2.3. Clinical Outcome Evaluation

The participants' faces were serially photographed from the frontal, left, and right oblique views at the beginning of the treatment and at 4, 12, and 24 weeks to evaluate the improvement. Three blinded board-certified dermatologists who were not involved in the treatment evaluated the improvement in skin laxity at each visit using photographs. A 6-point scale was employed to determine the degree of skin laxity: −1 = worse, 0 = no change, 1 = slight improvement, 2 = moderate improvement, 3 = marked improvement, and 4 = excellent improvement. The participants' satisfaction was evaluated using a 6-point scale: −1 = worse, 0 = no change, 1 = slight improvement (1–25%), 2 = moderate improvement (26–50%), 3 = marked improvement (51–75%), and 4 = excellent improvement (76–100%). We assessed the subjects' pain during and immediately after the procedure using a numerical rating scale; on a scale of 0 to 10, 0 means no pain, and 10 means the worst

pain you have ever felt. (0 = no pain; 1 = pain is very mild, barely noticeable; 2 = minor pain; 3 = noticeable pain. It may distract you, but you can get used to it; 4 = moderate pain. If you are involved in an activity, you can ignore the pain for a while; 5 = moderately strong pain; 6 = moderately stronger pain. You have trouble concentrating; 7 = strong pain. It keeps you from doing normal activities; 8 = extreme pain. It is hard to do anything at all; 9 = pain that is very hard to tolerate; 10 = worst pain possible.) [13] Finally, patients were asked to report any side effects during each visit.

2.4. Facial Firmness Measurement

We measured skin firmness on the cheek with an indentometer (Courage+Khazaka electronic GmbH, Köln, Germany) [14,15]. The tip was placed perpendicularly on the skin, and the force exerted by the spring on the tip causes deformation of the skin surface. The measurement principle relies on the force applied by the spring to the small indenter of the probe, which causes skin deformation. The device quantifies how the probe indenter displaces the skin, with the penetration depth of the pin (displacement) measured in millimeters (0–3 mm). Firmer skin results in less displacement by the pin. To ensure consistency, we measured the location 2 cm vertically downward from each patient's pupil on the cheek.

2.5. Skin Tone, Pores, and Fine Wrinkle Measurement

We measured the participants' skin tone, skin pores, and fine wrinkles using a facial aging measurement device (Mark-Vu; PSI Plus, Suwon-si, Republic of Korea). Before using the device, the participants were directed to remove their makeup to ensure precise skin analysis, and a proficient expert photographed the faces of the participants after eliminating external light interference. Alterations in pore impurities, skin tone, and skin radiance before and after monopolar RF were analyzed through images captured by a facial aging measurement device under three distinct lighting settings: normal light, specular light, and ultraviolet light. After capturing the facial skin photos, the software segmented the image into eight distinct zones: forehead, nose, next to right eye, next to left eye, under right eye and left eye, right cheek, and left cheek. Subsequently, it determined four to six specific regions deemed appropriate for analysis.

2.6. Statistical Analysis

All statistical analyses were performed using GraphPad Prism 8.0.1 for Windows (GraphPad Software, San Diego, CA, USA). The data were analyzed using a one-way analysis of variance and a *t*-test. A *p*-value < 0.05 was considered statistically significant.

3. Results

Twenty women with a mean age of 47.95 ± 6.02 years were enrolled. Their average level of facial skin laxity was 1.40 points on the Merz skin laxity scale. The mean monopolar RF treatment level was 3.80 ± 0.41 , and the total energy delivered was 36.60 ± 2.46 kJ (Table 1). Three blinded dermatologists who were not involved in the monopolar RF treatment evaluated skin tightening and lifting based on clinical photographs taken before and 4, 12, and 24 weeks after the RF treatment (Figure 1). The investigators' global assessment indicated no significant improvement at 4 weeks after treatment. At 12 weeks, however, the average score increased to 2.3 points, which was significantly higher than that at baseline, confirming moderate improvement. At 24 weeks after treatment, the average score was 1.87 points, indicating that the improvement was maintained compared with the baseline (Figure 2).

Facial skin firmness was measured on the cheek using an indentometer at every visit. Unexpectedly, the investigators observed significantly greater skin firmness at 4 weeks than at baseline. Moreover, skin firmness showed further improvement at weeks 12 and 24, indicating the long-lasting efficacy of a single monopolar RF treatment in terms of inducing collagen synthesis and dermal remodeling ($p < 0.01$) (Figure 3).

Table 1. Demographic data of patients.

Characteristic	
Age, mean ± SD	47.95 ± 6.02
Sex, no. (%)	
Female	20 (100)
Race/ethnicity	
Asian, no. (%)	20 (100)
Merz skin laxity scale, no. (%)	
Mild (1)	13 (65)
Moderate (2)	7 (35)
Severe (3)	0 (0)
Very severe (4)	0 (0)
Energy delivered by monopolar RF, no. (%)	
Total energy 37.80 kJ	16 (80)
Total energy 31.80 kJ	4 (20)

SD; standard deviation, RF; radiofrequency.

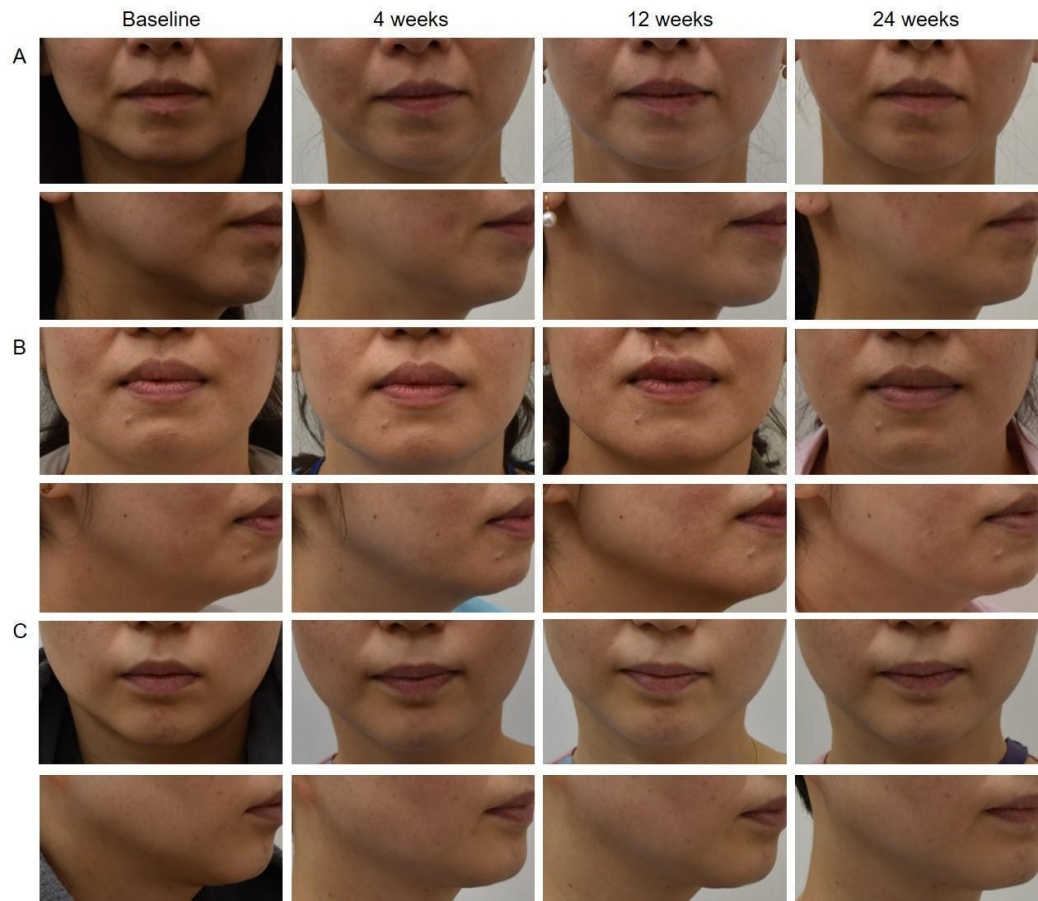

Figure 1. Photographs showing the clinical improvement of patients. The left column shows a baseline photo of the front and oblique view of patients (A–C). Tightening of the middle and lower face increased after 4 weeks and lasted for 24 weeks after treatment with monopolar RF. The patients showed skin tightening of the jowls and improvement in the nasolabial folds.

The participants’ satisfaction was assessed through questionnaires at every visit. Unlike the dermatologists’ clinical improvement assessments, the patients reported improvement at 4 weeks after RF treatment. The patients reported moderate improvement (49.15%) at 4 weeks after the procedure, substantial improvement (51.60%) at 12 weeks, and moderate improvement (45.25%) at 24 weeks compared with baseline ($p < 0.05$) (Figure 4). Checking the skin pores, fine wrinkles, and skin tone using a facial aging measurement

device showed a gradual improvement in all facial skin pores, wrinkles, and skin tone scores after treatment. The skin pore score was 57.15 ± 5.67 at baseline, 56.70 ± 5.52 at 4 weeks, 55.75 ± 5.41 at 12 weeks, and 55.70 ± 4.95 at 24 weeks. The fine wrinkle score was 28.90 ± 2.67 at baseline, 28.80 ± 2.63 at 4 weeks, 28.60 ± 2.52 at 12 weeks, and 28.35 ± 2.87 at 24 weeks. Lastly, the skin tone score was 56.00 ± 2.87 at baseline, 55.95 ± 2.93 at 4 weeks, 56.00 ± 3.11 at 12 weeks, and 55.25 ± 3.35 at 24 weeks. However, no statistically significant difference was seen among visits (Figure 5, Table 2). The average pain score during and immediately after the procedure was 0.4 points on the numerical rating scale. This confirmed that the patients experienced almost no pain during monopolar RF treatment, which is notable because we did not apply a local anesthetic cream to the patients' skin before the procedure.

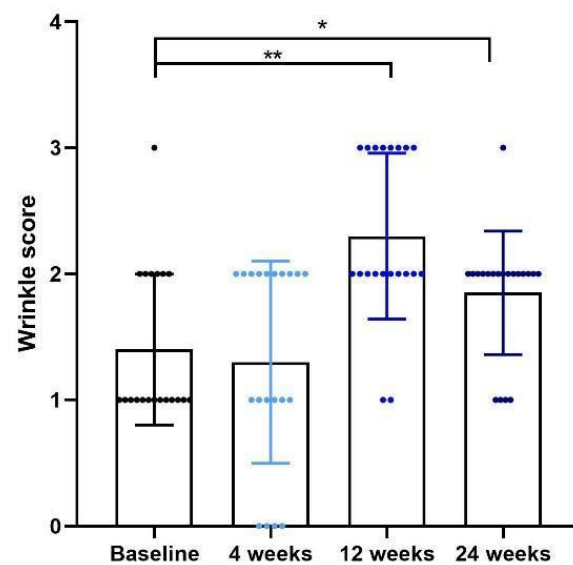


Figure 2. Clinical improvement using 6-point photonic scale. Dermatologists' assessments of the improvements statistically increased after 12 weeks of treatments and lasted 24 weeks. The mean values \pm SD are presented. The asterisk indicates a significant difference. * $p < 0.05$, ** $p < 0.01$. Dots mean the individual subjects. Different colors show the different follow up week.

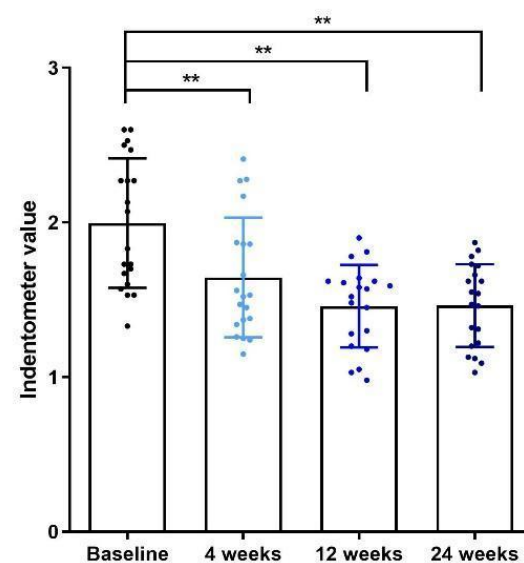


Figure 3. Skin firmness in patients after monopolar RF treatment. Skin firmness significantly increased after 4 weeks of treatment and continued to improve for 24 weeks. The mean values \pm SD are presented. The asterisk indicates a significant difference. ** $p < 0.01$.

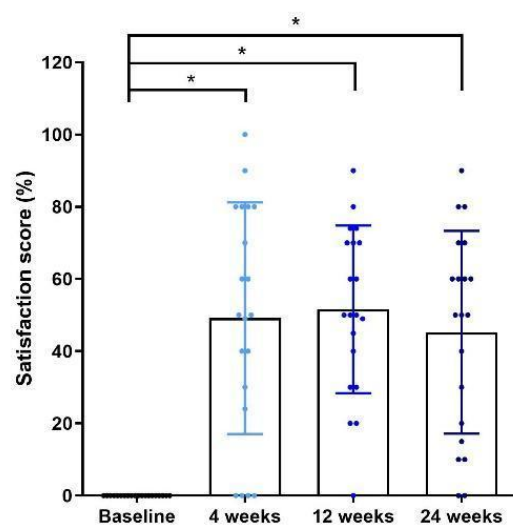


Figure 4. Patient self-assessment of improvement in middle and lower face laxity. Satisfaction significantly increased after 4 weeks of treatment and lasted 24 weeks. Mean values \pm SD are presented. Asterisk indicates significant difference. * $p < 0.05$.

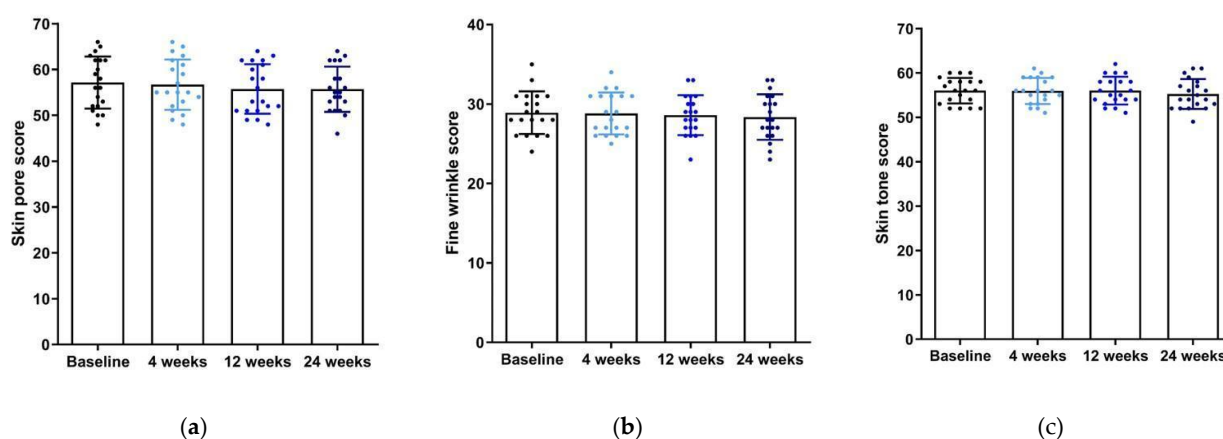


Figure 5. Assessment of skin pores, fine wrinkles, and skin tone with the facial aging measurement device. (a) Skin pores, (b) fine wrinkles, and (c) skin tone were analyzed using a facial aging measurement device (Mark-Vu[®], PSIPLUS, Republic of Korea). Mean values \pm SD are presented.

Table 2. Changes in skin pores, fine wrinkles, and skin tone score.

	Baseline Mean \pm SD	4 Weeks Mean \pm SD	12 Weeks Mean \pm SD	24 Weeks Mean \pm SD	<i>p</i> -Value
Skin pore score	57.15 \pm 5.67	56.70 \pm 5.52	55.75 \pm 5.41	55.70 \pm 4.95	$p = 0.80$
Fine wrinkle score	28.90 \pm 2.67	28.80 \pm 2.63	28.60 \pm 2.52	28.35 \pm 2.87	$p = 0.96$
Skin tone score	56.00 \pm 2.87	55.95 \pm 2.93	56.00 \pm 3.11	55.25 \pm 3.35	$p = 0.86$

SD; standard deviation.

4. Discussion

With the increase in the human lifespan, there has been a shift in the perception of aging. Rather than simply focusing on the prevention of aging, there is growing interest in embracing aging positively and maintaining healthy skin for more extended periods; this concept is known as “well aging” or “slow aging” [16]. Skin aging is broadly divided into intrinsic and extrinsic aging.

Intrinsic aging occurs due to chronological age changes, and typical changes include roughening of the skin surface, fine wrinkles, and subepidermal atrophy. On the other hand,

extrinsic aging is caused by various causes such as pollutants and heat, and photoaging caused by exposure to ultraviolet and infrared rays is a representative example, causing deeper and thicker wrinkles, pigment changes, and capillary dilation. This skin aging process does not occur at a constant rate in all people, and its progression varies according to anatomical location. As the signs of aging become increasingly apparent, there is a growing desire for cosmetic procedures and plastic surgery to maintain a youthful appearance. Additionally, there is a trend toward seeking lifestyle improvements, such as focusing on inner beauty through dietary changes and adopting healthier habits.

Invasive procedures such as facelifts and thread lifts were historically favored because of their dramatic effects in combating aging [17]. However, recent trends favor less-invasive procedures with minimal downtime [18]. High-intensity focused ultrasound and RF treatments align with these trends, offering individuals concerned about aging a convenient and quick solution with minimal disruption to their daily lives. These noninvasive procedures are gaining popularity because they provide options for skincare and contribute to the concept of slow aging.

Monopolar RF devices produce volumetric heat by utilizing a high-frequency electric current that passes through a transducer and then returns to a grounding pad on the patient's body [1]. This heat penetrates deep into the dermis, fat layers, fibrous septae, and fascia, leading to skin tightening that lasts approximately 4–6 months [6,19]. The middle and lower facial areas may exhibit more immediate responses to RF treatment because of their higher concentration of subcutaneous fat [20,21]. Some studies reported side effects during monopolar RF treatment, such as pain and burning during treatment, which tend to be more frequent because of the deep penetration depth. Less frequent adverse reactions are erythema, headache, scarring, edema, fat atrophy, and facial palsy.

The Oligio monopolar RF system creates a rapidly alternating electromagnetic field at a rate of 6 million times per second during treatment, stimulating the movement of charged particles and generating currents within tissues. These currents induce localized heating (40 °C–60 °C) within collagen-based structures, such as the dermal collagen scaffold and fibrous septae, resulting in deep-tissue heating. To prevent surface burns, contact cooling is implemented using a cryogen spray on the inner surface of the treatment tip before, during, and after each energy pulse [22]. The deep tissue heating produced by monopolar RF immediately triggers collagen contraction and denaturation, which is followed by a natural healing process over an extended period. This process leads to dermal remodeling and new collagen formation, ultimately inducing skin-tightening effects [23].

Monopolar RF technology has been available for a long period of time, and most studies to date have evaluated its clinical efficacy by reviewing photographs. Few studies have utilized skin measurement devices for long-term observations after RF monopolar treatment. In the present study, we used an indentometer to measure cheek skin firmness and observed initial improvement at 4 weeks after treatment, followed by continued and consistent improvement for up to 24 weeks. The independent experts' assessments of skin tightening and lifting efficacy after a single treatment session revealed moderate improvement at week 12, and this improvement was sustained up to week 24. We hypothesized that the slight time difference between the indentometer's results and the experts' visual evaluation results was caused by the fact that skin firmness begins to improve before any visible improvement becomes apparent. Similar to the indentometer results, patient satisfaction, as assessed through questionnaires, demonstrated moderate improvement at weeks 4, 12, and 24 after treatment compared with baseline. This improvement corresponded with the indentometer results and was more rapid than that assessed by the evaluators. As the patients touched and felt their faces every time they washed or applied moisturizer, they would have been able to see that their skin was gaining elasticity more rapidly than indicated by an expert's visual evaluation.

Interestingly, all patients in our study showed immediate improvement in facial skin firmness after the treatment compared with baseline. One possible explanation for these findings is the immediate denaturation of collagen, resulting in fibril contraction and tissue

thickening [24]. Another potential mechanism for the visible contour improvements is the conduction of monopolar RF energy to collagen-based fibrous septae. Approximately 10–30% of subcutaneous tissue comprises collagen-based fibrous septae, which form a connective tissue network between fat lobules [16].

The facial aging measurement device showed no statistically significant improvement in skin pores, fine wrinkles, or skin tone from baseline. We initially hypothesized that monopolar RF induced reductions in pore sizes and fine wrinkles. This led us to investigate the potential effect of multiple monopolar RF treatments because previous research showed that two RF treatments yielded significantly more significant improvement in facial skin laxity than a single treatment [24,25]. Moreover, a recent study suggested decreased pore volume after monopolar RF treatment. The main differences between that study and our previous study were the number of treatment sessions and the characteristics of the participants. Our previous study included 10 women and 9 men with an average pore diameter of >0.3 mm on the cheeks, and the patients underwent two monopolar RF treatment sessions at a 4-week interval [26]. A single monopolar RF treatment did not have a pore-reducing effect in patients with general aging compared with patients who had large pores. In the future, we plan to examine how often and at what intervals monopolar RF treatment can be used to observe a pore-reducing effect in patients with general facial skin aging.

The 10,600 nm CO₂ and 2940 nm Erbium lasers were the first ones to be used for rejuvenation. In recent years, several anti-aging tools and devices have been introduced, such as fractional picosecond lasers, 1440 nm lasers, fractional CO₂ lasers, and 675 nm lasers. Picosecond fractional lasers create small wounds, presumably by laser-induced optical breakdown, and improve both facial wrinkles and pigmentation [27]. The combination of multiple devices may be synergistic. There is a split-facial trial using a combination of intense pulse light (IPL) and a 1440 nm diode laser. As expected, the combination of IPL and a 1440 nm diode laser showed more improvement than either IPL or 1440 nm alone. As the skin aging process induces pigmentation and wrinkles, the combination of multiple devices may be effective and result in higher subject satisfaction [28]. The fractionated CO₂ laser has long been considered the gold standard for facial skin rejuvenation. Whole-face resurfacing can be effective in aged skin. However, in darker skin types, dermatologists should carefully monitor the treatment endpoint and post-treatment wound care. Post-inflammatory hyperpigmentation is a common complication following laser resurfacing [29]. One of the most significant advances in procedural dermatology over the past decade has been non-ablative laser resurfacing, which has replaced other treatments for a variety of aesthetic purposes. Ablative lasers have raised safety concerns in patients with dark skin types, such as scars, hyperpigmentation, and infections. As a result, non-ablative laser fields are emerging, although they are reserved for patients with mild to moderate skin aging. A new technology that emits a 675 nm wavelength of red light has been shown to be effective for scars, pigmentation, and wrinkles [30]. There are several limitations to this study. First, we only enrolled a small number of female subjects. The results might be more significant if we examined more subjects to evaluate the efficacy of RF treatment. Second, it would have been better if we compared the efficacy of RF treatment in a split face with the other anti-aging tools mentioned above. In future studies, we need to conduct studies that enroll more subjects and compare multiple anti-aging tools that can provide dermatologists with objective results.

One novel aspect of the present study is the assessment of pain during the procedure; the participants did not apply topical anesthetics before the treatment. As mentioned above, the most frequent side effects during monopolar RF treatment are pain and burning during treatment, and the less frequent adverse reactions are erythema, headache, scarring, edema, fat atrophy, and facial palsy. These adverse events are because of the deep penetration depth of RF. To reduce pain during the treatment, a topical anesthetic (mixture of 2.5% lidocaine and 2.5% prilocaine cream) was applied before the procedure in most studies [31,32]. When the patients use the topical anesthetic cream before the procedure, it is hard for the

practitioners to obtain the patient's feedback on whether the energy is painful or high. Therefore, it is easier for the patients to have unwanted skin burns or facial palsy after the monopolar RF treatment. Despite the lack of pretreatment for local anesthesia, the average pain score was only 0.4 points, indicating mild or no pain. Even with this minimal degree of pain, clinical efficacy remained unaffected. Without using topical anesthesia, practitioners can easily obtain patient feedback, and energy can be raised or lowered depending on the patient's reaction. Moreover, without topical anesthetic cream, patients can avoid allergic contact dermatitis, which is induced by topical amide anesthetics such as lidocaine. This suggests that high-frequency (RF) treatment may be a suitable option for patients who desire its benefits but are hesitant because of concerns about pain.

In line with the trends of well aging and slow aging, in which individuals seek natural beauty appropriate for their age and aim to achieve healthy aging, the monopolar RF device has the potential to expand the range of available cosmetic procedures. It may offer choices for those wishing to widen their options for gracefully maintaining natural beauty and facial skin elasticity.

Author Contributions: Conceptualization, Y.L., H.K. and Y.-J.S.; methodology, D.H. and Y.S.; validation, S.J. and C.-L.H.; data curation, Y.L. and J.S.; writing, Y.L., J.S., Y.S. and H.K.; visualization, D.H., K.E.J. and Y.-J.S. All authors have read and agreed to the published version of the manuscript.

Funding: This research received no external funding.

Institutional Review Board Statement: This study was conducted in accordance with the Declaration of Helsinki and later amendments. The study was approved by the Institutional Review Board of Chungnam National University Hospital (CNUH 2021-10-012).

Informed Consent Statement: Written informed consent has been obtained from the patient(s) to publish this paper.

Data Availability Statement: Data are available upon reasonable request.

Conflicts of Interest: The authors declare no conflicts of interest.

References

1. Beasley, K.L.; Weiss, R.A. Radiofrequency in cosmetic dermatology. *Dermatol. Clin.* **2014**, *32*, 79–90. [[CrossRef](#)] [[PubMed](#)]
2. Alster, T.S.; Lupton, J.R. Nonablative cutaneous remodeling using radiofrequency devices. *Clin. Dermatol.* **2007**, *25*, 487–491. [[CrossRef](#)] [[PubMed](#)]
3. Elsaie, M.L. Cutaneous remodeling and photorejuvenation using radiofrequency devices. *Indian J. Dermatol.* **2009**, *54*, 201–205. [[CrossRef](#)] [[PubMed](#)]
4. Tan, M.G.; Jo, C.E.; Chapas, A.; Khetarpal, S.; Dover, J.S. Radiofrequency Microneedling: A Comprehensive and Critical Review. *Dermatol. Surg.* **2021**, *47*, 755–761. [[CrossRef](#)] [[PubMed](#)]
5. Arnoczky, S.P.; Aksan, A. Thermal modification of connective tissues: Basic science considerations and clinical implications. *Instr. Course Lect.* **2001**, *50*, 3–11. [[CrossRef](#)] [[PubMed](#)]
6. Dierickx, C.C. The role of deep heating for noninvasive skin rejuvenation. *Lasers Surg. Med.* **2006**, *38*, 799–807. [[CrossRef](#)] [[PubMed](#)]
7. Angra, K.; Alhaddad, M.; Boen, M.; Lipp, M.B.; Kollipara, R.; Hoss, E.; Goldman, M.P. Prospective Clinical Trial of the Latest Generation of Noninvasive Monopolar Radiofrequency for the Treatment of Facial and Upper Neck Skin Laxity. *Dermatol. Surg.* **2021**, *47*, 762–766. [[CrossRef](#)] [[PubMed](#)]
8. Lee, J.; Jeong, E.T.; Lim, J.; Park, S.G. Development of the facial glycation imaging system for in situ human face skin glycation index measurement. *J. Cosmet. Dermatol.* **2021**, *20*, 2963–2968. [[CrossRef](#)] [[PubMed](#)]
9. Park, H.U.; Cho, H.; Lee, S.J.; Cho, H.K. Use of 1,064-nm Q-switched Neodymium:Yttrium-aluminum-garnet Laser Therapy Assisted with Diamond Particle Suspension and Gold Microparticle Application for Acne Vulgaris and Enlarged Facial Pores. *Med. Lasers* **2021**, *10*, 242–245. [[CrossRef](#)]
10. Carruthers, A.; Carruthers, J. A validated facial grading scale: The future of facial ageing measurement tools? *J. Cosmet. Laser Ther.* **2010**, *12*, 235–241. [[CrossRef](#)]
11. Carruthers, J.; Flynn, T.C.; Geister, T.L.; Gortelmeyer, R.; Hardas, B.; Himmrich, S.; Jones, D.; Kerscher, M.; Maio, M.; Mohrmann, C.; et al. Validated assessment scales for the mid face. *Dermatol. Surg.* **2012**, *38*, 320–332. [[CrossRef](#)] [[PubMed](#)]
12. Narins, R.S.; Carruthers, J.; Flynn, T.C.; Geister, T.L.; Gortelmeyer, R.; Hardas, B.; Himmrich, S.; Jones, D.; Kerscher, M.; Maio, M.; et al. Validated assessment scales for the lower face. *Dermatol. Surg.* **2012**, *38*, 333–342. [[CrossRef](#)] [[PubMed](#)]

13. Chauny, J.M.; Paquet, J.; Lavigne, G.; Marquis, M.; Daoust, R. Evaluating acute pain intensity relief: Challenges when using an 11-point numerical rating scale. *Pain* **2016**, *157*, 355–360. [[CrossRef](#)] [[PubMed](#)]
14. Uehata, Y.; Yoshida, M.; Yabunaka, K.; Minematsu, T.; Tamai, N.; Sugama, J.; Sanada, H. Relationship of skin hardness of the temporal region to nutritional status. *J. Nurs. Sci. Eng.* **2017**, *4*, 49–57.
15. Ivanova, Z.; Aleksiev, T.; Dobrev, H.; Atanasov, N. Use of a novel indentometer to evaluate skin stiffness in healthy and diseased human skin. *Skin Res. Technol.* **2023**, *29*, e13384. [[CrossRef](#)] [[PubMed](#)]
16. Wanitphakdeedecha, R.; Yogya, Y.; Yan, C.; Phumariyapong, P.; Nanchaipruek, Y.; Thongjaroensirikul, P.; Maneeprasopchoke, P.; Techapichetvanich, T.; Eimpunth, S.; Manuskiatti, W. Efficacy and Safety of Monopolar Radiofrequency for Treatment of Lower Facial Laxity in Asians. *Dermatol. Ther.* **2022**, *12*, 2563–2573. [[CrossRef](#)] [[PubMed](#)]
17. Rabe, J.H.; Mamelak, A.J.; McElgunn, P.J.S.; Morison, W.L.; Sauder, D.N. Photoaging: Mechanisms and repair. *J. Am. Acad. Dermatol.* **2006**, *55*, 1–19. [[CrossRef](#)] [[PubMed](#)]
18. Lee, C.; Gold, M.H. Updates on radiofrequency devices for skin tightening and body contouring. *Dermatol. Rev.* **2020**, *1*, 75–83. [[CrossRef](#)]
19. Schoellhammer, C.M.; Blankschtein, D.; Langer, R. Skin permeabilization for transdermal drug delivery: Recent advances and future prospects. *Exp. Opin. Drug Deliv.* **2014**, *11*, 393–407. [[CrossRef](#)]
20. Alster, T.S.; Tanzi, E. Improvement of neck and cheek laxity with a nonablative radiofrequency device: A lifting experience. *Dermatol. Surg.* **2004**, *30*, 503–507. [[CrossRef](#)]
21. Bogle, M.A.; Uebelhoefer, N.; Weiss, R.A.; Mayoral, F.; Kaminer, M.S. Evaluation of the multiple pass, low fluence algorithm for radiofrequency tightening of the lower face. *Lasers Surg. Med.* **2007**, *39*, 210–217. [[CrossRef](#)] [[PubMed](#)]
22. Abraham, M.T.; Mashkevich, G. Monopolar radiofrequency skin tightening. *Fac. Plast. Surg. Clin. N. Am.* **2007**, *15*, 169–177. [[CrossRef](#)]
23. Zelickson, B.D.; Kist, D.; Bernstein, E.; Brown, D.B.; Ksenzenko, S.; Burns, J.; Kilmer, S.; Mehregan, D.; Pope, K. Histological and ultrastructural evaluation of the effects of a radiofrequency-based nonablative dermal remodeling device: A pilot study. *Arch. Dermatol.* **2004**, *140*, 204–209. [[CrossRef](#)]
24. Fritz, M.; Counters, J.T.; Zelickson, B.D. Radiofrequency treatment for middle and lower face laxity. *Arch. Fac. Plast. Surg.* **2004**, *6*, 370–373. [[CrossRef](#)]
25. Suh, D.H.; Lee, S.J.; Ryou, J.H.; Son, H.C.; Kim, H.J.; Kim, H.S. Monopolar radiofrequency treatment in Asian skin: Do multiple RF treatments over time have beneficial effects? An observational report with long-term follow-up in eight patients. *Dermatol. Surg.* **2013**, *39*, 670–672. [[CrossRef](#)] [[PubMed](#)]
26. Techapichetvanich, T.; Manuskiatti, W.; Wongdama, S.; Viriyaskultorn, N.; Li, J.B.; Jantanapornchai, N. Nonablative monopolar radiofrequency for the reduction of facial pores and sebum excretion in Thai patients: A novel approach. *Lasers Surg. Med.* **2023**, *55*, 528–535. [[CrossRef](#)] [[PubMed](#)]
27. Ross, E.V.; Tidwell, W.J.; Guss, L.; Sutton, A.V. Study of a 532/1064 fractional picosecond laser for facial rejuvenation. *Dermatol. Surg.* **2022**, *48*, 109–113. [[CrossRef](#)]
28. Almukhtar, R.M.; Wood, E.S.; Fabi, S.G. Efficacy and safety of intense pulsed light and nonablative fractional 1440-nm diode laser to a combination of the 2 modalities for facial rejuvenation. *Dermatol. Surg.* **2023**, *49*, 42–47. [[CrossRef](#)] [[PubMed](#)]
29. Ziai, K.; Wright, H.V. Carbon dioxide laser rejuvenation of the facial skin. *Clin. Plast. Surg.* **2023**, *50*, 421–436. [[CrossRef](#)]
30. Tolone, M.; Bennardo, L.; Zappia, E.; Scali, E.; Nisticò, S.P. New insight into nonablative 675-nm laser technology: Current applications and future perspectives. *Dermatol. Clin.* **2024**, *42*, 45–50. [[CrossRef](#)]
31. Kushikata, N.; Negishi, K.; Tezuka, Y.; Takeuchi, K.; Wakamatsu, S. Is topical anesthesia useful in noninvasive skin tightening using radiofrequency? *Dermatol. Surg.* **2005**, *31*, 526–533. [[CrossRef](#)] [[PubMed](#)]
32. Sachdev, M.; Hameed, S.; Mysore, V. Nonablative lasers and nonlaser systems in dermatology: Current status. *Indian J. Dermatol. Venereol. Leprol.* **2011**, *77*, 380–388. [[CrossRef](#)] [[PubMed](#)]

Disclaimer/Publisher’s Note: The statements, opinions and data contained in all publications are solely those of the individual author(s) and contributor(s) and not of MDPI and/or the editor(s). MDPI and/or the editor(s) disclaim responsibility for any injury to people or property resulting from any ideas, methods, instructions or products referred to in the content.