

Supplementary Materials: MAL Daylight Photodynamic Therapy for Actinic Keratosis: Clinical and Imaging Evaluation by 3D Camera

Carmen Cantisani, Giovanni Paolino, Giovanni Pellacani, Dario Didona, Marco Scarno, Valentina Faina, Tommaso Gobello and Stefano Calvieri

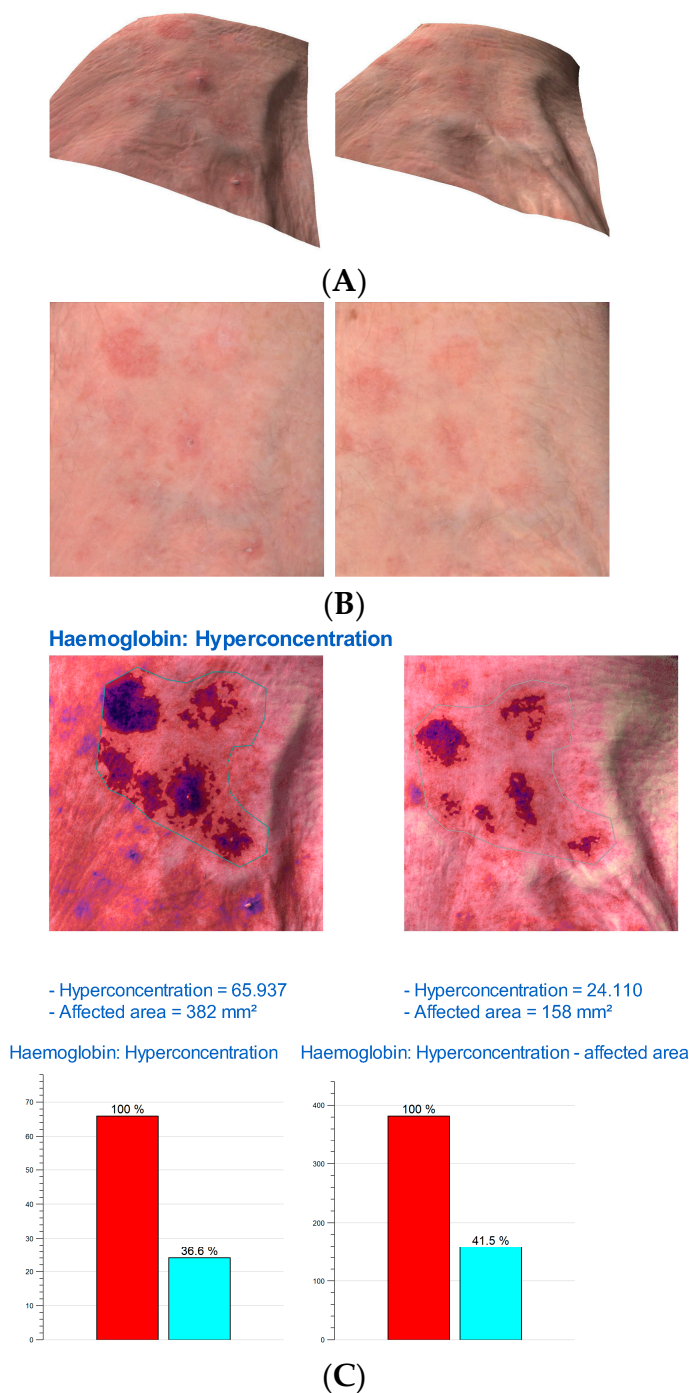


Figure S1. Cont.

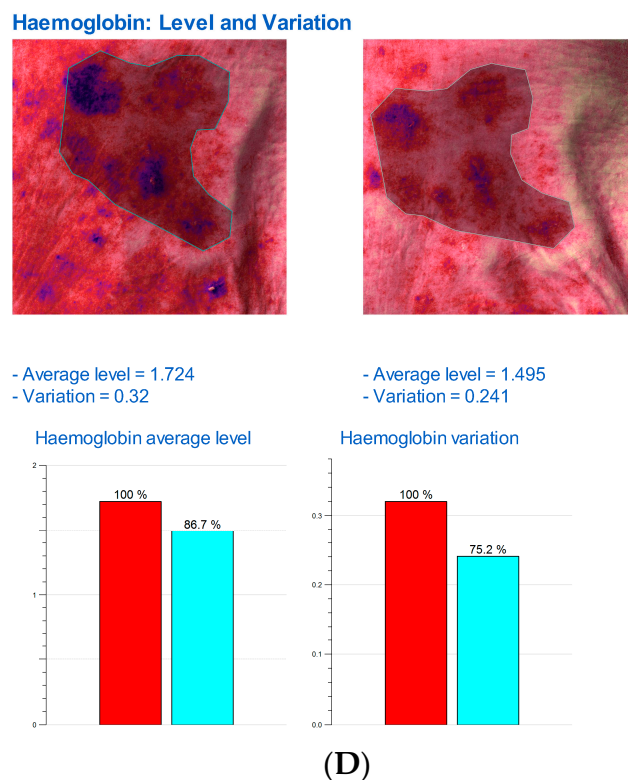


Figure S1. (A) Multiple actinic keratoses highlighted by Antera 3D, Miravex; (B) A particular of the same actinic keratoses; (C) Hemoglobin concentration in the affected area and variation of hemoglobin before and after one treatment. The **left** figures are before the treatment, while the **right** figures are after the treatment. In the graphs there is represented the variation of hemoglobin before (red column) and after one treatment (blue column); (D) Hemoglobin concentration in the affected area and variation of hemoglobin before and after one treatment. The **left** figures are before the treatment, while the **right** figures are after the treatment. In the graphs there is represented the variation of hemoglobin before (red column) and after one treatment (blue column).