

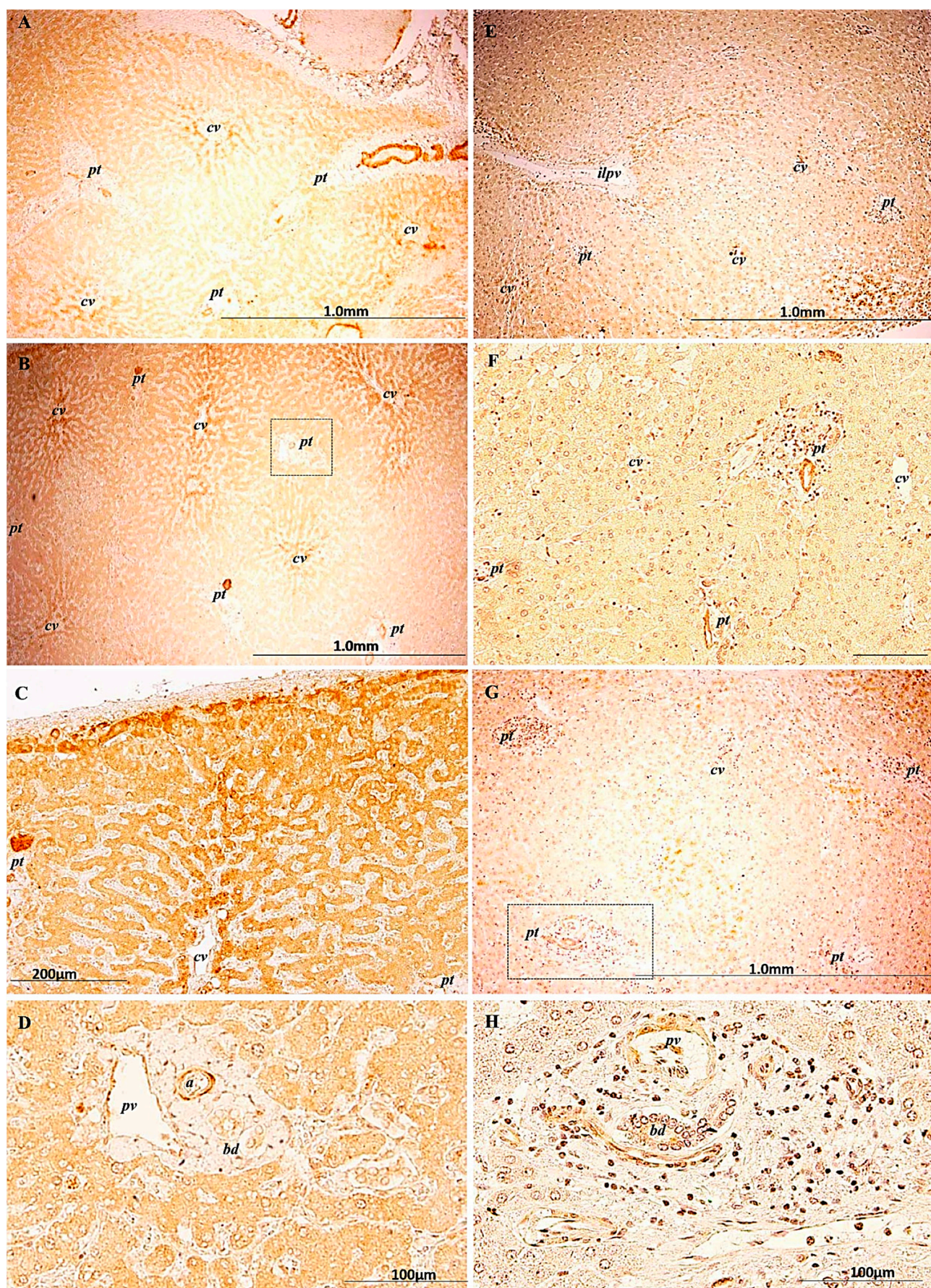Figure S1. Immunohistochemical characterization of AMOTL2 expression in healthy (A-D) and CRC metastasized liver (E-H). In healthy liver tissue sections a positive AMOTL2 cytoplasmic expression gradient is observed in hepatocytes, with

higher grades of expression in peri-venous hepatocytes (A-C). This grading of staining disappears in apparently healthy areas of metastasized liver samples (E-G). (D) and (H) are higher magnifications of the insets in B and G respectively, showing the presence of numerous inflammatory AmotL2⁺ cells in the connective tissue that surrounds portal tracts of metastasized CRC liver tissue samples (H), not observed in healthy liver (D). *pt*=portal tract *cv*=central vein *ilpv*=inter lobular portal vein *a*=artery *bd*=bile duct *M*=metastasis

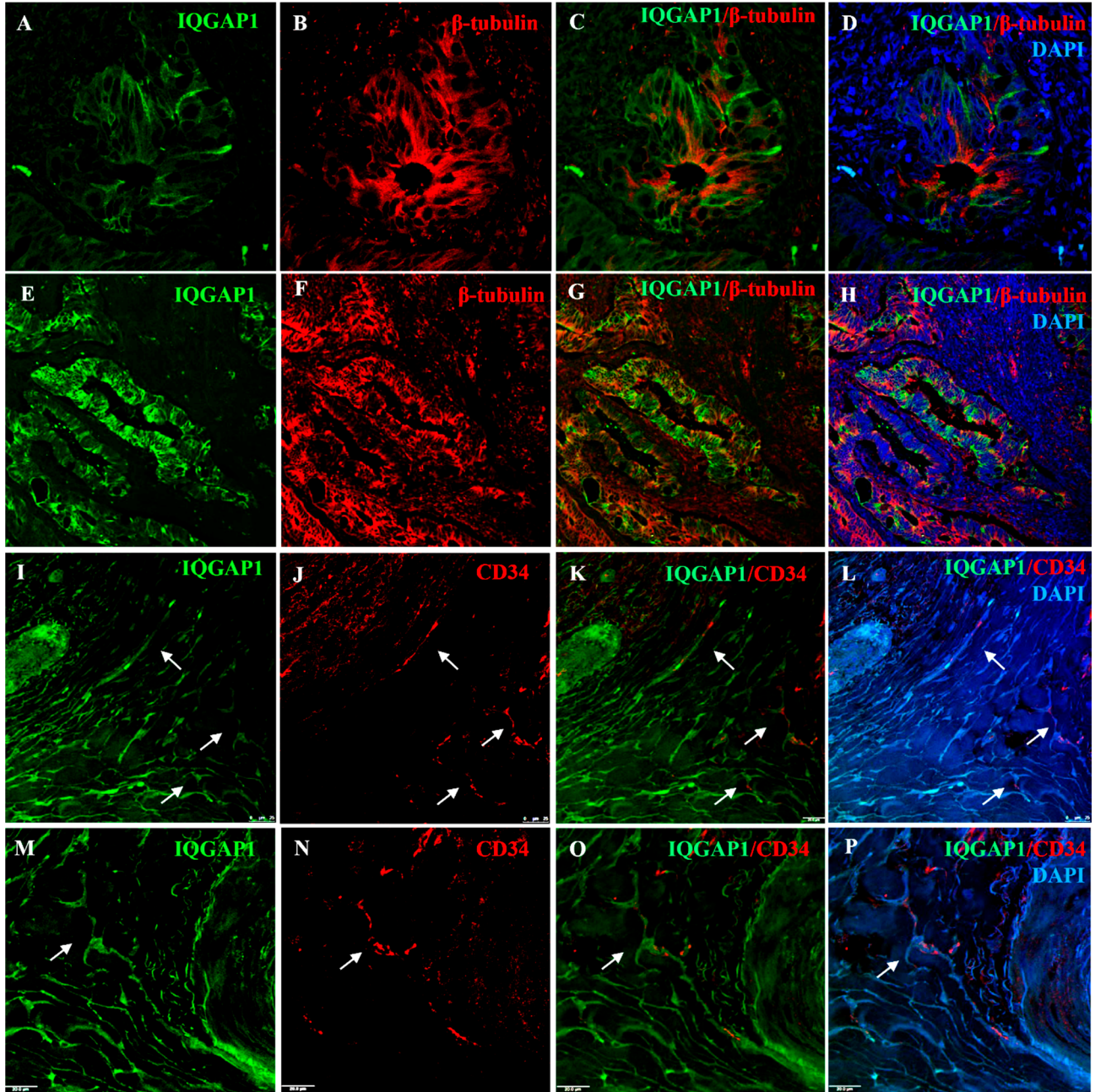


Figure S2. (A–H) Double immunolocalization of IQGAP1 (green) and β-tubulin (red) in CRC tissue samples. (I–L) Double immunolocalization of IQGAP1 (green) and CD34 (red) in CRC tissue samples. Arrows point to IQGAP1⁺/CD34⁺ telocytes. (M–N) Higher magnification of panels I–L to appreciate the peculiar morphology of telocytes (arrow).