

Supplementary Material

Figure S1: The HE staining of tissues in the sham and CLP groups at 10 days. (A) The lung tissues of the CLP group exhibited a significant infiltration of lymphocytes and neutrophils, (B) Hepatocellular degeneration surrounding liver blood vessels is observed in multiple areas, (C) Minor venous congestion and dilation were observed in kidney.

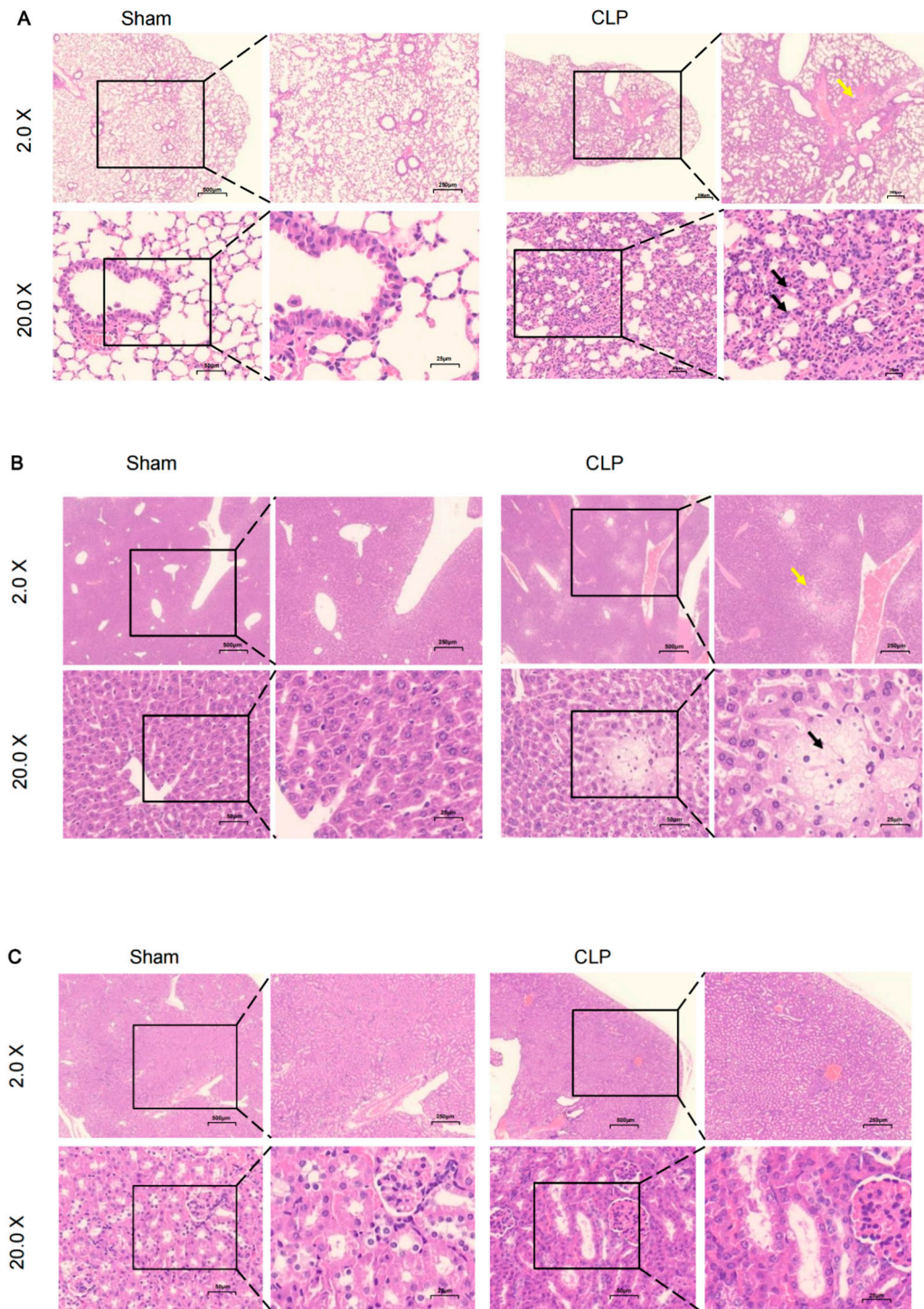


Figure S2: The heat map of top ten up-regulated and down-regulated genes, respectively.

