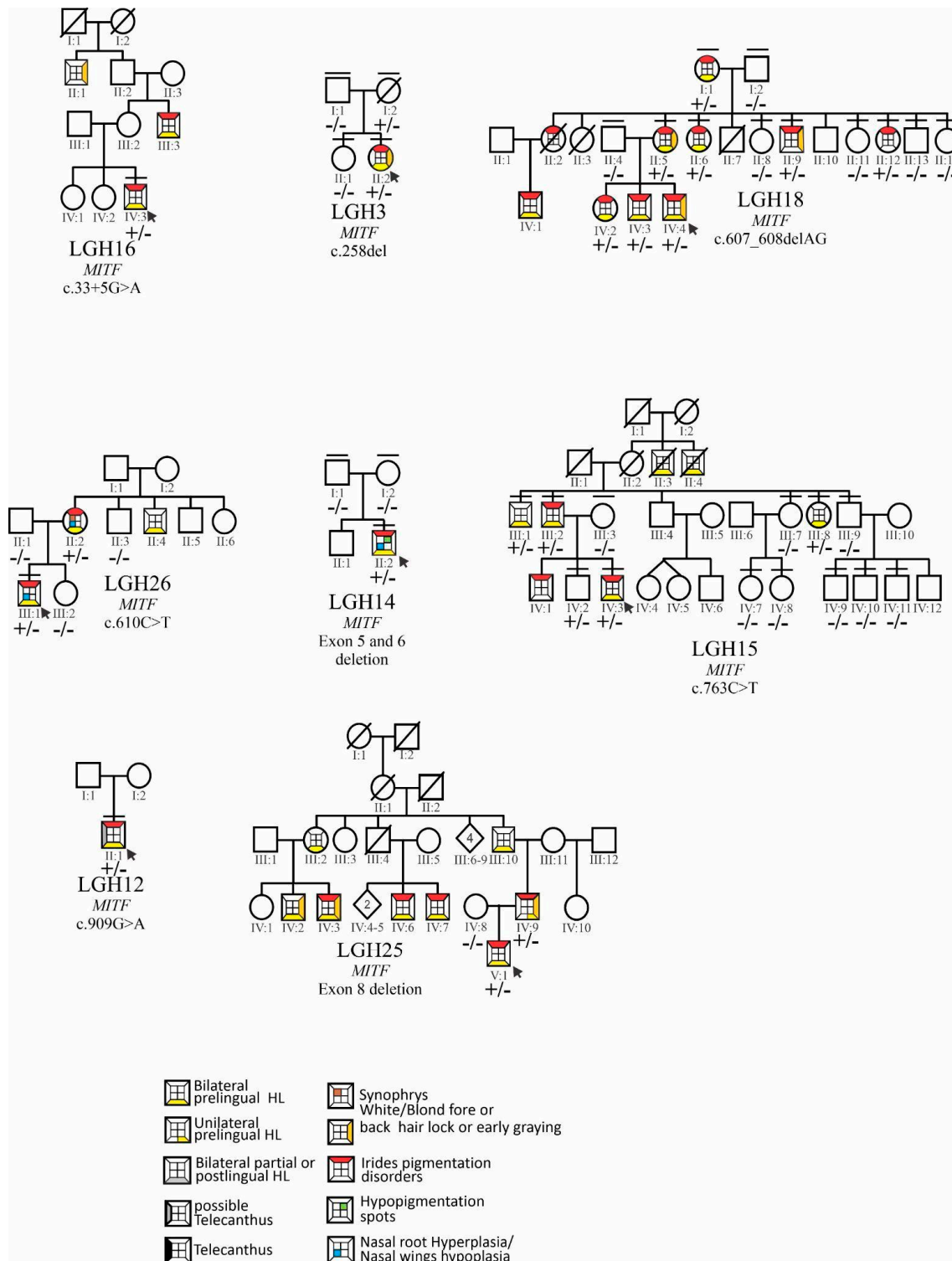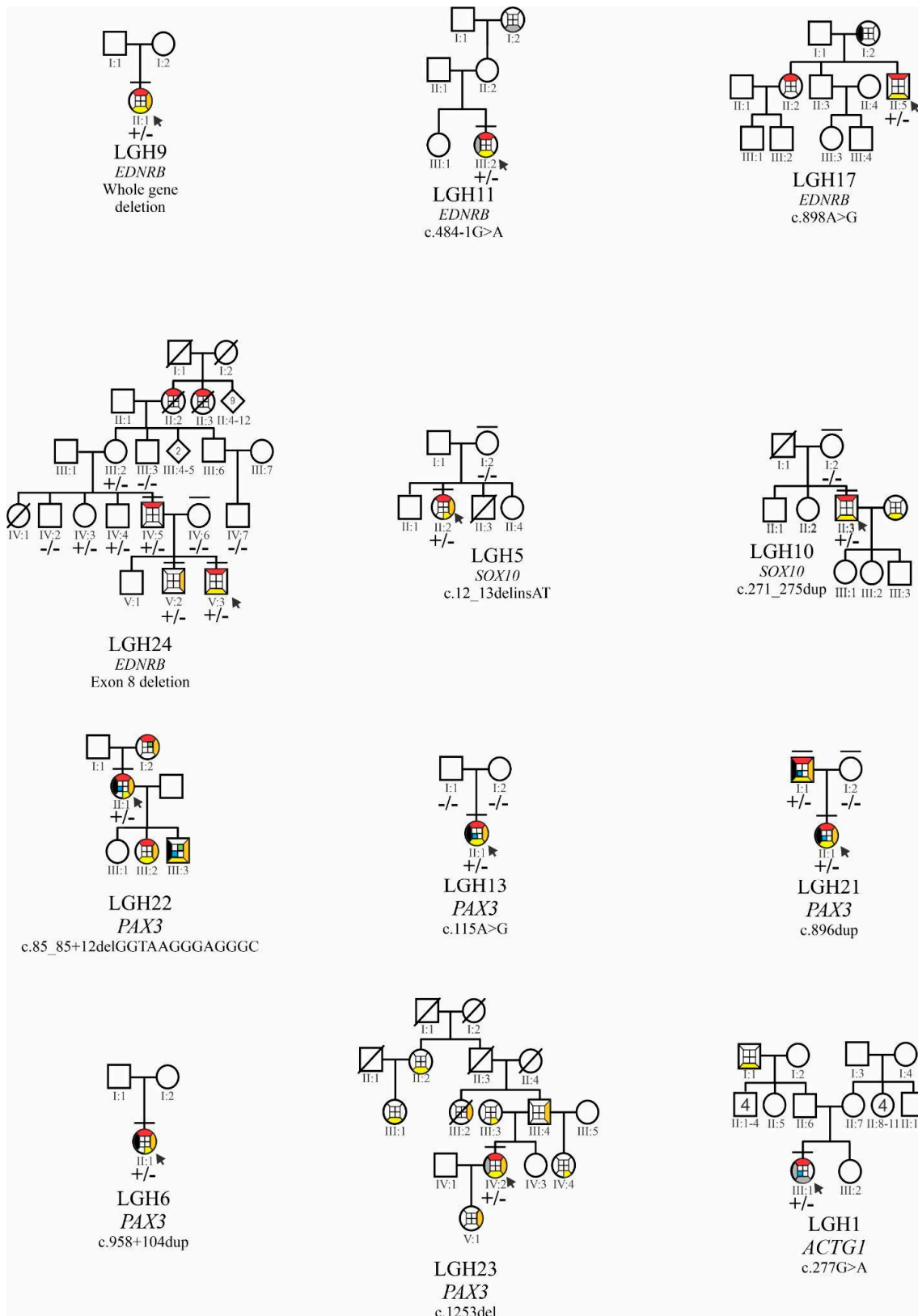


Figure S1: Pedigrees of the cases with the clinical characterization and the segregation of the variants



Continuation of Figure S1

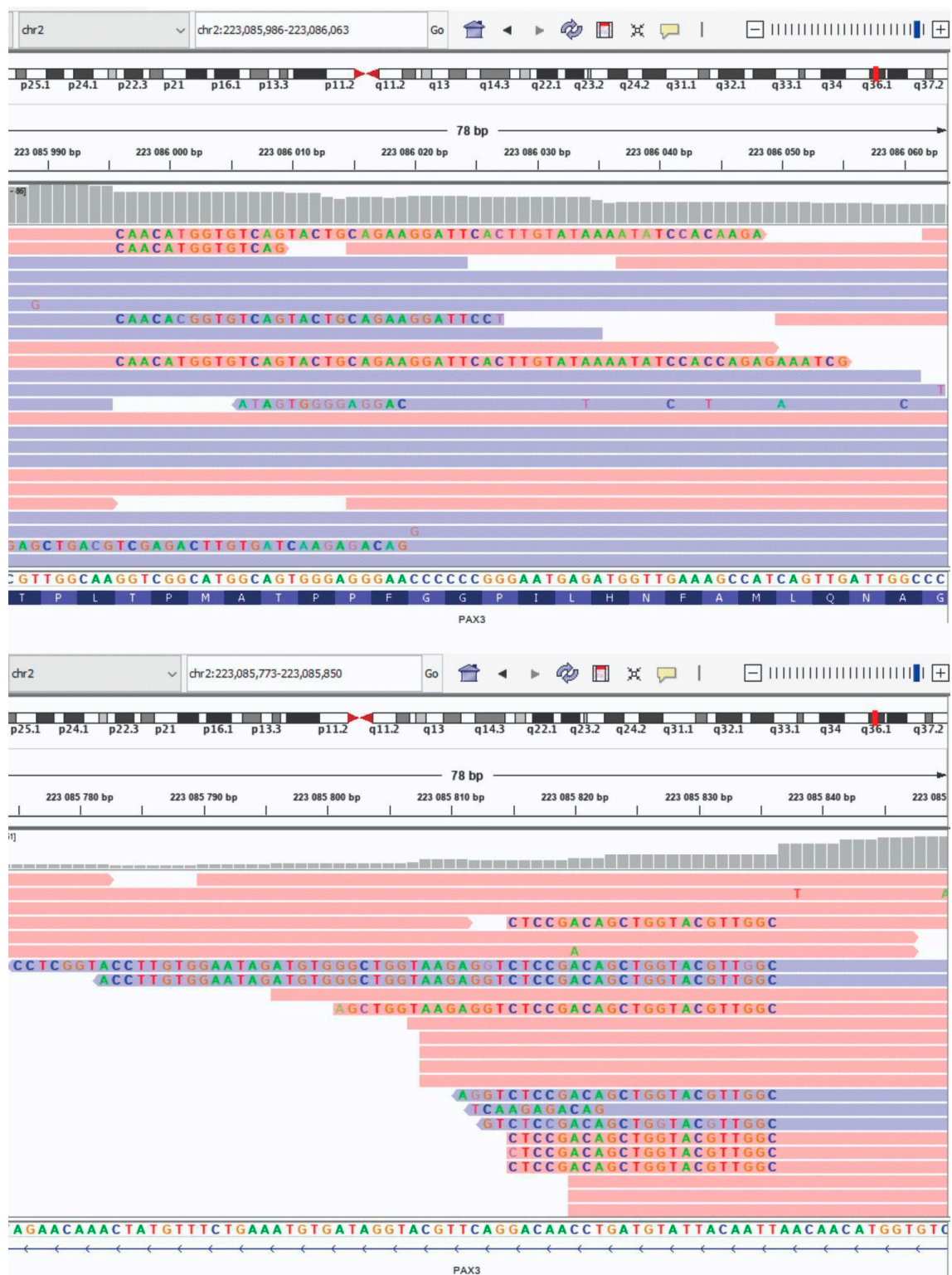


Figure S2: Visualization in IGV of the misaligned soft-clipped reads of proband LGH6.