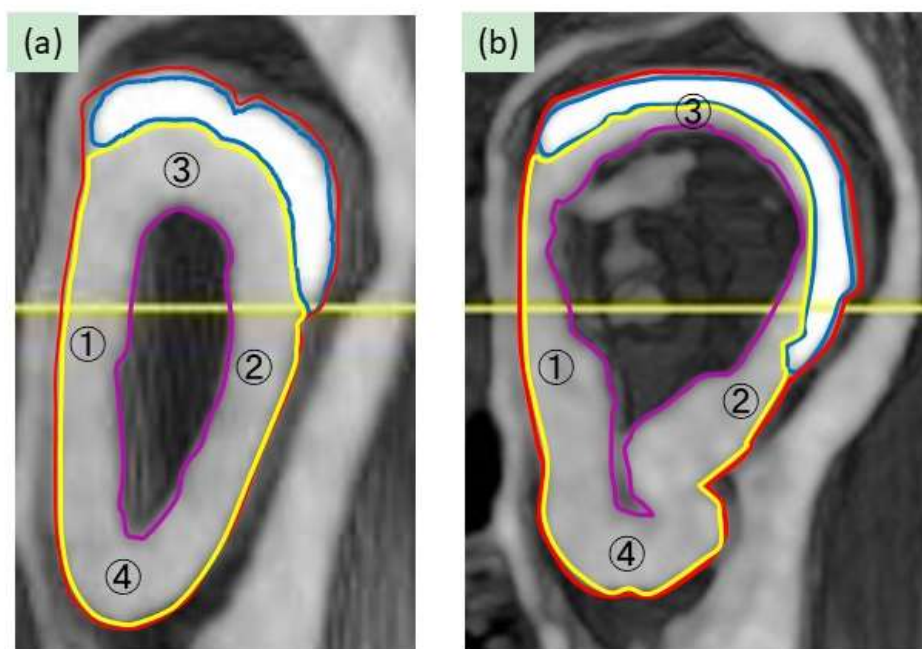


Spontaneous Development of Dental Dysplasia in Aged *Parp-1* Knockout Mice



Supplemental Figure 1. Definition of areas of tooth elements. Representative CT images of incisors of aged *Parp-1*^{+/+} (a) and *Parp-1*^{-/-} mice (b). The areas of enamel, dentin, pulp and the whole of the tooth were defined as encircled with blue, yellow, purple and red lines, respectively. The calcification level of dentin was defined as average of four points; ① medial, ② distal, ③ labial, and ④ palatal points of dentin.