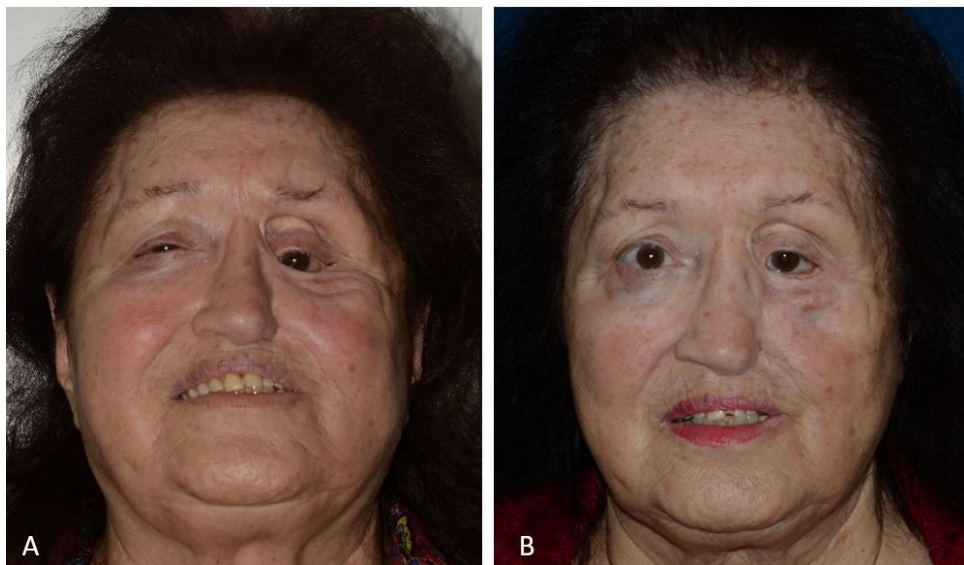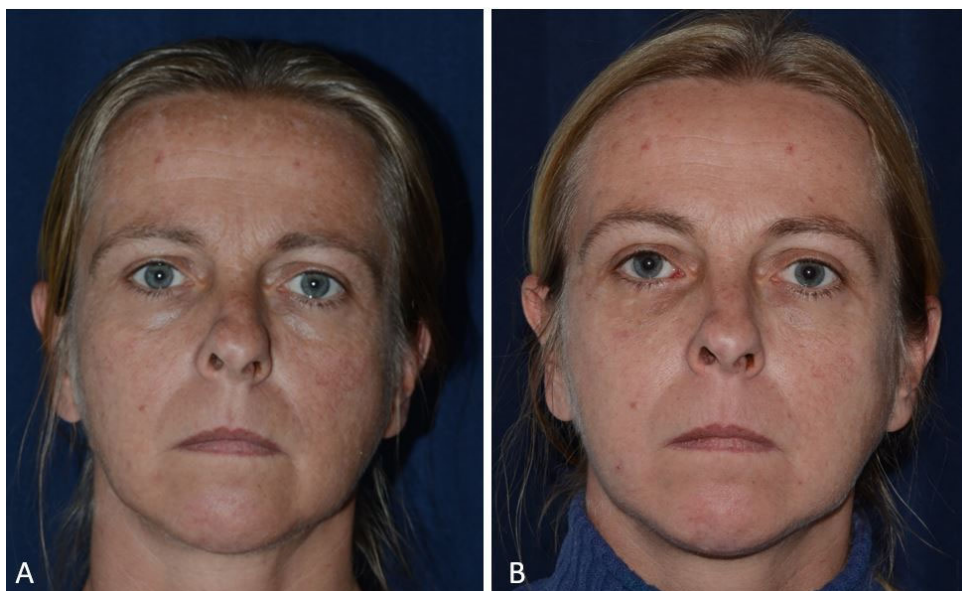




*Figure 1: A) a lady with left eyeball dystopia and enophthalmos due to a previous craniofacial oncological resection. She had both vertical diplopia and in primary position. B) After orbital reconstruction, she obtained a good both resolution of eyeball dystopia and diplopia.*



**Figure 2:** A) a lady affected by post-traumatic enophthalmos without diplopia. B) She had a floor of the orbit reconstruction, obtaining a correct eyeball repositioning, maintaining the correct muscular function.

**Commented [M1]:** Figures should be in numerical order, we revised Figure 3 to Figure 2, please confirm.