



Review

Clinical Findings of *Listeria monocytogenes* Infections with a Special Focus on Bone Localizations

Marco Bongiovanni ^{1,*}, Claudio Cavallo ², Beatrice Barda ¹, Lukasz Strulak ², Enos Bernasconi ¹ and Andrea Cardia ²

¹ Division of Infectious Diseases, Ente Ospedaliero Cantonale, 6900 Lugano, Switzerland; beatrice.barda@eoc.ch (B.B.); enos.bernasconi@eoc.ch (E.B.)

² Division of Neurosurgery, Ente Ospedaliero Cantonale, 6900 Lugano, Switzerland; claudio.cavallo@eoc.ch (C.C.); lukasz.strulak@eoc.ch (L.S.)

* Correspondence: marco.bongiovanni@eoc.ch; Tel.: +41-0918-117-145

Abstract: *Listeria monocytogenes* is a Gram-positive pathogenic bacterium which can be found in soil or water. Infection with the microorganism can occur after ingestion of contaminated food products. Small and large outbreaks of listeriosis have been described in the past. *L. monocytogenes* can cause a number of different clinical syndromes, most frequently sepsis, meningitis, and rhombencephalitis, particularly in immunocompromised hosts. *L. monocytogenes* systemic infections can develop following tissue penetration across the gastrointestinal tract or to hematogenous spread to sterile sites, possibly evolving towards bacteremia. *L. monocytogenes* only rarely causes bone or joint infections, usually in the context of prosthetic material that can provide a site for bacterial seeding. We describe here the clinical findings of invasive listeriosis, mainly focusing on the diagnosis, clinical management, and treatment of bone and vertebral infections occurring in the context of invasive listeriosis.

Keywords: *Listeria monocytogenes*; bone infections; spondylodiscitis



Citation: Bongiovanni, M.; Cavallo, C.; Barda, B.; Strulak, L.; Bernasconi, E.; Cardia, A. Clinical Findings of *Listeria monocytogenes* Infections with a Special Focus on Bone Localizations. *Microorganisms* **2024**, *12*, 178. <https://doi.org/10.3390/microorganisms12010178>

Academic Editor: Piotr B. Heczko

Received: 12 December 2023

Revised: 5 January 2024

Accepted: 15 January 2024

Published: 16 January 2024



Copyright: © 2024 by the authors. Licensee MDPI, Basel, Switzerland. This article is an open access article distributed under the terms and conditions of the Creative Commons Attribution (CC BY) license (<https://creativecommons.org/licenses/by/4.0/>).

1. Introduction

Listeria monocytogenes is a Gram-positive, motile, facultative, anaerobe bacteria that inhabits a broad ecologic niche [1,2]. The microorganism can be isolated from soil, water, and vegetation, including raw vegetables intended for human consumption without further processing [3,4]. Newer chromogenic media may offer advantages in the detection of contaminated food [5,6]. The surface contamination of meat and vegetables is common, with up to 15% of these foods harboring the microorganism. Furthermore, *L. monocytogenes* is a transient inhabitant of both animal and human gastrointestinal tracts; intermittent carriage suggests possible frequent exposure [7,8]. Usually, the gut is the source for microorganisms in case of invasive listeriosis; the virulence factor ActA is associated with carriage development [9]. The microorganism has a competitive advantage against other Gram-positive and Gram-negative bacteria in cold environments, such as refrigerators; it is also amplified in spoiled food products, possibly leading to increased alkalinity. Feeding of spoiled silage with a high pH has resulted in epidemics of listeriosis in sheep and cattle [10]. Several foodborne outbreaks of listeriosis have been the result of animal epidemics; the first one occurred in Canada and was associated with the ingestion of contaminated coleslaw [11]. Subsequently, many other foodstuffs have been implicated in different outbreaks, including cheeses made with raw or pasteurized milk or milk derivatives [12–23], meat products [24–29], and fruits and vegetables [30–34]. Table 1 summarizes the food products that are usually implicated in the occurrence of foodborne listeriosis. In addition, hospitalized individuals also seem to be at risk of acquiring *L. monocytogenes* infections [35]. To optimize the tracking of listeriosis cases, whole-genome sequencing has been developed; this has replaced older techniques, such as serotyping [36,37]. However, the question of why outbreaks of listeriosis can occur in humans remains incompletely understood; a

possible enhancement of organism-specific virulence factors may play a role in developing epidemic dissemination.

Table 1. Foods that are usually implicated in foodborne listeriosis.

Dairy Products	Fruits and Vegetables	Meat Products	Fish Products
Pasteurized whole milk	Coleslaw (cabbage)	Delicatessen foods (deli meats)	
Chocolate milk	Lettuce	Pâté	
Soft cheese (different types)	Corn	Foie gras	
Hard cheese	Rice salad	Uncooked hot dogs	
Mexican-style cheese	Salted mushrooms	“Rillettes”	Shrimp salad
Goat cheese	Sprouts	Pork tongue in aspic	Tuna salad
Ice cream	Strawberries	Pork pie	Smoked fish
Fresh cream	Nectarines	Beef	
	Apples	Turkey franks	
	Cantaloupes	Jellied pork	
	Blueberries	Cooked ham	
	Stone fruit	Ox tongue	
		Undercooked chicken	

Also, sporadic cases of listeriosis can be foodborne-related; reports of sporadic cases of *L. monocytogenes* infection in the absence of documented outbreaks have been associated with different food products that could represent vehicles for the occurrence of sporadic invasive listeriosis in humans [38]. Consequently, *L. monocytogenes* can be considered a common contaminant of food products; the ingestion of small quantities of this microorganism occurs frequently in humans [39]. *L. monocytogenes* usually grows in biofilms or in food products that have not undergone pasteurization and those which are kept at cold temperatures. Invasive diseases occur when the ingestion of a large number of microorganisms overwhelm the innate host-defense systems at the gastrointestinal, liver, or spleen levels. Although the annual rate of sporadic listeriosis in Europe and North America is usually <1/100,000 population per year [40–42], the development of this infection is associated with a high burden of costs [43,44]. Sporadic listeriosis usually follows seasonal variations, being more common during the spring and summer seasons; it is mainly associated with the increased consumption of higher-risk products during warmer periods. In addition, the risk of developing invasive listeriosis could be associated with the presence of pre-existing damage in the gastrointestinal mucosa due to other microorganisms that induce viral gastroenteritis and that have seasonal patterns that may overlap with those of listeriosis. Such damage may allow the translocation of *L. monocytogenes* from the gastrointestinal tract, followed by the subsequent development of invasive diseases [45].

All isolates of *L. monocytogenes* are able to produce all the virulence factors characteristic of the species. Several virulence factors of *L. monocytogenes* have been identified and extensively characterized at both the molecular and cell biologic levels, including the hemolysin (listeriolysin O), two distinct phospholipases, a protein (ActA), several internalins, and others. Study of these provides an impressive improvement in our knowledge of the mechanisms used by *L. monocytogenes* to interact with mammalian host cells, escape the host cell’s killing mechanisms, and spread from one infected cell to others. In particular, after the infection of the host cells, the microorganisms are internalized in a vacuole. Expression of listeriolysin O promotes escape from the vacuole into cytoplasm, where *L. monocytogenes* can replicate. The intracytoplasmic microorganisms use the actin of the host cell, in conjunction with their ActA protein, to promote their motility intracellularly, their location in protruding pseudopods, and the engulfment of the pseudopods by the adjacent host cells. After their uptake by adjacent cells, the bacteria escape the now-double-membrane-bound vacuole by means of listeriolysin O and the phospholipases, and the cycle continues to repeat. The production of listeriolysin O in the host cell is under stringent regulatory control; this virulence factor is expressed in the vacuole but not in the

cytosol, preventing the killing of the host cell and allowing the host cell cytoplasm to serve as a safe haven for microorganism survival and replication. In addition, several molecular subtyping tools have been developed to facilitate the detection of different strain types and lineages of the pathogen, including those implicated in common-source outbreaks of the disease [46]. Genetic studies continue to identify genes essential for the virulence of *L. monocytogenes* [47,48]. Although the key virulence factors known to date (listeriolysin O, phospholipases, ActA, internalins A and B, and others) are present in all serotypes, their regulation of expression may differ among the serotypes. Furthermore, strains of serotypes 1/2b and 4b may have additional virulence determinants, which will not become identified until and unless strains of these serotypes become included in genetic studies of virulence. The identification of potentially unique virulence factors of these strains may be aided by the use of comparative genomic analyses.

Host-specific conditions also contribute to the increased risk of invasive listeriosis [49,50]. In particular, cases of invasive listeriosis are most commonly described in the first month of life or among elderly individuals. The fetus is mainly infected during maternal sepsis or secondary–peri-vaginal or peri-anal colonization in the birthing parent, with transmission occurring through the birth canal. Infants usually do not have an adequate host defense, mainly in cases of impairment of macrophage and cell-mediated immune function; therefore, invasive listeriosis can easily develop in case of colonization of the liver, respiratory tract, or gastrointestinal tract. Pregnant people have usually a decreased gastrointestinal motility and also a slight impairment in their cell-mediated immune response to *L. monocytogenes*; both these conditions may predispose them to invasive listeriosis, followed by transplacental infection of the infant [51–54]; this can finally lead to the delivery of a premature and often severely ill newborn. Spontaneous recovery of the birthing parent from invasive listeriosis normally occurs after the delivery; the administration of specific and appropriate antibiotic therapy can improve the prognosis of the infant and also accelerate the clinical recovery of the birthing parent. When the infant is infected through a colonized birth canal, clinical disease in the infant usually develops 7–14 days later. A direct cutaneous invasion is unlikely in this context; aspiration of *L. monocytogenes* into the respiratory tract or by swallowing the microorganism can occur only during the incubation period. Recently, a unique outbreak of neonatal listeriosis has been described. *L. monocytogenes* was spread through contaminated mineral oil used to clean infants after delivery from healthy birthing parents, with cross-contamination of shared mineral oil; the index case was infected through the placental route of maternal–fetal infection [55].

The increased risk of invasive listeriosis among the elderly usually reflects the increasing incidence of other immunosuppressive conditions in this specific population, such as solid or hematological malignancies, chronic diseases leading to immunological impairment such as diabetes or renal failure, or immunosuppressive treatments. In particular, malignancies may lead to abnormalities in the gastrointestinal mucosa and the impairment of effective macrophage function in liver, spleen, and peritoneum, both directly or secondary to chemotherapy- or radiation-induced damages; finally, bacterial translocation from the gastrointestinal tract is favored. The increasing use of immunosuppressive treatments with a specific effect on cell-mediated immune function as corticosteroids or cyclosporine A, as well as the use of biologic treatments with an immune modulator effect, such as tumor necrosis factor- α inhibitors, can also contribute to an increased risk of invasive listeriosis [56–58].

Among the causes of immunosuppression, HIV infection has been linked to the occurrence of sporadic invasive listeriosis [59]. In particular, earlier studies have described a 500–1000-fold greater risk of developing invasive listeriosis among HIV-infected individuals compared to the general population. Subsequently, a progressive reduction in reported cases has been observed, due to dietary recommendations to prevent foodborne illnesses and, above all, due to the wide use of trimethoprim-sulfamethoxazole as *Pneumocystis jirovecii* pneumonia prophylaxis, which *L. monocytogenes* is also susceptible to; furthermore, a possible contribution to the reduction in cases may be secondary to the widespread use

of more efficient antiretroviral treatments that induce a restoration of immune system function [60].

L. monocytogenes is, overall, considered to be one of the most important foodborne pathogens associated with the occurrence of febrile gastroenteritis outbreaks. Several foods have been described as vehicles of these outbreaks, including fresh cheese, ready-to-eat meat, shrimps, rice or corn salad, and chocolate milk [15,22,61–66]. In these outbreaks, symptoms develop soon after ingestion (approximately 24 h) and attack rates have been found to be significantly greater when compared to invasive listeriosis. These high attack rates are not usually related to the enhanced intrinsic virulence of the *L. monocytogenes* strain but rather to the heavy contamination of the ingested food.

A reduction in the overall incidence of listeriosis could be due to a larger promotion of dietary recommendations to high-risk individuals, including pregnant people, people with malignancies, or people undergoing transplantation [67]. It is more likely that this reduction is due to the worldwide increase in awareness in the food-processing industry, including hazard analysis at critical control point (HACCP) [68,69]; above all, the improvement may be attributable to programs that have been formed to reduce food contamination with different microorganisms including *L. monocytogenes*, *Salmonella* spp., *Escherichia coli*, and *Campylobacter* spp. [70–72]. These activities have provided augmented protection for fresh, unprocessed food products that may not have been cooked or pasteurized and that are at higher risk of conveying foodborne illnesses. In addition to hazard analysis, regulatory agencies have implemented the control of those microorganisms that have the ability to potentially contaminate food. The U.S. Food and Drug Administration has developed strict recommendations for the control of *L. monocytogenes* in the food industry [73], mainly including the use of whole-genome sequences (WGSs) [74]. Recently, Conrad et al. [75] described how, starting from five cases of invasive listeriosis in Kansas, the use of WGSs enabled the identification of *L. monocytogenes* contamination of ice cream products in three other states; the facilities where the ice creams were being produced were located in Texas and Oklahoma, suggesting long-standing contamination. Other countries have adopted less stringent guidelines, allowing a small amount of contamination ($<10^2$ CFU/g); this small permitted amount was chosen to enable a balance to be attained between the protection of public health and the needless condemnation of otherwise edible food products. While invasive listeriosis seems more common in some European countries than in United States, it is still unclear whether these differences can be attributed to the less stringent standards in Europe. It remains therefore debatable if a “zero tolerance” approach for *L. monocytogenes* contamination of food could be preferable to a risk assessment approach [76].

2. Clinical Findings Due to *Listeria monocytogenes*

L. monocytogenes infections are associated with a broad variety of clinical findings in both humans and animals. Sepsis caused by *L. monocytogenes* was first described in an epizootic affecting South African rodents and in laboratory colonies of rabbits [77,78]. The species name *monocytogenes* was suggested as a result of the production of monocytosis in blood; while monocytosis-producing antigens have been considered to be a virulence factor for *L. monocytogenes*, monocytosis in the peripheral blood is not considered to be a distinguishing factor in finding human infections [79].

Many wild and domestic animals are susceptible to invasive listeriosis. Animals can acquire *L. monocytogenes* through grazing; this is further amplified by fecal contamination in soil and vegetation. However, farm animals and in particular ruminants can acquire listeriosis not only from forage, but also from silage. In fact, a very intense keratoconjunctivitis which farmers call “silage-eye” is often described among sheep and goats affected by listeriosis; the condition has been correlated with the intake of silage that is not well fermented and is therefore potentially contaminated by *L. monocytogenes*. In ruminants, *L. monocytogenes* has been implicated as a possible cause of abortion and prematurity [80]. The clinical syndromes associated with listeriosis in humans were discovered later. Neonatal listeriosis was first described in Europe among premature septic newborns during the

post-war period [81]; subsequently, other reports described neonatal meningitis as late-onset listeriosis occurring in the post-partum period. In the developed world, listeriosis is a frequent cause of neonatal meningitis; however, the wide use of antibiotic prophylaxis to prevent group B streptococcal infection has reduced cases of neonatal listeriosis [82,83].

3. Bone and Vertebral Infections by *L. monocytogenes*

L. monocytogenes only rarely causes bone and joint infections; this usually occurs in the context of prosthetic material that can provide a site for bacterial seeding.

3.1. Imaging Techniques

When suspecting bone or vertebral infections, the use of imaging techniques such as radiography or CT scans could provide valuable information in terms of bone erosions and vertebral bone integrity, mainly in the later stages of the disease; during the early stage of infection, no significant finding is usually detected. Furthermore, spinal stability must be assessed among patients in whom surgical management is being considered. Indeed, vertebral collapse, kyphotic deformity, and loss of normal lordosis can be found in advanced infections. CT also provides guidance for percutaneous aspirations in order to provide specimens for bacteriologic analysis in the presence of a fluid collection. MRI is the gold standard and represents the diagnostic imaging modality of choice. It should be performed among all patients for whom a spinal infection is suspected, unless contraindicated. Unenhanced T1-weighted images usually reveal a hypointense signal at the level of the end plates in the vertebral body and loss of a normal hyperintense fat signal in the vertebral bone marrow. T2-weighted imaging reveals a high signal corresponding to edema in the disk space and occasionally in the bone and paravertebral soft tissues. Gadolinium-enhanced T1-weighted imaging can demonstrate the contrast enhancement of the vertebral body, end plates, the prevertebral and paravertebral soft tissues, and the epidural space. Whenever the MRI is contraindicated or non-diagnostic (e.g., due to the presence of metallic implants causing artifacts), other imaging modalities should be considered. CT myelography provides another way of visualizing the spinal cord and ruling out compression in the setting of suspected cauda equina syndrome. On the contrary, nuclear medicine scans with radionuclide studies offer a high degree of sensitivity in the early stages of the disease. Spinal infections can occasionally be multifocal, so the whole spine should be scanned if an infectious focus is detected.

3.2. Microbiological Diagnosis

The determination of a microbiological diagnosis of *L. monocytogenes* bone or vertebral infection is challenging, especially in the absence of referred exposures or negative blood tests. In this context, aspiration biopsy or surgical sampling represent the optimal method of providing a valid microbiological diagnosis. As a consequence, empiric antibiotic therapy should be delayed if the patient is hemodynamically stable and has no neurological signs in order to obtain valid samples for cultures; postponing antimicrobial administration can improve the microbiological yield, so it could be preferably deferred in the absence of life-threatening conditions or spinal cord involvement [84]. However, the initiation of an antibiotic treatment does not always preclude undertaking a biopsy [85]; in those cases where antibiotic treatment has already been started, it has been demonstrated that interrupting and withholding antibiotics for 2 weeks led to a better yield compared to holding for only 3 days pre-biopsy [86]. These data can vary according to the pharmacokinetics, dose, duration, and bone penetration of the selected antibiotic. Nevertheless, a short duration of empiric antibiotic exposure does not negatively impact pathogen recovery and therefore is not an absolute contraindication for biopsy [87]. Therefore, all these diagnostic and therapeutic issues should be taken into consideration when managing *L. monocytogenes* vertebral infections.

3.3. Surgical Approach

In the absence of neurological deficits or sepsis, the optimal therapeutic approach comprises medical management with adequate intravenous antibiotics and immobilization of the affected spinal segment. Antibiotic therapy should be started as soon as the microorganism has been isolated in order to achieve sterilization of the infected bone or vertebral disc and prevent the occurrence of a neurological deficit or painful deformity. The duration of antibiotic therapy varies depending on the extent of bone involvement and the status of the patient's immune system. Neurosurgical intervention should be considered only after taking into account a given patient's neurological status as well as the extent of bone erosion and the specific vertebral level involved. The principles of surgical treatment include debridement of infected tissue, decompression of neural elements, and the restoration of spinal alignment and/or correction of spinal instability. The presence of neurological deficits is considered to be the most important factor in the decision-making process. Regardless of the duration of the weakness, emergency surgical intervention is offered unless the motor deficit is minimal. Patients for whom non-surgical management is considered should be carefully monitored; this is because early progression with neurological deterioration may occur rapidly. Surgical approaches for spinal infections are usually dictated by the site of compression (ventrally vs. dorsally located lesions) and tailored to the vertebral level involved. The nature of the compressive lesion is also relevant; the liquid collection of pus can be drained, whereas a mass of granulation tissue or retro pulsed bone are better addressed with an open surgical approach. In addition, the optimal surgical approach is selected after consideration of the intrinsic features of each anatomic region of the spine and the likelihood of postoperative instability. The degree of kyphotic deformity, the number of vertebral elements involved, and the bone and posterior tension band integrity can be used to determine the extent of spinal instrumentation required to restore stability. Surgical intervention is also indicated after the failure of medical management or patients with chronic pain, significant deformity, or spine instability in the setting of spinal infection or its sequelae.

3.4. Antibiotic Treatment of Bone and Vertebral *L. monocytogenes* Infections

Reports of *L. monocytogenes* bone infections are usually described in patients with predisposing factors, such as diabetes, leukemia, or receipt of long-term corticosteroids or immune-modulant treatments [88–92]. Usually, native vertebral *L. monocytogenes* infections have an insidious course, with symptoms, especially back pain, that could be present for over a year, as described in previous reports [93,94]. In the review by Charlier et al., more than 70% of cases of listeriosis involving bone and joint infections were subacute or chronic at the onset. Furthermore, most of these cases occurred in the hip (60%) and in prosthetic joints [88]. In this review, patients with osteomyelitis caused by *L. monocytogenes* showed only a mild increased in inflammatory markers compared with those with other forms of bacterial osteomyelitis. Vertebral osteomyelitis represents an even less frequent localization of invasive listeriosis. To date, eight cases [93–100] have been reported in the literature and most of them had significant risk factors for developing invasive listeriosis (Table 2). Figure 1 showed the MRI evolution of a patient with epidural abscess by *L. monocytogenes* from diagnosis to complete recovery after both surgical and antibiotic treatment [101]. All these patients were treated with ampicillin or amoxicillin or benzyl penicillin; five patients received a treatment combination with aminoglycosides; treatment duration was highly heterogeneous among these reports, ranging from 6 to 28 weeks in accordance with possible delayed clinical responses. Only one report [97] used trimetoprim/sulphamethoxazole as an oral maintenance treatment; however, this was not combined with amoxicillin in any of the studies. Oral use of amoxicillin was described in two other reports and was administered for a total of 12 and 18 weeks, respectively [98,99]. The antibiotic treatment should often be associated with surgical intervention in cases of spinal *L. monocytogenes* infections, especially for those patients experiencing neurological deficit, cord compres-

sion, destruction of the vertebrae with instability, large epidural abscesses, or inadequate responses to antimicrobials [102].

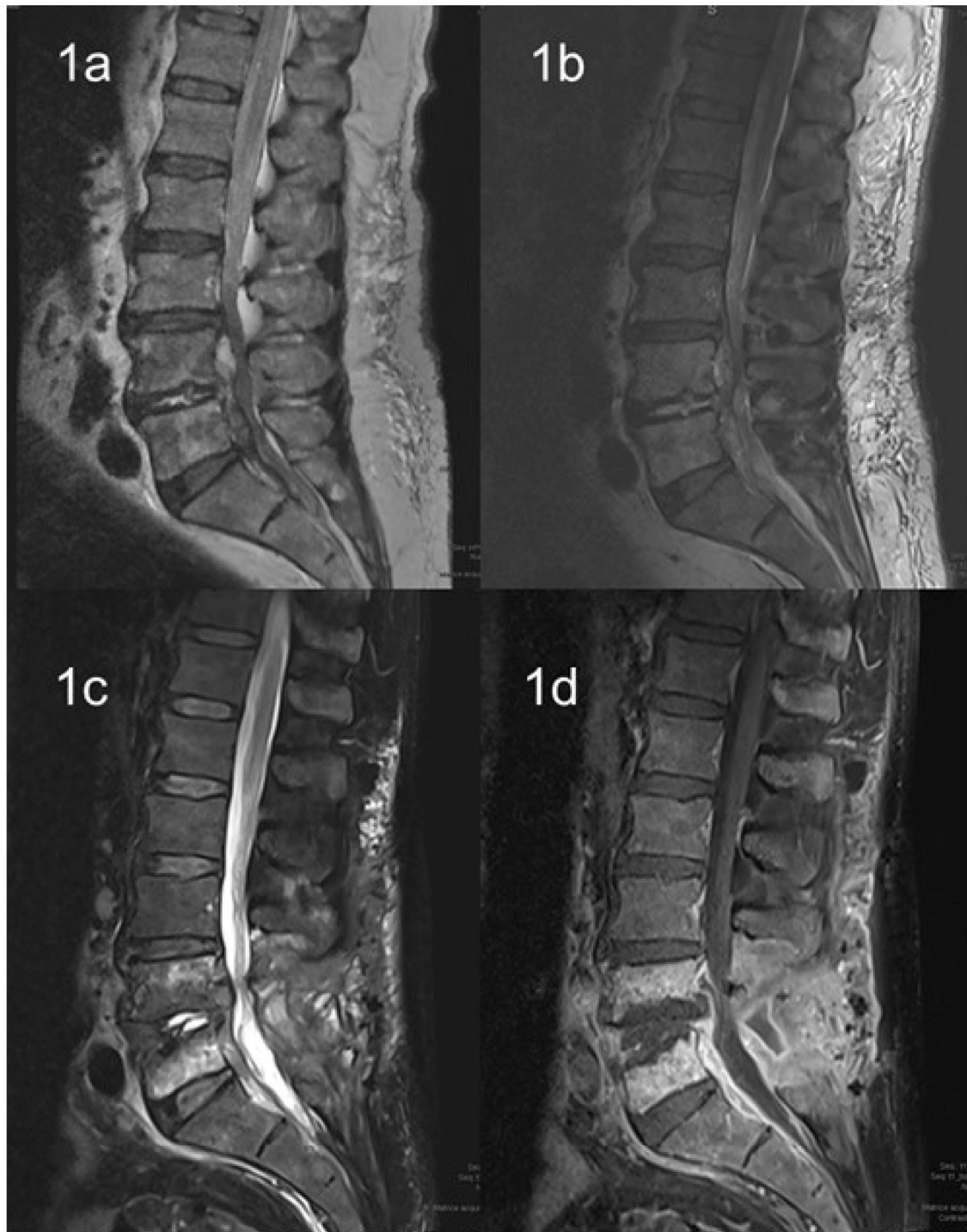


Figure 1. Evolution of MRI in a patient with epidural abscess by *L. monocytogenes*. (1a) T2 weighted image at baseline; (1b) T2 weighted image after 10 days; (1c,1d) T2 and T1 weighted with contrast at clinical resolution.

Table 2. Characteristics of patients with *Listeria monocytogenes* vertebral osteomyelitis.

Author	Age	Gender	Co-Morbidities	Clinical Symptoms	Duration of Symptoms	Antibiotic Treatment and Duration	Surgery
Adebolu et al. [93]	60	M	Polymyalgia rheumatica	Back pain	12 months	Ampicillin, IV, 6 weeks Gentamicin, IV, 2 weeks	Yes
Khan et al. [94]	69	M	Prior spinal laminectomy	Back pain	5 months	Ampicillin, IV * Gentamicin, IV *	Yes
Camp et al. [95]	67	M	DM, prior lumbar surgery	Back pain	Unknown	Oxacillin, IV * Streptomycin, IV *	Yes
Chirgwin et al. [96]	57	M	DM, asthma	Fever, back pain	3 weeks	Ampicillin, IV, 6 weeks Tobramycin, IV, 6 weeks	Yes
Aubin et al. [97]	92	M	DM, heart failure, hip arthroplasty	Fever	1 week	Amoxicillin, IV, 6 days Gentamicin, IV, 4 days Trimethoprim-sulfamethoxazole, oral, 12 weeks	Yes
Hasan et al. [98]	63	M	DM, aortic valve replacement	Fever, back pain	2 days	Benzyl penicillin, IV, 6 weeks Rifampicin, oral, 4 weeks Amoxicillin, oral, 18 weeks	Yes
Duarte et al. [99]	65	M	DM	Fever	5 days	Ampicillin, IV, 2 weeks Amoxicillin, oral, 12 weeks	Yes
Al Ohaly et al. [100]	79	M	Hypertension, carotid bypass, repair of AAA	Back pain	3 weeks	Ampicillin, IV, 6 weeks	No

M: male; DM: diabetes mellitus; IV: intravenously; AAA: abdominal aortic aneurysm; * duration not specified.

4. Other Clinical Features

4.1. Listeriosis and Pregnancy

Pregnant people have an increased risk of *L. monocytogenes* infections; these can lead to chorioamnionitis and finally to early-onset neonatal listeriosis [51]. Infants with listeriosis have a peculiar constellation of clinical features, including prematurity sepsis at birth, fever, cutaneous maculo-papular exanthema, and jaundice [103]. In this context, the mortality rate is very high, even when a prompt, specific antibiotic treatment is started. Autopsy findings showed chorioamnionitis in placental remnants and multiple granulomas in the spleen and liver of the infants; the syndrome, when first described, was therefore called “granulomatosis infantispetica” [81]. While such infants usually have dramatic findings, their birthing parents may be asymptomatic or may commonly have only mild symptoms, like flu-like or urinary or gastrointestinal symptoms, before their blood cultures were shown to be positive for *L. monocytogenes*. The rapid administration of antibiotic treatment to birthing parents with *L. monocytogenes* bacteremia can prevent transplacental infection, with a delivery of an uninfected infant [104]. However, this is a very unusual condition and can only happen when a community-based outbreak of *L. monocytogenes* is identified in specific geographical areas through public health alerts. Symptoms of late-onset neonatal meningitis due to *L. monocytogenes* usually occur 1–2 weeks after delivery; these symptoms have been found to include fever, irritability, bulging fontanelle, and meningismus [105]. In this context, the birthing parent does not develop any septic complication during pregnancy, delivery, or the post-partum period.

4.2. Meningoencephalitis

Invasive *L. monocytogenes* infections have been associated with meningitis in adults. Usually, the clinical symptoms are those of subacute bacterial meningitis with fever, headache, and neck stiffness that can develop over several days [106]. During epidemics of foodborne listeriosis, meningitis caused by *L. monocytogenes* can also occur in apparently healthy individuals of all ages; on the contrary, in sporadic diseases, a defect in cell-mediated immune function can predispose subjects to this finding of invasive listeriosis. In addition, *L. monocytogenes* can induce rhomboencephalitis in humans and in animals; this is described mainly as circling disease [107]. When these features appear,

fever, headache, nausea, and vomiting occur early, and signs of meningeal irritation are less commonly observed. Subsequently, multiple abnormalities of cranial nerves develop with associated cerebellar dysfunction, mainly ataxia. Fever is not present in up to 15% of patients, leading to a more difficult diagnosis. However, the presence of micro abscesses in the cerebellum and diencephalon could aid in the diagnostic process. This variant has a mortality of 50% and a high risk of neurological sequelae, despite prompt administration of antibiotic treatment.

It has been reported that *L. monocytogenes* infiltrates the brain either directly from blood or the nervous cell fibers connected to peripheral tissues [108]. *L. monocytogenes* is able to cross the blood–brain barrier, recognizing specific receptors as E-cadherin or Met at the surface of the barrier, and then adheres by using Internalin- (Inl) A and Inl-B and finally passes the blood–brain barrier [109]. Another way in which *L. monocytogenes* enters the brain is the transportation of the microorganism inside infected phagocytic cells, such as monocytes and dendritic cells or bone marrow myelomonocytic cells, directly to the CNS (the so-called Trojan horse mechanism) [110,111]. Afterwards, the bacterium is able to infect the brain neurons spreading from these carrying cells [112]. Recently, it has been demonstrated in a mouse model of neurolisteriosis using hypervirulent *L. monocytogenes* strains that monocytes are necessary and sufficient to induce neuroinvasion. It has also been documented that Inl-B possesses a major role in this process, whereas Inl-A is not involved [113].

4.3. *Listeria monocytogenes* Sepsis

Bacteremia by *L. monocytogenes* without central nervous system involvement represents approximately one-third of adult cases of invasive listeriosis. Symptoms are usually a-specific, but fever and chills are often present. The occurrence of *L. monocytogenes* sepsis is often associated with pre-existing cancers, organ transplants, or other causes of immune depression, and has a mortality rate of up to 30%. In this context, the symptoms are nonspecific and can mimic the sepsis caused by other Gram-positive or Gram-negative bacteria [114,115].

4.4. Gastroenteritis

L. monocytogenes can cause febrile gastroenteritis with diarrhea and abdominal pain, especially during large outbreaks of foodborne adult listeriosis, with a high burden of microorganisms in the contaminated food [15,22,23,61–65,116]. Most patients are healthy before the development of the infection; bacteremia is an unusual finding in this setting and most patients develop symptoms within 24 h following exposure; a large amount of microorganisms (up to 10^9 CFU/g) is usually found in the contaminated food. During these outbreaks, pregnant people have a particularly high risk of developing sepsis and invasive listeriosis; the isolation of *L. monocytogenes* from stool is unusual, but serological tests have been widely used to better define the extent of the outbreaks. In the outbreaks reported to date, reported foods have been identified as shrimp salad, chocolate milk, corn, deli meats, and fresh cheese. Invasive listeriosis with meningoencephalitis could finally occur in this context when the gastrointestinal mucosa lost its integrity for other bacterial or viral concomitant gastroenteritis [49,117].

4.5. Endocarditis

Endocarditis caused by *L. monocytogenes* usually follows transient bacteremia from a gastrointestinal focus with the subsequent endovascular infection of an abnormal heart valve; over 50% of cases of endocarditis cause by *L. monocytogenes* involved prosthetic valves, whereas cases in native valves are sporadic [118,119]. Diagnostic criteria included the presence of a prosthetic valve with or without vegetation and a continuous bacteremia by *L. monocytogenes*; septic emboli and abscesses in other organs are relatively frequent and can occur in approximately two-thirds of patients. Aortic and mitral valves are the most commonly involved valves. In native valve endocarditis, *L. monocytogenes* infection

can sporadically follow previous episodes of streptococcal bacterial endocarditis or other valvular heart diseases. Reports of patients with malignancy, diabetes, prolonged steroid therapy, and renal and liver transplantation with *L. monocytogenes* endocarditis have been published to date [120]. The clinical presentation is usually nonspecific for *L. monocytogenes* and includes prolonged fever, chills, and, ultimately, signs of congestive heart failure. In these cases, diagnosis can be obtained only by systematically performing blood cultures. *L. monocytogenes* can also cause arterial infections that involve prosthetic abdominal and aortic grafts or native abdominal aortic aneurysms [121]. The mortality rate of this condition approached 40% before 1985 but has been reduced to 12% with better recognition and surgical management. In this context, a multidisciplinary approach is mandatory for better management of the antibiotic treatment, the surgical intervention, and the increased risk of systemic complications.

4.6. Abdominal Infections

L. monocytogenes-associated hepatitis has been described in several case reports [122]. Though the diagnosis is often unsuspected, severe diseases can occur; autopsy findings showed micro abscesses and occasional granulomas that were similar to those observed in neonatal disease [123]. Solitary and multiple liver abscesses with fever have also been reported [124,125]. Predisposing factors for liver complications caused by *L. monocytogenes* included cirrhosis, liver transplantation, diabetes mellitus, and alcoholism.

Recently, *L. monocytogenes* has been described as a possible cause of biliary tract infections, mainly by retrograde infection from contaminated food and because the microorganisms are resistant to bile [126,127]. Immunosuppression due to corticosteroids and use of biologic agents to treat underlying conditions are well-established risk factors for this infection; the mortality rate is high, mainly due to inappropriate antibiotic therapy decisions following misleading diagnoses.

L. monocytogenes can also cause isolated episodes of peritonitis, especially among patients receiving peritoneal dialysis with isolation of the microorganism from dialysate or blood cultures, or among those with advanced liver diseases [128–132]. Infections are usually secondary to the translocation of the microorganism from the gastrointestinal tract among patients who have ingested *L. monocytogenes* with food. The mortality rate is low; it is comparable to that of spontaneous bacterial peritonitis caused by other microorganisms.

4.7. Cutaneous Infections

Cutaneous listeriosis is an occupational hazard for veterinary workers exposed to infected amniotic fluid or placental remnants that are removed from the birth canal of animals [133,134]. Also, conjunctivitis has been reported among laboratory workers [135]. In these conditions, *L. monocytogenes* is usually isolated by the multiple papulo-pustular lesions of the skin; findings are similar to those observed in infants with early-onset disseminated listeriosis. In adults, the infection is usually self-limited and people recover spontaneously without antibiotic treatment; however, its occurrence is easily preventable with the appropriate use of gloves and other protective wears.

5. Conclusions

In this paper, we present a comprehensive description of clinical findings surrounding *L. monocytogenes*. We mainly focused on bone and vertebral infections caused by *L. monocytogenes*, because these localizations are usually underestimated, except in cases of outbreaks. In fact, in the literature, very few data have been reported for this specific localization, and most of them are extrapolated by case reports. We described the diagnostic and the clinical management of patients with bone infections due to *L. monocytogenes*, as well as the surgical and the optimal antibiotic treatment for this condition. Despite the limited number of reports, consideration for *L. monocytogenes*-associated osteomyelitis should be taken in account as part of the differential diagnosis, even in the absence of prosthetic material, in the context of epidemiologic risk factors especially. However, this diagnosis should

also be considered in those individuals living in areas with relatively low incidences of *L. monocytogenes* infections, because sporadic outbreaks can occur everywhere.

Funding: This research received no external funding.

Data Availability Statement: Not applicable.

Conflicts of Interest: The authors declare no conflicts of interest.

References

- Welshimer, H.J.; Donker-Voet, J. *Listeria monocytogenes* in nature. *Appl. Microbiol.* **1971**, *21*, 516–519. [\[CrossRef\]](#)
- Linke, K.; Ruckerl, I.; Brugger, K.; Karpiskova, R.; Walland, J.; Muri-Klinger, S.; Tichy, A.; Wagner, M.; Stessl, B. Reservoirs of *Listeria* species in three environmental ecosystems. *Appl. Environ. Micro.* **2014**, *80*, 5583–5592. [\[CrossRef\]](#)
- Law, J.W.; Mutalib, N.S.; Chan, K.G.; Lee, L.H. An insight into the isolation, enumeration, and molecular detection of *Listeria monocytogenes* in food. *Front. Microbiol.* **2015**, *6*, 1227–1242. [\[CrossRef\]](#) [\[PubMed\]](#)
- Graves, L.M.; Swaminathan, B.; Ajello, G.W.; Malcolm, G.D.; Weaver, R.E.; Ransom, R.; Dever, K.; Plikaytis, B.D.; Schuchat, A.; Wenger, J.D.; et al. Comparison of three selective enrichment methods for the isolation of *Listeria monocytogenes* from naturally contaminated foods. *J. Food Prot.* **1992**, *55*, 952–959. [\[CrossRef\]](#)
- Bres, V.; Yang, H.; Hsu, E.; Ren, Y.; Cheng, Y.; Wisniewski, M.; Hanhan, M.; Zaslavsky, P.; Noll, N.; Weaver, B.; et al. *Listeria monocytogenes* LmG2 detection assay using transcription mediated amplification to detect *Listeria monocytogenes* in selected foods and stainless steel surfaces. *J. AOAC Int.* **2014**, *97*, 1343–1358. [\[CrossRef\]](#) [\[PubMed\]](#)
- Reissbrodt, R. New chromogenic plating media for detection and enumeration of pathogenic *Listeria* spp.: An overview. *Int. J. Food Microbiol.* **2004**, *95*, 1–9. [\[CrossRef\]](#) [\[PubMed\]](#)
- Grif, K.; Hein, I.; Wagner, M.; Brandl, E.; Mpamugo, O.; McLauchlin, J.; Dierich, M.P.; Allerberger, F. Prevalence and characterization of *Listeria monocytogenes* in the feces of healthy Austrians. *Wien. Klin. Wochenschr.* **2001**, *113*, 737–742.
- Gahan, C.G.; Hill, C. *Listeria monocytogenes*: Survival and adaptation in the gastrointestinal tract. *Front. Cell Infect. Microbiol.* **2014**, *4*, 9–16. [\[CrossRef\]](#)
- Travier, L.; Guadagnini, S.; Gouin, E.; Dufour, A.; Chenal-Francisque, V.; Cossart, P.; Olivo-Marin, J.C.; Ghigo, J.M.; Disson, O.; Lecuit, M. ActA promotes *Listeria monocytogenes* aggregation, intestinal colonization and carriage. *PLoS Pathog.* **2013**, *9*, e1003131. [\[CrossRef\]](#)
- Low, J.C.; Renton, C.P. Septicaemia, encephalitis and abortions in a housed flock of sheep caused by *Listeria monocytogenes* type 1/2. *Vet. Rec.* **1985**, *116*, 147–150. [\[CrossRef\]](#)
- Schlech, W.F., III; Lavigne, P.M.; Bortolussi, R.A.; Allen, A.C.; Haldane, E.V.; Wort, A.J.; Hightower, A.W.; Johnson, S.E.; King, S.H.; Nicholls, E.S.; et al. Epidemic listeriosis: Evidence for transmission by food. *N. Engl. J. Med.* **1983**, *308*, 203–206. [\[CrossRef\]](#)
- Büla, C.J.; Bille, J.; Glauser, M.P. An epidemic of food-borne listeriosis in western Switzerland: Description of 57 cases involving adults. *Clin. Infect. Dis.* **1995**, *20*, 66–72. [\[CrossRef\]](#) [\[PubMed\]](#)
- Centers for Disease Control and Prevention (CDC). Outbreak of listeriosis associated with homemade Mexican-style cheese: North Carolina, October 2000–January 2001. *MMWR Morb. Mortal. Wkly. Rep.* **2001**, *50*, 560–562.
- Fretz, R.; Pichler, J.; Sagel, U.; Much, P.; Ruppitsch, W.; Pietzka, A.T.; Stoger, A.; Huhulescu, S.; Heuberger, S.; Appl, G.; et al. Update: Multinational listeriosis outbreak due to ‘quargel’, a sour milk curd cheese, caused by two different *L. monocytogenes* serotype 1/2a strains, 2009–2010. *Euro Surveill.* **2010**, *22*, 19543. [\[CrossRef\]](#)
- Carrique-Mas, J.J.; Hökeberg, I.; Andersson, Y.; Arneborn, M.; Tham, W.; Danielsson-Tham, M.L.; Osterman, B.; Leffler, M.; Steen, M.; Eriksson, E.; et al. Febrile gastroenteritis after eating on-farm manufactured fresh cheese: An outbreak of listeriosis? *Epidemiol. Infect.* **2003**, *130*, 79–86. [\[CrossRef\]](#) [\[PubMed\]](#)
- Linnan, M.J.; Mascola, L.; Lou, X.D.; Goulet, V.; May, S.; Salminen, C.; Hird, D.W.; Yonekura, M.L.; Hayes, P.; Weaver, R.; et al. Epidemic listeriosis associated with Mexican-style cheese. *N. Engl. J. Med.* **1988**, *319*, 823–828. [\[CrossRef\]](#) [\[PubMed\]](#)
- Choi, M.J.; Jackson, K.A.; Medus, C.; Beal, J.; Rigdon, C.E.; Cloyd, T.C.; Forstner, M.J.; Ball, J.; Bosch, S.; Bottichio, L.; et al. Multistate outbreak of listeriosis linked to soft-ripened cheese: United States, 2013. *MMWR Morb. Mortal. Wkly. Rep.* **2014**, *63*, 294–295.
- Jackson, K.A.; Biggerstaff, M.; Tobin-D’Angelo, M.; Sweat, D.; Klos, R.; Nosari, J.; Garrison, O.; Boothe, E.; Saathoff-Huber, L.; Hainstock, L.; et al. Multistate outbreak of *Listeria monocytogenes* associated with Mexican-style cheese made from pasteurized milk among pregnant, Hispanic women. *J. Food Prot.* **2011**, *74*, 949–953. [\[CrossRef\]](#)
- Koch, J.; Dworak, R.; Prager, R.; Becker, B.; Brockmann, S.; Wicke, A.; Wichmann-Schauer, H.; Hof, H.; Werber, D.; Stark, K. Large listeriosis outbreak linked to cheese made from pasteurized milk, Germany, 2006–2007. *Foodborne Pathog. Dis.* **2010**, *7*, 1581–1584. [\[CrossRef\]](#)
- Heiman, K.E.; Garalde, V.B.; Gronostaj, M.; Jackson, K.A.; Beam, S.; Joseph, L.; Saupe, A.; Ricotta, E.; Waechter, H.; Wellman, A.; et al. Multistate outbreak of listeriosis caused by imported cheese and evidence of cross-contamination of other cheeses, USA, 2012. *Epidemiol. Infect.* **2016**, *144*, 2698–2708. [\[CrossRef\]](#)

21. Fleming, D.W.; Cochi, S.L.; MacDonald, K.L.; Brondum, J.; Hayes, P.S.; Plikaytis, B.D.; Holmes, M.B.; Audurier, A.; Broome, C.V.; Reingold, A.L. Pasteurized milk as a vehicle of infection in an outbreak of listeriosis. *N. Engl. J. Med.* **1985**, *312*, 404–407. [\[CrossRef\]](#)
22. Dalton, C.B.; Austin, C.C.; Sobel, J.; Hayes, P.S.; Bibb, W.F.; Graves, L.M.; Swaminathan, B.; Proctor, M.E.; Griffin, P.M. An outbreak of gastroenteritis and fever due to *Listeria monocytogenes* in milk. *N. Engl. J. Med.* **1997**, *336*, 100–105. [\[CrossRef\]](#)
23. Lyytikäinen, O.; Autio, T.; Majjala, R.; Ruutu, P.; Honkanen-Buzalski, T.; Miettinen, M.; Hatakka, M.; Mikkola, J.; Anttila, V.J.; Johansson, T.; et al. An outbreak of *Listeria monocytogenes* serotype 3a infections from butter in Finland. *J. Infect. Dis.* **2000**, *181*, 1838–1841. [\[CrossRef\]](#) [\[PubMed\]](#)
24. MMWR. Public health dispatch: Outbreak of listeriosis: Northeastern United States. *MMWR Morb. Mortal. Wkly. Rep.* **2002**, *51*, 950–951.
25. de Valk, H.; Vaillant, V.; Jacquet, C.; Rocourt, J.; Le Querrec, F.; Stainer, F.; Quelquejeu, N.; Pierre, O.; Pierre, V.; Desenclos, J.C.; et al. Two consecutive nationwide outbreaks of listeriosis in France, October 1999–February 2000. *Am. J. Epidemiol.* **2001**, *154*, 944–950. [\[CrossRef\]](#)
26. Hachler, H.; Marti, G.; Giannini, P.; Lehner, A.; Jost, M.; Beck, J.; Weiss, F.; Bally, B.; Jermini, M.; Stephan, R.; et al. Outbreak of listeriosis due to imported cooked ham. *Euro Surveill.* **2013**, *18*, 20469. [\[PubMed\]](#)
27. Smith, B.; Larsson, J.T.; Lisby, M.; Müller, L.; Madsen, S.B.; Engberg, J.; Bangsbo, J.; Ethelberg, S.; Kemp, M. Outbreak of listeriosis caused by infected beef meat from a meals-on-wheels delivery in Denmark 2009. *Clin. Microbiol. Infect.* **2011**, *17*, 50–52. [\[CrossRef\]](#)
28. Currie, A.; Farber, J.M.; Nadon, C.; Sharma, D.; Whitfield, Y.; Gaulin, C.; Galanis, E.; Bekal, S.; Flint, J.; Tschetter, L.; et al. Multi-province listeriosis outbreak linked to contaminated deli meat consumed primarily in institutional settings, Canada, 2008. *Foodborne Pathog. Dis.* **2015**, *12*, 645–652. [\[CrossRef\]](#) [\[PubMed\]](#)
29. National Institute for Communicable Diseases. Situation Report on Listeriosis Outbreak, South Africa, 2017. 4 December 2017; pp. 1–3. Available online: <https://s3-us-west-2.amazonaws.com/listeriaclassactioncoza-images/pdfs/NICD-Situation-Report-20-December-2017.pdf> (accessed on 11 December 2023).
30. Self, J.L.; Conrad, A.; Stroika, S.; Jackson, A.; Burnworth, L.; Beal, J.; Wellman, A.; Jackson, K.A.; Bidol, S.; Gerhardt, T.; et al. Outbreak of listeriosis associated with consumption of packaged salad: United States and Canada. *MMWR Morb. Mortal. Wkly. Rep.* **2016**, *65*, 879–881. [\[CrossRef\]](#)
31. Angelo, K.M.; Conrad, A.R.; Saupe, A.; Dragoo, H.; West, N.; Sorenson, A.; Barnes, A.; Doyle, M.; Beal, J.; Jackson, K.A.; et al. Multistate outbreak of *Listeria monocytogenes* infections linked to whole apples used in commercially produced, prepackaged caramel apples: United States, 2014–2015. *Epidemiol. Infect.* **2017**, *145*, 848–856. [\[CrossRef\]](#)
32. Jackson, B.R.; Salter, M.; Tarr, C.; Conrad, A.; Harvey, E.; Steinbock, L.; Saupe, A.; Sorenson, A.; Katz, L.; Stroika, S.; et al. Listeriosis associated with stone fruit: United States, 2014. *MMWR Morb. Mortal. Wkly. Rep.* **2014**, *64*, 282–283.
33. Gaul, L.K.; Farag, N.H.; Shim, T.; Kingsley, M.A.; Silk, B.J.; Hyytia-Trees, E. Hospital-acquired listeriosis outbreak caused by contaminated diced celery: Texas, 2010. *Clin. Infect. Dis.* **2013**, *56*, 20–26. [\[CrossRef\]](#)
34. McCollum, J.T.; Cronquist, A.B.; Silk, B.J.; Jackson, K.A.; O'Connor, K.A.; Cosgrove, S.; Gossack, J.P.; Parachini, S.S.; Jain, N.S.; Ettestad, P.; et al. Multistate outbreak of listeriosis associated with cantaloupe. *N. Engl. J. Med.* **2013**, *369*, 944–953. [\[CrossRef\]](#)
35. Silk, B.J.; McCoy, M.H.; Iwamoto, M.; Griffin, P.M. Foodborne listeriosis acquired in hospitals. *Clin. Infect. Dis.* **2014**, *59*, 532–540. [\[CrossRef\]](#) [\[PubMed\]](#)
36. Datta, A.R.; Burall, L.S. Serotype to genotype: The changing landscape of listeriosis outbreak investigations. *Food Microbiol.* **2017**, *75*, 18–27. [\[CrossRef\]](#) [\[PubMed\]](#)
37. Kwong, J.C.; Mercoullia, K.; Tomita, T.; Easton, M.; Li, H.Y.; Bulach, D.M.; Stinear, T.P.; Seemann, T.; Howden, B.P. Prospective whole genome sequencing enhances national surveillance of *Listeria monocytogenes*. *J. Clin. Microbiol.* **2016**, *54*, 333–342. [\[CrossRef\]](#)
38. Schuchat, A.; Deaver, K.A.; Wenger, J.D.; Plikaytis, B.D.; Mascola, L.; Pinner, R.W.; Reingold, A.L.; Broome, C.V.; The Listeria Study Group. Role of foods in sporadic listeriosis. I. Case-control study of dietary risk factors. *JAMA* **1992**, *267*, 2041–2045. [\[CrossRef\]](#) [\[PubMed\]](#)
39. Grif, K.; Patscheider, G.; Dierich, M.P.; Allerberger, F. Incidence of fecal carriage of *Listeria monocytogenes* in three healthy volunteers: A oneyear prospective stool survey. *Eur. J. Clin. Microbiol. Infect. Dis.* **2003**, *22*, 16–20. [\[CrossRef\]](#)
40. Goulet, V.; de Valk, H.; Pierre, O.; Stainer, F.; Rocourt, J.; Vaillant, V.; Jacquet, C.; Desenclos, J.C. Effect of prevention measures on incidence of human listeriosis, France, 1987–1997. *Emerg. Infect. Dis.* **2001**, *7*, 983–989. [\[CrossRef\]](#)
41. Allerberger, F.; Wagner, M. Listeriosis: A resurgent foodborne infection. *Clin. Microbiol. Infect.* **2010**, *16*, 16–23. [\[CrossRef\]](#)
42. Centers for Disease Control and Prevention (CDC). Vital signs: Listeria illnesses, deaths, and outbreaks: United States, 2009–2011. *MMWR Morb. Mortal. Wkly. Rep.* **2013**, *62*, 448–452.
43. de Noordhout, C.M.; Devleeschauwer, B.; Angulo, F.J.; Verbeke, G.; Haagsma, J.; Kirk, M.; Havelaar, A.; Speybroeck, N. The global burden of listeriosis: A systematic review and meta-analysis. *Lancet Infect. Dis.* **2014**, *14*, 1073–1082. [\[CrossRef\]](#) [\[PubMed\]](#)
44. Thomas, M.K.; Vriezen, R.; Farber, J.M.; Currie, A.; Schlech, W.; Fazil, A. Economic cost of a *Listeria monocytogenes* outbreak in Canada, 2008. *Foodborne Pathog. Dis.* **2015**, *12*, 966–971. [\[CrossRef\]](#)
45. Schwartz, B.; Hexter, D.; Broome, C.V.; Hightower, A.W.; Hirschhorn, R.B.; Porter, J.D.; Hayes, P.S.; Bibb, W.F.; Lorber, B.; Faris, D.G. Investigation of an outbreak of listeriosis: New hypotheses for the etiology of epidemic *Listeria monocytogenes* infections. *J. Infect. Dis.* **1989**, *159*, 680–685. [\[CrossRef\]](#) [\[PubMed\]](#)

46. Kathariou, S. *Listeria monocytogenes* virulence and pathogenicity, a food safety perspective. *J. Food Prot.* **2002**, *65*, 1811–1829. [[CrossRef](#)] [[PubMed](#)]
47. Autret, N.I.; Dubail, P.; Trieu-Cuot, P.; Berche, P.; Charbit, A. Identification of new genes involved in the virulence of *Listeria monocytogenes* by signature-tagged mutagenesis. *Infect. Immun.* **2001**, *69*, 2054–2065. [[CrossRef](#)]
48. Lecuit, M.S.; Vandormael-Pournin, J.; Lefort, M.; Huerre, P.; Gounon, C.; Dupuy, C.; Babinet, C.; Cossart, P. A transgenic model for listeriosis: Role of internalin in crossing the intestinal barrier. *Science* **2001**, *292*, 1722–1725. [[CrossRef](#)] [[PubMed](#)]
49. Pouillot, R.; Hoelzer, K.; Jackson, K.A.; Henao, O.L.; Silk, B.J. Relative risk of listeriosis in Foodborne Diseases Active Surveillance Network (FoodNet) sites according to age, pregnancy, and ethnicity. *Clin. Infect. Dis.* **2012**, *54* (Suppl. S5), S405–S410. [[CrossRef](#)]
50. Dalton, C.B.; Merritt, T.D.; Unicomb, L.E.; Kirk, M.D.; Stafford, R.J.; Lalor, K.; OzFoodNet Working Group. A national case-control study of risk factors for listeriosis in Australia. *Epidemiol. Infect.* **2011**, *139*, 437–445. [[CrossRef](#)]
51. Girard, D.; Leclercq, A.; Laurent, E.; Lecuit, M.; de Valk, H.; Goulet, V. Pregnancy-related listeriosis in France, 1984 to 2011, with a focus on 606 cases from 1999 to 2011. *Euro. Surveill.* **2014**, *19*, 20909. [[CrossRef](#)]
52. Madjunkov, M.; Chaudhry, S.; Ito, S. Listeriosis during pregnancy. *Arch. Gynecol. Obstet.* **2017**, *296*, 143–152. [[CrossRef](#)]
53. Sridama, V.; Pacini, F.; Yang, S.L.; Moawad, A.; Reilly, M.; DeGroot, L.J. Decreased levels of helper T cells: A possible cause of immunodeficiency in pregnancy. *N. Engl. J. Med.* **1982**, *307*, 352–356. [[CrossRef](#)]
54. Wald, A.; Van Thiel, D.H.; Hoechstetter, L.; Gavaler, J.S.; Egler, K.M.; Verm, R.; Scott, L.; Lester, R. Effect of pregnancy on gastrointestinal transit. *Dig. Dis. Sci.* **1982**, *27*, 1015–1018. [[CrossRef](#)]
55. Schuchat, A.; Lizano, C.; Broome, C.V.; Swaminathan, B.; Kim, C.; Winn, K. Outbreak of neonatal listeriosis associated with mineral oil. *Pediatr. Infect. Dis. J.* **1991**, *10*, 183–189. [[CrossRef](#)] [[PubMed](#)]
56. Schlech, W.F., III. An animal model of foodborne *Listeria monocytogenes* virulence: Effect of alterations in local and systemic immunity on invasive infection. *Clin. Investig. Med.* **1993**, *16*, 219–225.
57. Bodro, M.; Paterson, D.L. Listeriosis in patients receiving biologic therapies. *Eur. J. Clin. Microbiol. Infect. Dis.* **2013**, *32*, 1225–1230. [[CrossRef](#)]
58. Holmøy, T.; von der Lippe, H.; Leegaard, T.M. *Listeria monocytogenes* infection associated with alemtuzumab: A case for better preventive strategies. *BMC Neurol.* **2017**, *17*, 65–69. [[CrossRef](#)]
59. Jurado, R.L.; Farley, M.M.; Pereira, E.; Harvey, R.C.; Schuchat, A.; Wenger, J.D.; Stephens, D.S. Increased risk of meningitis and bacteremia due to *Listeria monocytogenes* in patients with human immunodeficiency virus infection. *Clin. Infect. Dis.* **1993**, *17*, 224–227. [[CrossRef](#)]
60. Ewert, D.P.; Lieb, L.; Hayes, P.S.; Reeves, M.W.; Mascola, L. *Listeria monocytogenes* infection and serotype distribution among HIV-infected persons in Los Angeles County, 1985–1992. *J. Acquir. Immune Defic. Syndr. Hum. Retrovirol.* **1995**, *8*, 461–465. [[CrossRef](#)] [[PubMed](#)]
61. Riedo, F.X.; Pinner, R.W.; Tosca, M.L.; Cartter, M.L.; Graves, L.M.; Reeves, M.W.; Weaver, R.E.; Plikaytis, B.D.; Broome, C.V. A point-source foodborne listeriosis outbreak: Documented incubation period and possible mild illness. *J. Infect. Dis.* **1994**, *170*, 693–696. [[CrossRef](#)] [[PubMed](#)]
62. Salamina, G.; Dalle Donne, E.; Niccolini, A.; Poda, G.; Cesaroni, D.; Bucci, M.; Fini, R.; Maldini, M.; Schuchat, A.; Swaminathan, B.; et al. A foodborne outbreak of gastroenteritis involving *Listeria monocytogenes*. *Epidemiol. Infect.* **1996**, *117*, 429–436. [[CrossRef](#)]
63. Aureli, P.; Fiorucci, G.C.; Caroli, D.; Marchiaro, G.; Novara, O.; Leone, L.; Salmaso, S. An outbreak of febrile gastroenteritis associated with corn contaminated by *Listeria monocytogenes*. *N. Engl. J. Med.* **2000**, *342*, 1236–1241. [[CrossRef](#)] [[PubMed](#)]
64. Frye, D.M.; Zweig, R.; Sturgeon, J.; Tormey, M.; LeCavalier, M.; Lee, I.; Lawani, L.; Mascola, L. An outbreak of febrile gastroenteritis associated with delicatessen meat contaminated with *Listeria monocytogenes*. *Clin. Infect. Dis.* **2002**, *35*, 943–949. [[CrossRef](#)]
65. Sim, J.; Hood, D.; Finnie, L.; Wilson, M.; Graham, C.; Brett, M.; Hudson, J.A. Series of incidents of *Listeria monocytogenes* non-invasive febrile gastroenteritis involving ready-to-eat meats. *Lett. Appl. Microbiol.* **2002**, *35*, 409–413. [[CrossRef](#)] [[PubMed](#)]
66. Pichler, J.; Much, P.; Kasper, S.; Fretz, R.; Auer, B.; Kathan, J.; Mann, M.; Huhulescu, S.; Ruppitsch, W.; Pietzka, A.; et al. An outbreak of febrile gastroenteritis associated with jellied pork contaminated with *Listeria monocytogenes*. *Wien. Klin. Wochenschr.* **2009**, *121*, 149–156. [[CrossRef](#)] [[PubMed](#)]
67. Bennion, J.R.; Sorvillo, F.; Wise, M.E.; Krishna, S.; Mascola, L. Decreasing listeriosis mortality in the United States, 1990–2005. *Clin. Infect. Dis.* **2008**, *47*, 867–874. [[CrossRef](#)] [[PubMed](#)]
68. Tappero, J.W.; Schuchat, A.; Deaver, K.A.; Mascola, L.; Wenger, J.D. Reduction in the incidence of human listeriosis in the United States. Effectiveness of prevention efforts? The Listeriosis Study Group. *JAMA* **1995**, *273*, 1118–1122. [[CrossRef](#)]
69. Buchanan, R.L.; Whiting, R.C. Risk assessment: A means for linking HACCP plans and public health. *J. Food Prot.* **1998**, *61*, 1531–1534. [[CrossRef](#)]
70. Rocourt, J.; Hogue, A.; Toyofuku, H.; Jacquet, C.; Schlundt, J. *Listeria* and listeriosis: Risk assessment as a new tool to unravel a multifaceted problem. *Am. J. Infect. Control.* **2001**, *29*, 225–227. [[CrossRef](#)]
71. Panisello, P.J.; Rooney, R.; Quantick, P.C.; Stanwell-Smith, R. Application of foodborne disease outbreak data in the development and maintenance of HACCP systems. *Int. J. Food Microbiol.* **2000**, *59*, 221–234. [[CrossRef](#)]
72. McLauchlin, J.; Mitchell, R.T.; Smerdon, W.J.; Jewell, K. *Listeria monocytogenes* and listeriosis: A review of hazard characterisation for use in microbiological risk assessment of foods. *Int. J. Food Microbiol.* **2004**, *92*, 15–33. [[CrossRef](#)] [[PubMed](#)]
73. Thompson, P.; Salisbury, P.A.; Adams, C.; Archer, D.L. US food legislation. *Lancet* **1990**, *336*, 1557–1559. [[CrossRef](#)] [[PubMed](#)]

74. Jackson, B.R.; Tarr, C.; Strain, E.; Jackson, K.A.; Conrad, A.; Carleton, H.; Katz, L.S.; Stroika, S.; Gould, L.H.; Mody, R.K.; et al. Implementation of nationwide real-time whole-genome sequencing to enhance listeriosis outbreak detection and investigation. *Clin. Infect. Dis.* **2016**, *63*, 380–386. [\[CrossRef\]](#)
75. Conrad, A.R.; Tubach, S.; Cantu, V.; Webb, L.M.; Stroika, S.; Moris, S.; Davis, M.; Hunt, C.; Bradley, K.K.; Kucerova, Z.; et al. *Listeria monocytogenes* illness and deaths associated with ongoing contamination of a multiregional brand of ice cream products, United States, 2010–2015. *Clin. Infect. Dis.* **2023**, *76*, 89–95. [\[CrossRef\]](#) [\[PubMed\]](#)
76. Donnelly, C.W. *Listeria monocytogenes*: A continuing challenge. *Nutr. Rev.* **2001**, *59*, 183–194. [\[CrossRef\]](#)
77. Pirie, J.H.H. A new disease of veld rodents, Tiger River disease. *Publ. S. Afr. Inst. Med. Res.* **1927**, *3*, 163–186.
78. Murray, E.G.D.; Webb, R.A.; Swann, M.B.R. A disease of rabbits characterized by large mononuclear leucocytosis, caused by a hitherto undescribed bacillus: *Bacterium monocytogenes*. *J. Pathol. Bacteriol.* **1926**, *29*, 407–439. [\[CrossRef\]](#)
79. Shum, D.T.; Galsworthy, S.B. Stimulation of monocyte production by an endogenous mediator induced by a component from *Listeria monocytogenes*. *Immunology* **1982**, *46*, 343–351.
80. Lammerding, A.M.; Glass, K.A.; Gendron-Fitzpatrick, A.; Doyle, M.P. Determination of virulence of different strains of *Listeria monocytogenes* and *Listeria innocua* by oral inoculation of pregnant mice. *Appl. Environ. Microbiol.* **1992**, *58*, 3991–4000. [\[CrossRef\]](#)
81. Potel, J. Granulomatosis infantisepsica. *Zentralbl. Bakteriolog. Orig.* **1952**, *158*, 329–332.
82. Okike, I.O.; Johnson, A.P.; Henderson, K.L.; Blackburn, R.M.; Muller-Pebody, B.; Ladhani, S.N.; Anthony, M.; Ninis, N.; Heath, P.T.; Galiza, E.P.; et al. Incidence, etiology, and outcome of bacterial meningitis in infants aged < 90 days in the United Kingdom and Republic of Ireland: Prospective, enhanced, national population-based surveillance. *Clin. Infect. Dis.* **2014**, *59*, 150–157. [\[CrossRef\]](#)
83. Baltimore, R.S.; Huie, S.M.; Meek, J.I.; Schuchat, A.; O'Brien, K.L. Early-onset neonatal sepsis in the era of group B streptococcal prevention. *Pediatrics* **2001**, *108*, 1094–1098. [\[CrossRef\]](#)
84. De Lucas, E.M.; Mandly, A.G.; Gutiérrez, A.; Pellón, R.; Martín-Cuesta, L.; Izquierdo, J.; Sánchez, E.; Ruiz, E.; Quintana, F. CT-guided fine-needle aspiration in vertebral osteomyelitis: True usefulness of a common practice. *Clin. Rheumatol.* **2009**, *28*, 315–320. [\[CrossRef\]](#)
85. McNamara, A.L.; Dickerson, E.C.; Gomez-Hassan, D.M.; Cinti, S.K.; Srinivasan, A. Yield of Image-Guided Needle Biopsy for Infectious Discitis: A Systematic Review and Meta-Analysis. *Am. J. Neuroradiol.* **2017**, *38*, 2021–2027. [\[CrossRef\]](#)
86. Trampuz, A.; Piper, K.E.; Jacobson, M.J.; Hanssen, A.D.; Unni, K.K.; Osmon, D.R.; Mandrekar, J.N.; Cockerill, F.R.; Steckelberg, J.M.; Greenleaf, J.F.; et al. Sonication of removed hip and knee prostheses for diagnosis of infection. *N. Engl. J. Med.* **2007**, *357*, 654–663. [\[CrossRef\]](#) [\[PubMed\]](#)
87. Marschall, J.; Bhavan, K.P.; Olsen, M.A.; Fraser, V.G.; Wright, N.M.; Warren, D.K. The impact of prebiopsy antibiotics on pathogen recovery in hematogenous vertebral osteomyelitis. *Clin. Infect. Dis.* **2011**, *52*, 867–872. [\[CrossRef\]](#)
88. Charlier, C.; Perrodeau, E.; Leclercq, A.; Cazenave, B.; Pilmis, B.; Henry, B.; Lopes, A.; Maury, M.M.; Moura, A.; Lortholary, O.; et al. Clinical features and prognostic factors of listeriosis: The MONALISA national prospective cohort study. *Lancet Infect. Dis.* **2017**, *17*, 510–519. [\[CrossRef\]](#) [\[PubMed\]](#)
89. Merle-Melet, M.; Dossou-Gbete, L.; Maurer, P.; Meyer, P.; Lozniewski, A.; Kuntzburger, O.; Weber, M.; Gerard, A. Is amoxicillin-cotrimoxazole the most appropriate antibiotic regimen for listeria meningoencephalitis? Review of 22 cases and the literature. *J. Infect.* **1996**, *33*, 79–85. [\[CrossRef\]](#)
90. Louthrenoo, W.; Schumacher, H.R., Jr. *Listeria monocytogenes* osteomyelitis complicating leukemia: Report and literature review of *Listeria* osteoarticular infections. *J. Rheumatol.* **1990**, *17*, 107–110.
91. Del Pozo, J.L.; de la Garza, R.G.; de Rada, P.D.; Ornilla, E.; Yuste, J.R. *Listeria monocytogenes* septic arthritis in a patient treated with mycophenolate mofetil for polyarteritis nodosa: A case report and review of the literature. *Int. J. Infect. Dis.* **2013**, *17*, e132–e133. [\[CrossRef\]](#)
92. Kubota, T.; Mori, Y.; Yamada, G.; Cammack, I.; Shinohara, T.; Matsuzaka, S.; Hoshi, T. *Listeria monocytogenes* Ankle Osteomyelitis in a Patient with Rheumatoid Arthritis on Adalimumab: A Report and Literature Review of *Listeria monocytogenes* Osteomyelitis. *Intern. Med.* **2021**, *60*, 3171–3176. [\[CrossRef\]](#) [\[PubMed\]](#)
93. Adebolu, O.I.; Sommer, J.; Idowu, A.B.; Lao, N.; Riaz, T. Vertebral osteomyelitis and epidural abscess due to *Listeria monocytogenes*—Case report and review of literature. *J. Bone Jt. Infect.* **2022**, *7*, 75–79. [\[CrossRef\]](#) [\[PubMed\]](#)
94. Khan, K.M.; Pao, W.; Kendler, J. Epidural abscess and vertebral osteomyelitis caused by *Listeria monocytogenes*: Case report and literature review. *Scand. J. Infect. Dis.* **2001**, *33*, 714–716. [\[CrossRef\]](#) [\[PubMed\]](#)
95. Camp, C.; Luft, W.C. *Listeria monocytogenes* osteomyelitis. *Guthrie Bull.* **1973**, *43*, 32–38. [\[CrossRef\]](#)
96. Chirgwin, K.; Gleich, S. *Listeria monocytogenes* osteomyelitis. *Arch. Intern. Med.* **1989**, *149*, 931–932. [\[CrossRef\]](#) [\[PubMed\]](#)
97. Aubin, G.G.; Boutoille, D.; Bourcier, R.; Caillon, J.; Lepelletier, D.; Bémer, P.; Corvec, S. Unusual Case of Spondylodiscitis due to *Listeria monocytogenes*. *J. Bone Jt. Infect.* **2016**, *1*, 7–9. [\[CrossRef\]](#)
98. Hasan, T.; Chik, W.; Chen, S.; Kok, J. Successful treatment of *Listeria monocytogenes* prosthetic valve endocarditis using rifampicin and benzylpenicillin in combination with valve replacement. *JMM Case Rep.* **2017**, *4*, e005085. [\[CrossRef\]](#)
99. Duarte, F.; Moreira Pinto, S.; Trigo, A.C.; Guimaraes, F.; Pereira, R.; Neno, M.; Correia de Abreu, R.; Neves, I. A rare presentation of *Listeria monocytogenes* infection: Perianal abscess associated with lumbar spine osteitis. *IDCases* **2019**, *15*, e00488. [\[CrossRef\]](#)
100. Al Ohaly, R.; Ranganath, N.; Saffie, M.G.; Shroff, A. *Listeria* spondylodiscitis: An uncommon etiology of a common condition; a case report. *BMC Infect. Dis.* **2020**, *20*, 559. [\[CrossRef\]](#)

101. Bongiovanni, M.; Barda, B.; Martinetti Lucchini, G.; Gaia, V.; Merlani, G.; Bernasconi, E. Invasive Listeriosis in Southern Switzerland: A Local Problem That Is Actually Global. *Clin. Infect. Dis.* **2023**, *77*, 161–162. [\[CrossRef\]](#)
102. Berbari, E.F.; Kanj, S.S.; Kowalski, T.J.; Darouiche, R.O.; Widmer, A.F.; Schmitt, S.K.; Hendershot, E.F.; Holtom, P.D.; Huddleston, P.M., 3rd; Petermann, G.W.; et al. Infectious Diseases Society of America (IDSA) Clinical Practice Guidelines for the Diagnosis and Treatment of Native Vertebral Osteomyelitis in Adults. *Clin. Infect. Dis.* **2015**, *61*, e26–e46. [\[CrossRef\]](#)
103. Mylonakis, E.; Paliou, M.; Hohmann, E.L.; Calderwood, S.B.; Wing, E.J. Listeriosis during pregnancy: A case series and review of 222 cases. *Medicine* **2002**, *81*, 260–269. [\[CrossRef\]](#) [\[PubMed\]](#)
104. Charlier-Woerther, C.; Lecuit, M. Listeriosis and pregnancy. *Presse Med.* **2014**, *43*, 676–682. [\[CrossRef\]](#)
105. Kessler, S.L.; Dajani, A.S. Listeria meningitis in infants and children. *Pediatr. Infect. Dis. J.* **1990**, *9*, 61–63. [\[CrossRef\]](#)
106. Mylonakis, E.; Hohmann, E.L.; Calderwood, S.B. Central nervous system infection with *Listeria monocytogenes*. 33 years' experience at a general hospital and review of 776 episodes from the literature. *Medicine* **1998**, *77*, 313–336. [\[CrossRef\]](#) [\[PubMed\]](#)
107. Armstrong, R.W.; Fung, P.C. Brainstem encephalitis due to *Listeria monocytogenes*: Case report and review. *Clin. Infect. Dis.* **1993**, *16*, 689–702. [\[CrossRef\]](#) [\[PubMed\]](#)
108. Wei, P.; Bao, R.; Fan, Y. Brainstem encephalitis caused by *Listeria monocytogenes*. *Pathogens* **2020**, *9*, 715. [\[CrossRef\]](#)
109. Disson, O.; Lecuit, M. Targeting of the central nervous system by *Listeria monocytogenes*. *Virulence* **2012**, *3*, 213–221. [\[CrossRef\]](#)
110. Drevets, D.A.; Leenen, P.J.; Greenfield, R.A. Invasion of the central nervous system by intracellular bacteria. *Clin. Microbiol. Rev.* **2004**, *17*, 323–347. [\[CrossRef\]](#)
111. Join-Lambert, O.F.; Ezine, S.; Le Monnier, A.; Jaubert, F.; Okabe, M.; Berche, P.; Kayal, S. *Listeria monocytogenes*-infected bone marrow myeloid cells promote bacterial invasion of the central nervous system. *Cell. Microbiol.* **2005**, *7*, 167–180. [\[CrossRef\]](#)
112. Dramsi, S.; Lévi, S.; Triller, A.; Cossart, P. Entry of *Listeria monocytogenes* into neurons occurs by cell-to-cell spread: An in vitro study. *Infect. Immun.* **1998**, *66*, 4461–4468. [\[CrossRef\]](#) [\[PubMed\]](#)
113. Maudet, C.; Kheloufi, M.; Levallois, S.; Gaillard, J.; Huang, L.; Gaultier, C.; Tsai, Y.H.; Disson, O.; Lecuit, M. Bacterial inhibition of Fas-mediated killing promotes neuroinvasion and persistence. *Nature* **2022**, *603*, 900–906. [\[CrossRef\]](#) [\[PubMed\]](#)
114. Goulet, V.; Marchetti, P. Listeriosis in 225 non-pregnant patients in 1992, clinical aspects and outcome in relation to predisposing conditions. *Scand. J. Infect. Dis.* **1996**, *28*, 367–374. [\[CrossRef\]](#) [\[PubMed\]](#)
115. Rivero, G.A.; Torres, H.A.; Rolston, K.V.I.; Kontoyiannis, D.P. *Listeria monocytogenes* infection in patients with cancer. *Diagn. Microbiol. Infect. Dis.* **2003**, *47*, 393–398. [\[CrossRef\]](#) [\[PubMed\]](#)
116. Ooi, S.T.; Lorber, B. Gastroenteritis due to *Listeria monocytogenes*. *Clin. Infect. Dis.* **2005**, *40*, 1327–1332. [\[CrossRef\]](#)
117. Lorber, B. Listeriosis following shigellosis. *Rev. Infect. Dis.* **1991**, *13*, 865–866. [\[CrossRef\]](#) [\[PubMed\]](#)
118. Fernández Guerrero, M.L.; Rivas, P.; Rábago, R.; Núñez, A.; de Górgolas, M.; Martinell, J. Prosthetic valve endocarditis due to *Listeria monocytogenes*. Report of two cases and reviews. *Int. J. Infect. Dis.* **2004**, *8*, 97–102. [\[CrossRef\]](#)
119. Spyrou, N.; Anderson, M.; Foale, R. Listeria endocarditis: Current management and patient outcome: World literature review. *Heart* **1997**, *77*, 380–383. [\[CrossRef\]](#)
120. Kumaraswamy, M.; Do, C.; Sakoulas, G.; Nonejuie, P.; Tseng, G.W.; King, H.; Fierer, J.; Pogliano, J.; Nizet, V. *Listeria monocytogenes* endocarditis: Case report, review of the literature, and laboratory evaluation of potential novel antibiotic synergies. *Int. J. Antimicrob. Agents* **2018**, *51*, 468–478. [\[CrossRef\]](#)
121. Gauto, A.R.; Cone, L.A.; Woodard, D.R.; Mahler, R.J.; Lynch, R.D.; Stoltzman, D.H. Arterial infections due to *Listeria monocytogenes*: Report of four cases and review of world literature. *Clin. Infect. Dis.* **1992**, *14*, 23–28. [\[CrossRef\]](#)
122. Bourgeois, N.; Jacobs, F.; Tavares, M.L.; Rickaert, F.; Deprez, C.; Liesnard, C.; Moonens, F.; Van de Stadt, J.; Gelin, M.; Adler, M. *Listeria monocytogenes* hepatitis in a liver transplant recipient: A case report and review of the literature. *J. Hepatol.* **1993**, *18*, 284–289. [\[CrossRef\]](#)
123. Vargas, V.; Alemán, C.; de Torres, I.; Castells, L.; Gavalda, J.; Margarit, C.; Esteban, R.; Guardia, J. *Listeria monocytogenes*-associated acute hepatitis in a liver transplant recipient. *Liver* **1998**, *18*, 213–215. [\[CrossRef\]](#) [\[PubMed\]](#)
124. Braun, T.I.; Travis, D.; Dee, R.R.; Nieman, R.E. Liver abscess due to *Listeria monocytogenes*: Case report and review. *Clin. Infect. Dis.* **1993**, *17*, 267–269. [\[CrossRef\]](#) [\[PubMed\]](#)
125. Brönnimann, S.; Baer, H.U.; Malinverni, R.; Büchler, M.W. *Listeria monocytogenes* causing solitary liver abscess. Case report and review of the literature. *Dig. Surg.* **1998**, *15*, 364–368. [\[CrossRef\]](#) [\[PubMed\]](#)
126. Bruminhent, J.; Lynch, T.K.; Gefen, J.; Santoro, J. *Listeria monocytogenes* cholecystitis: A possible new syndrome. *Am. J. Med. Sci.* **2013**, *345*, 414–417. [\[CrossRef\]](#) [\[PubMed\]](#)
127. Charlier, C.; Fevre, C.; Travier, L.; Cazenave, B.; Bracq-Dieye, H.; Podevin, J.; Assomany, D.; Guilbert, L.; Bossard, C.; Carpentier, F.; et al. *Listeria monocytogenes*-associated biliary tract infections: A study of 12 consecutive cases and review. *Medicine* **2014**, *93*, e105. [\[CrossRef\]](#) [\[PubMed\]](#)
128. Sivalingam, J.J.; Martin, P.; Fraimow, H.S.; Yarze, J.C.; Friedman, L.S. *Listeria monocytogenes* peritonitis: Case report and literature review. *Am. J. Gastroenterol.* **1992**, *87*, 1839–1845.
129. Bierhoff, M.; Krutwagen, E.; van Bommel, E.F.H.; Verburgh, C.A. Listeria peritonitis in patients on peritoneal dialysis: Two cases and a review of the literature. *Neth. J. Med.* **2011**, *69*, 461–464.
130. Moscovici, A.; Kogan, M.; Kliens, I.; Kukuy, O.; Segal, G. Listeria peritonitis in a patient treated with peritoneal dialysis. *Isr. Med. Assoc. J.* **2016**, *18*, 129–130.

131. Jayaraj, K.; Di Bisceglie, A.M.; Gibson, S. Spontaneous bacterial peritonitis caused by infection with *Listeria monocytogenes*: A case report and review of the literature. *Am. J. Gastroenterol.* **1998**, *93*, 1556–1558. [[CrossRef](#)]
132. El Sayed Zaki, M.; El Shabrawy, W.O.; El-Eshmawy, M.M.; Aly Eletreby, S. The high prevalence of *Listeria monocytogenes* peritonitis in cirrhotic patients of an Egyptian medical center. *J. Infect. Public Health* **2011**, *4*, 211–216. [[CrossRef](#)] [[PubMed](#)]
133. Zelenik, K.; Avberšek, J.; Pate, M.; Lušicky, M.; Krt, B.; Ocepek, M.; Zdovc, I. Cutaneous listeriosis in a veterinarian with the evidence of zoonotic transmission: A case report. *Zoonoses Public Health* **2014**, *61*, 238–241. [[CrossRef](#)]
134. Godshall, C.E.; Suh, G.; Lorber, B. Cutaneous listeriosis. *J. Clin. Microbiol.* **2013**, *51*, 3591–3596. [[CrossRef](#)] [[PubMed](#)]
135. Hof, H. *Listeria* infections of the eye. *Eur. J. Ophthalmol.* **2017**, *27*, 115–121. [[CrossRef](#)] [[PubMed](#)]

Disclaimer/Publisher’s Note: The statements, opinions and data contained in all publications are solely those of the individual author(s) and contributor(s) and not of MDPI and/or the editor(s). MDPI and/or the editor(s) disclaim responsibility for any injury to people or property resulting from any ideas, methods, instructions or products referred to in the content.