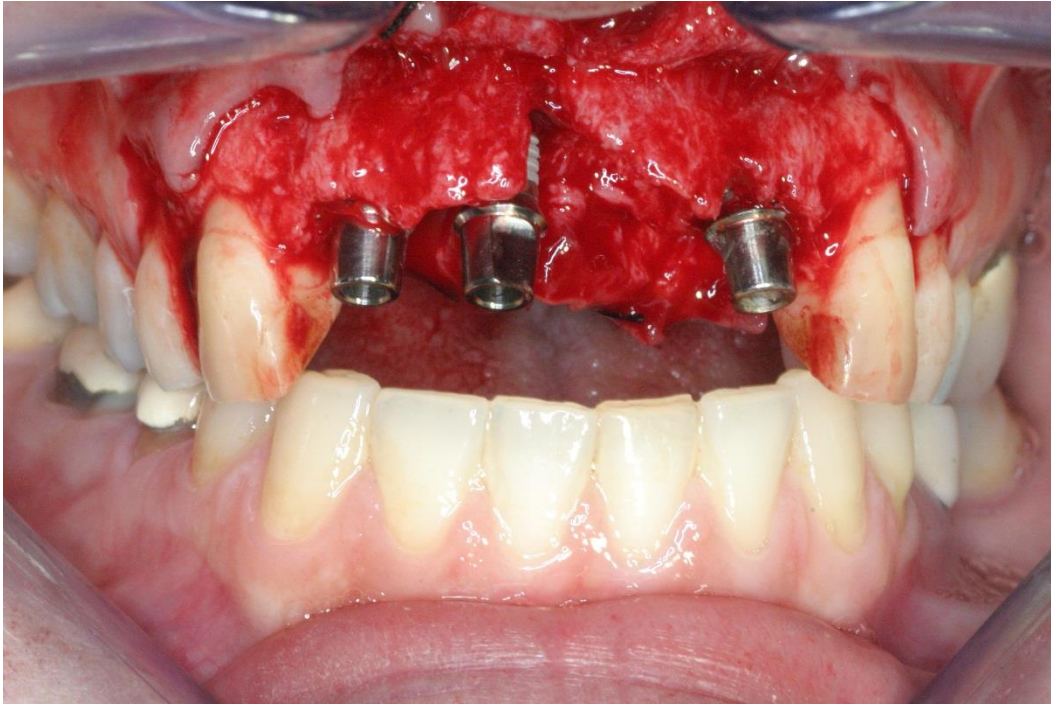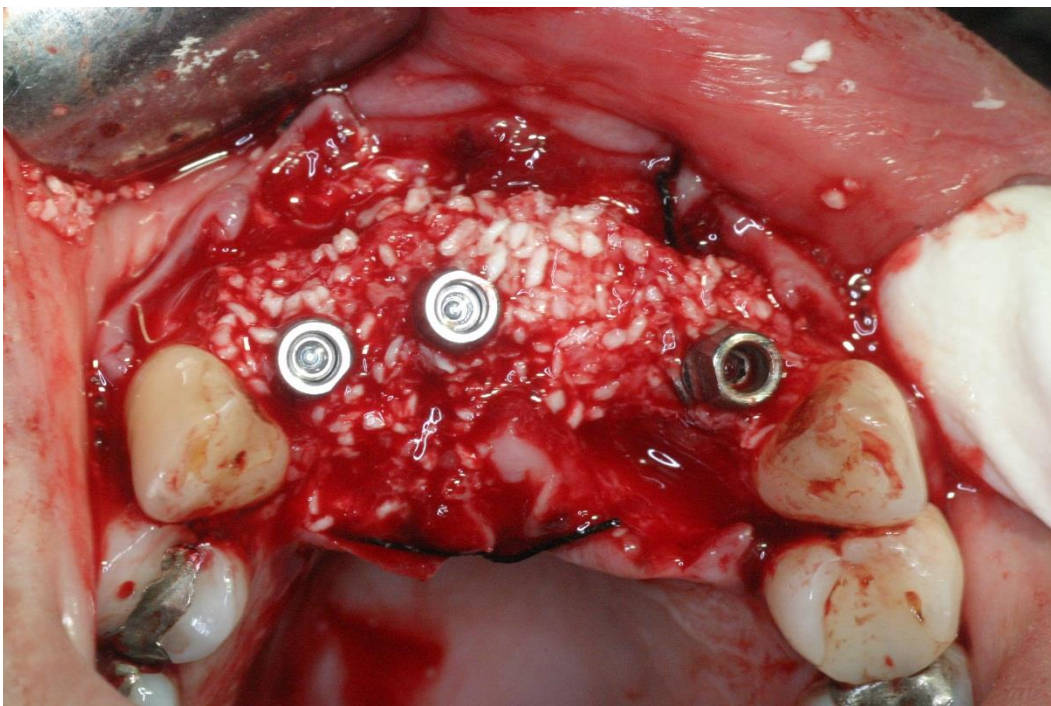
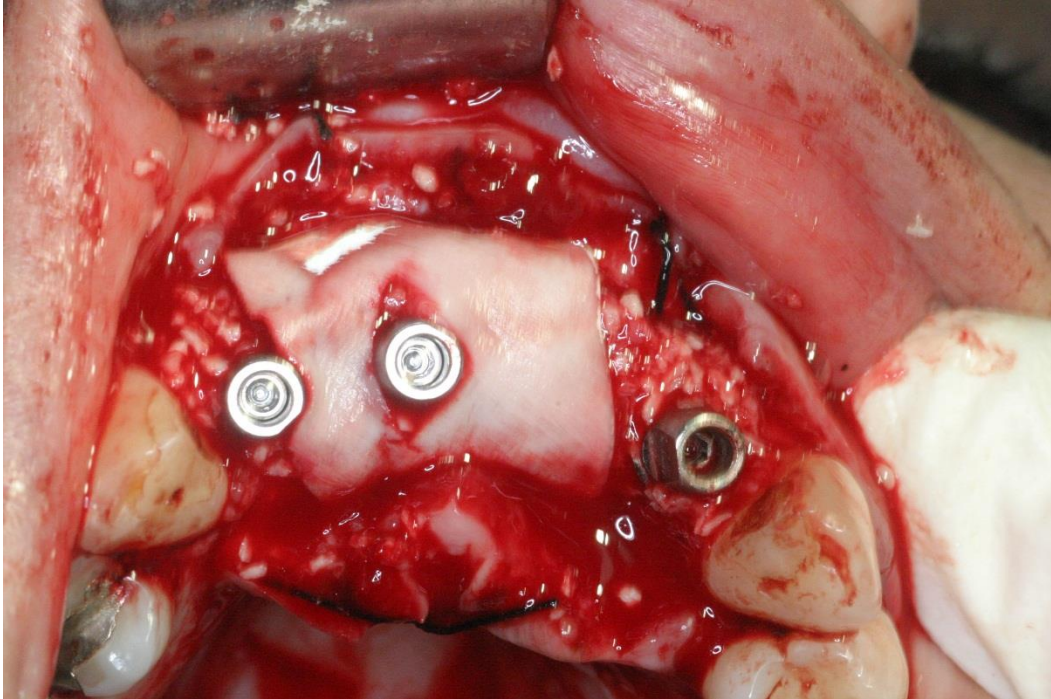


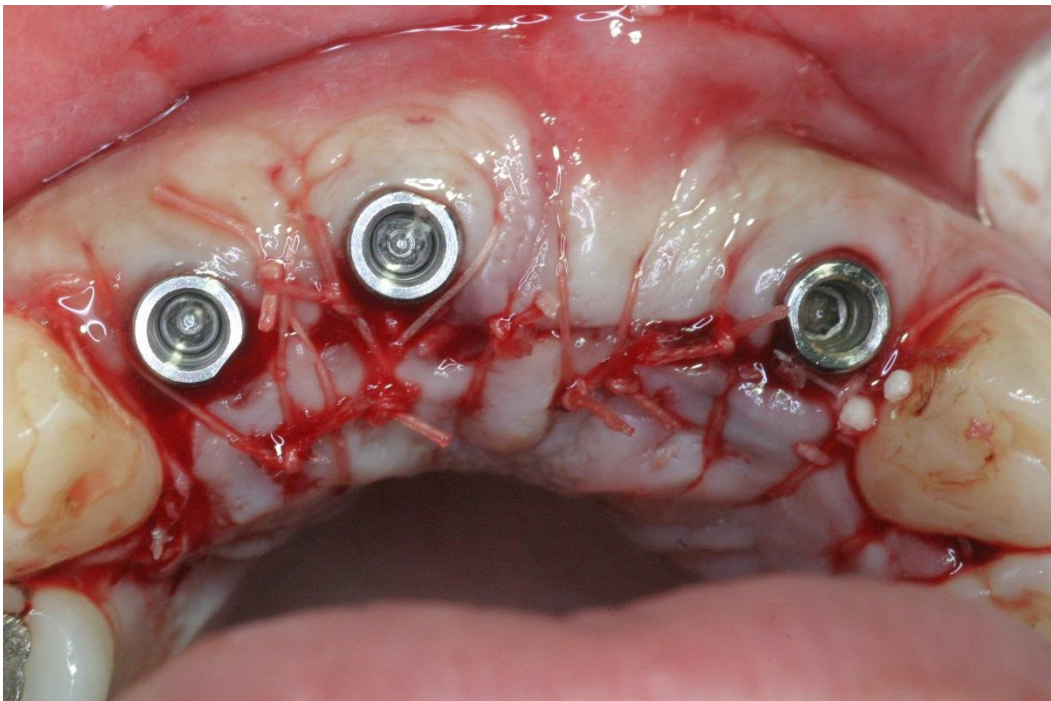**Figure S1** The buccal neck of the implant is at least 2 mm palatal to the buccal contour of the neighboring teeth. The neck of the implant was flush with the palatal bone in an apico-coronal direction.



**Figure S2** Allograft material was applied in the residual gap and above the buccal wall.



**Figure S3** A resorbable collagen membrane was applied after adaptation of an appropriate transfer abutment.



**Figure S4** A coronally positioned flap was performed after a periosteal releasing incision.