

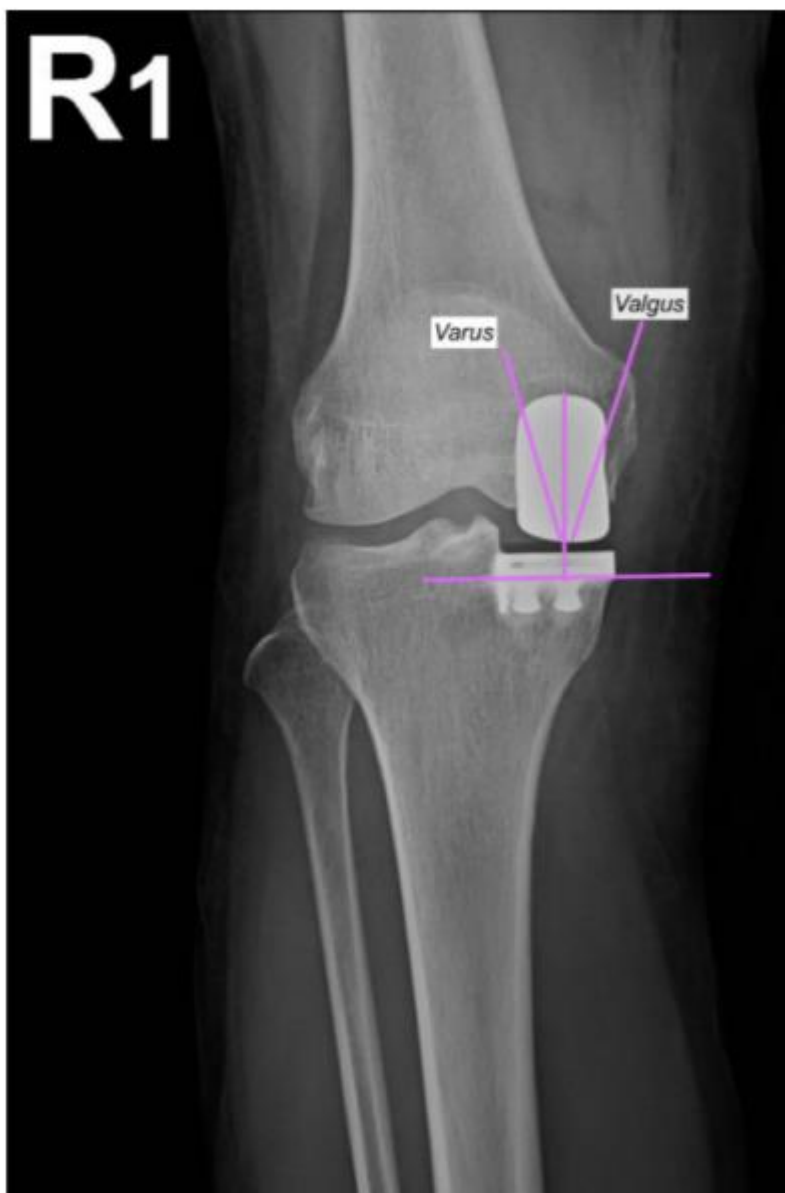

Figure S1. Assessment of the implant alignment grossly based on the radiograph

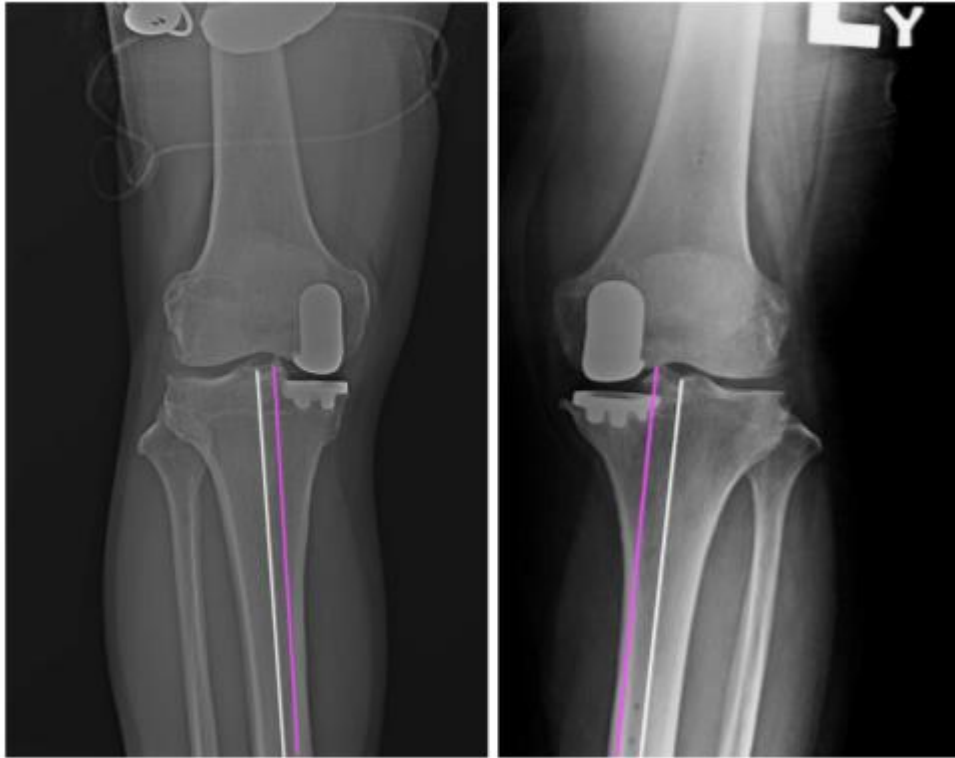


Figure S2. Assessment for the preservation of tibial eminence based on the radiograph

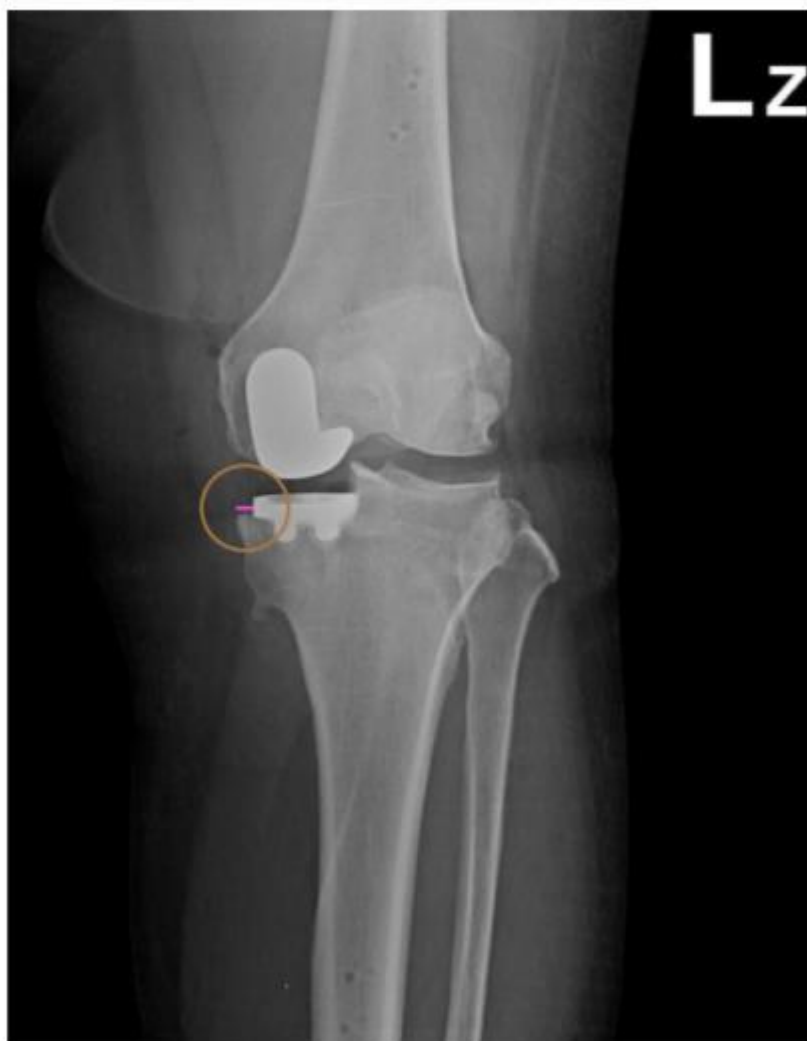

Figure S3. Assessment of the implant positioning as overhang or normal.