









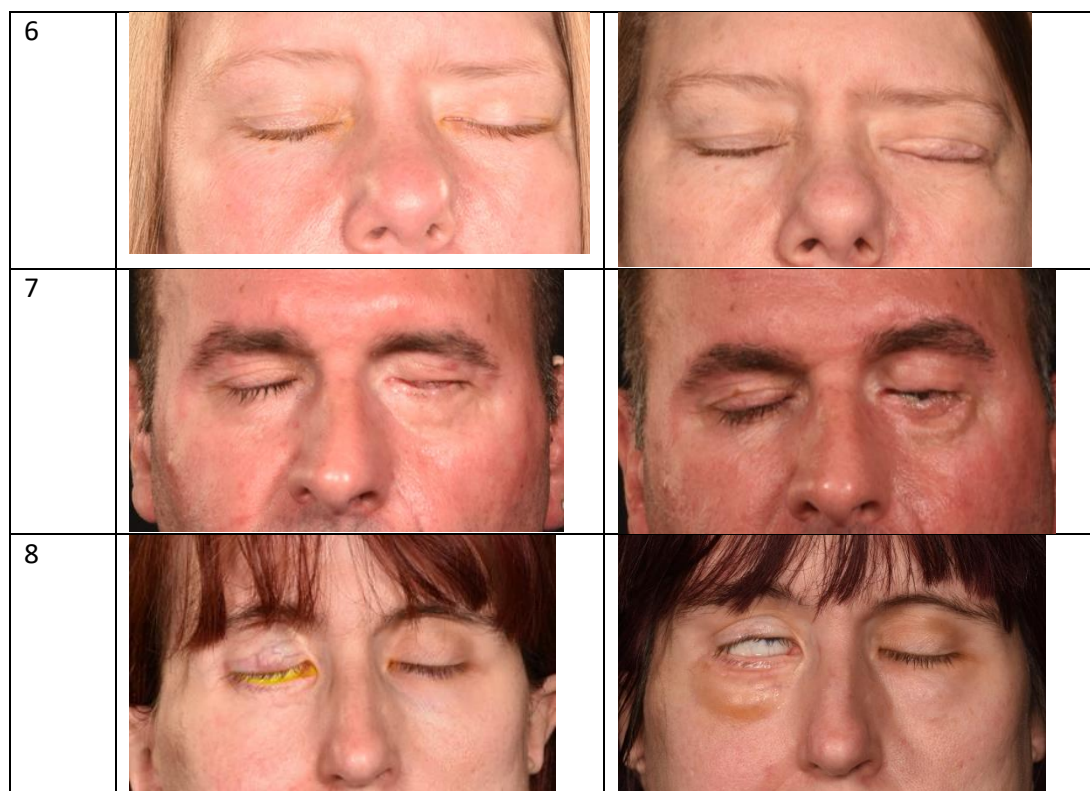

Case	Preoperative	Late Postoperative
1		
2		
3		
4		
5		



Supplement Figure S1:

Standardized photographs with gentle eye closure in eight consecutive young adults with facial nerve palsy (P1–P8) at pre-skin grafting and late postoperative follow-up.