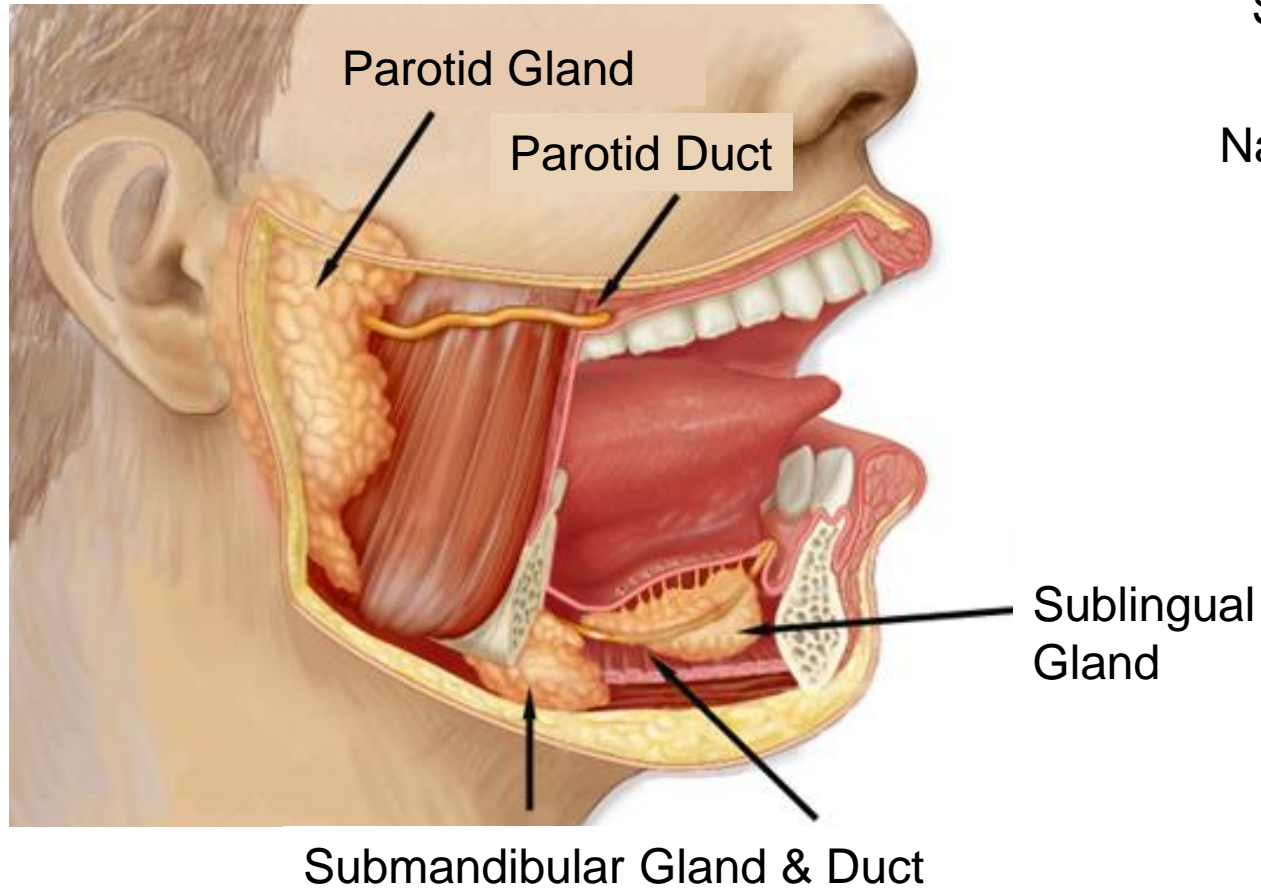
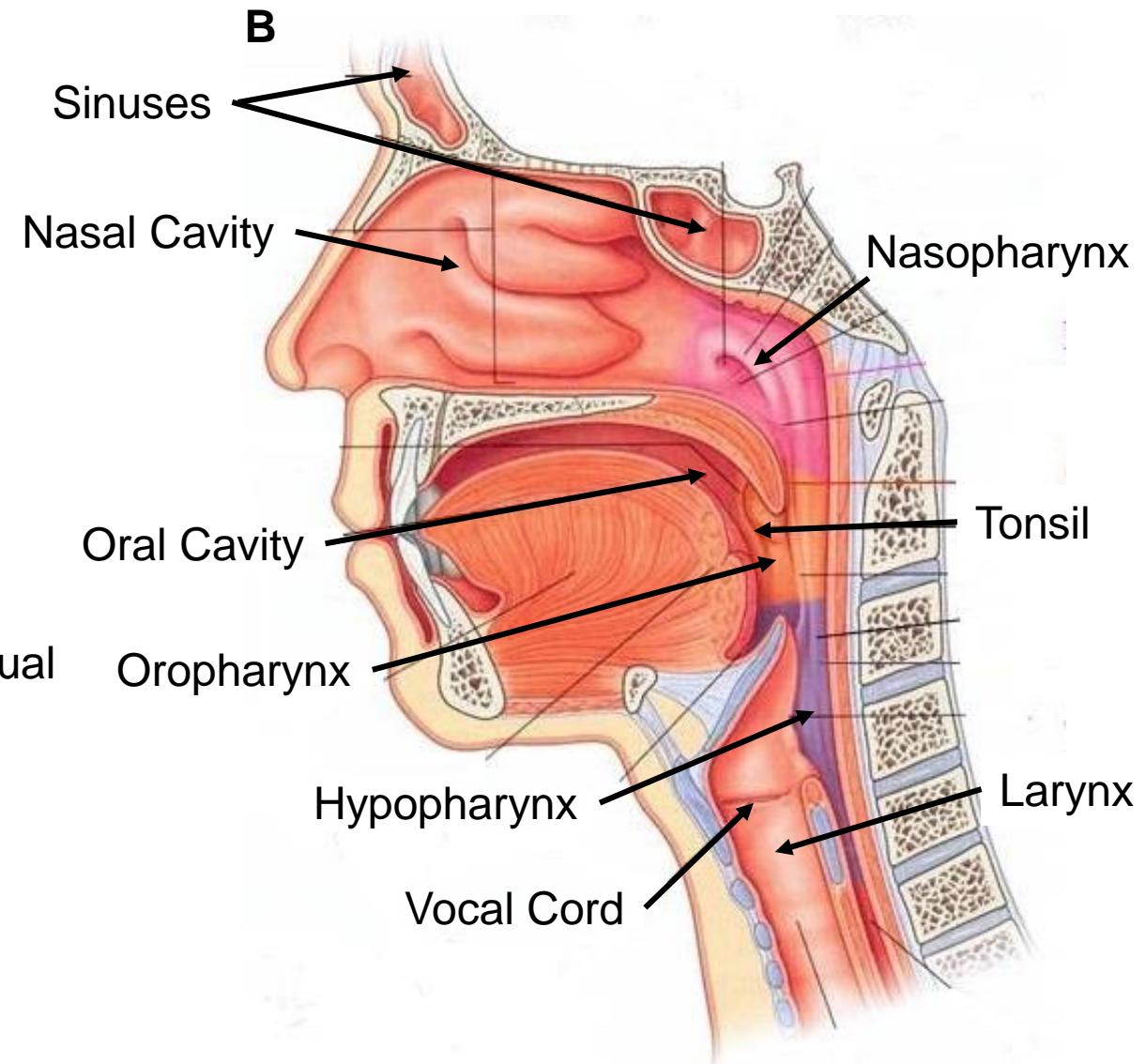


A**B**

Supplementary Figure 1: Anatomical description and location of salivary glands (A) and head and neck structures (B). Schemes were obtained from <https://www.parotidsurgerymd.com/> (A) and from Gray's Anatomy 2nd Edition, Elsevier 2010 (B)