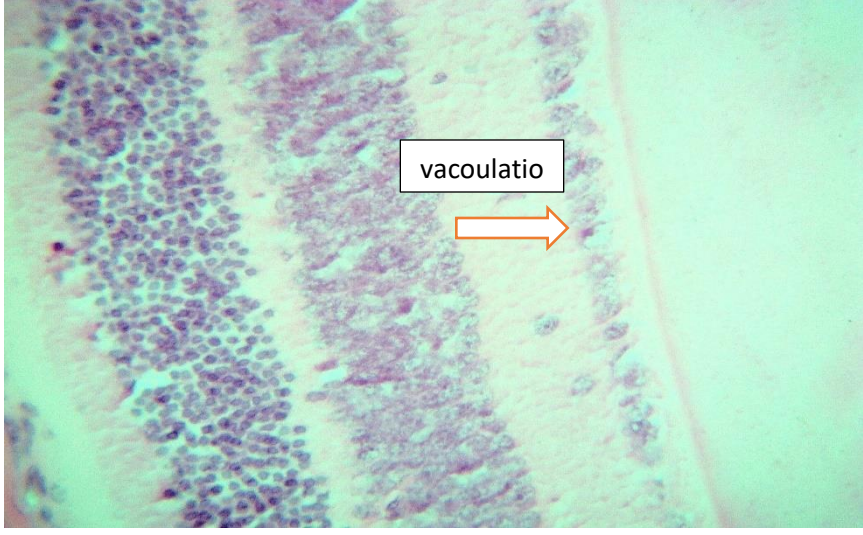
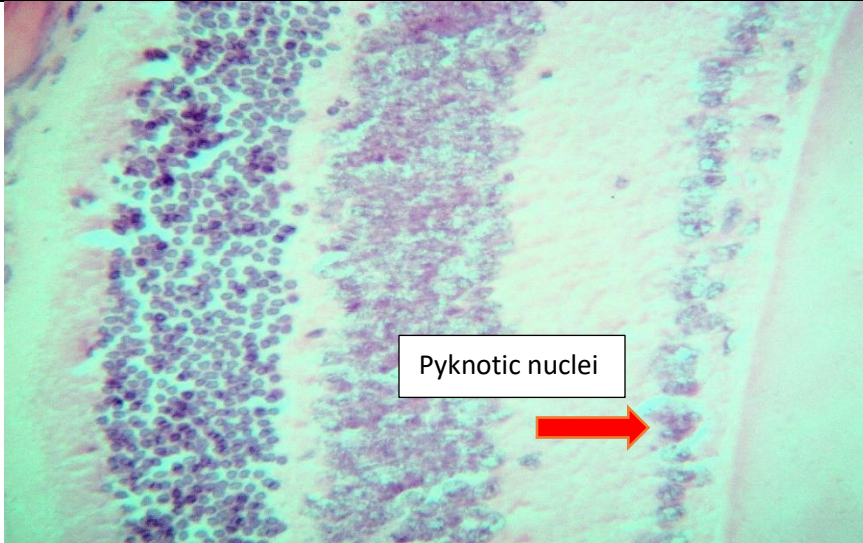


A	 <p>Micrograph A shows a histological section of tissue at 400x magnification. The ganglion cell layer is disorganized, and there is visible vacuolation. An orange arrow points to a specific area of vacuolation, which is labeled with a text box containing the word "vacoulatio".</p>	
B	 <p>Micrograph B shows a histological section of tissue at 400x magnification. The ganglion cell layer is disorganized, and there are visible pyknotic nuclei. A red arrow points to a specific area of pyknotic nuclei, which is labeled with a text box containing the words "Pyknotic nuclei".</p>	
	<p>Supplementary 1. Image shows disorganized ganglion cell layer and vacuolation (panel A) and pyknotic nuclei (panel B) at high power (400x).</p>	