

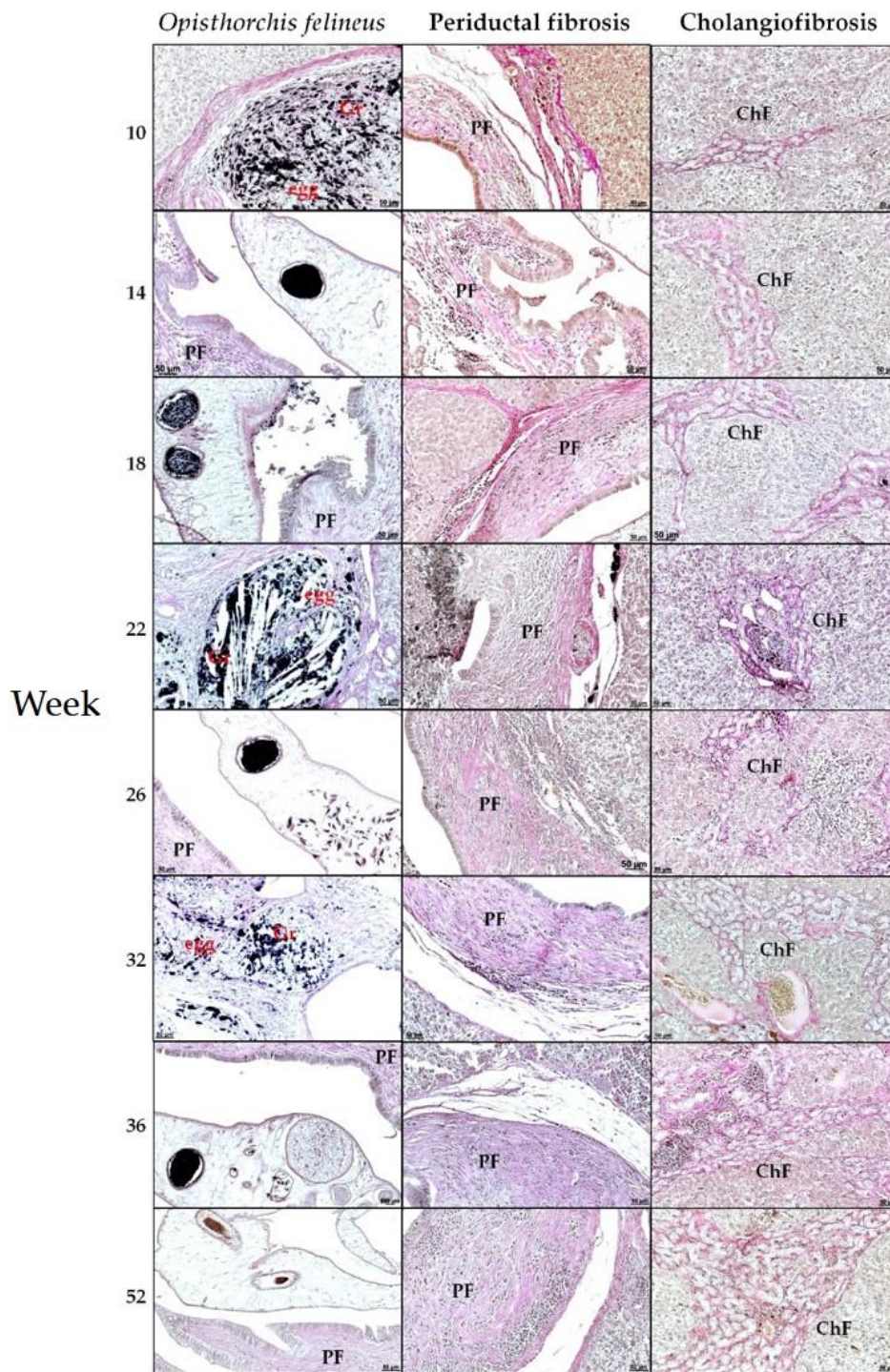Figure S1: Histopathological changes in Syrian hamster liver, Van Gieson staining. OF – *Opisthorchis felineus*, Gr – granuloma, egg – *O. felineus* egg into granuloma, PF – periductal fibrosis, ChF – cholangiofibrosis. Magnification x200.

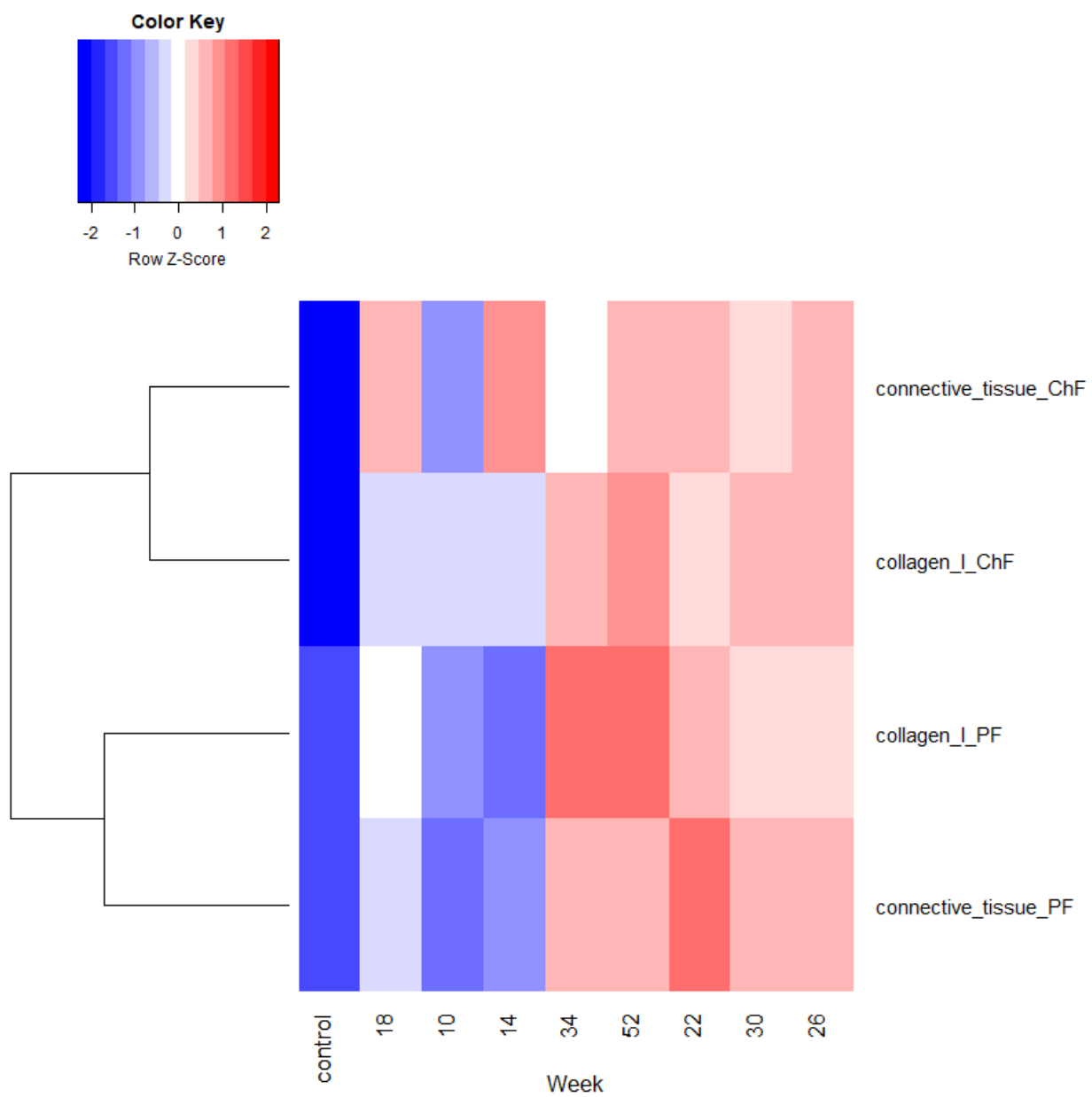


Figure S2: Clustering analysis of periductal and cholangiofibrosis with type I collagen.

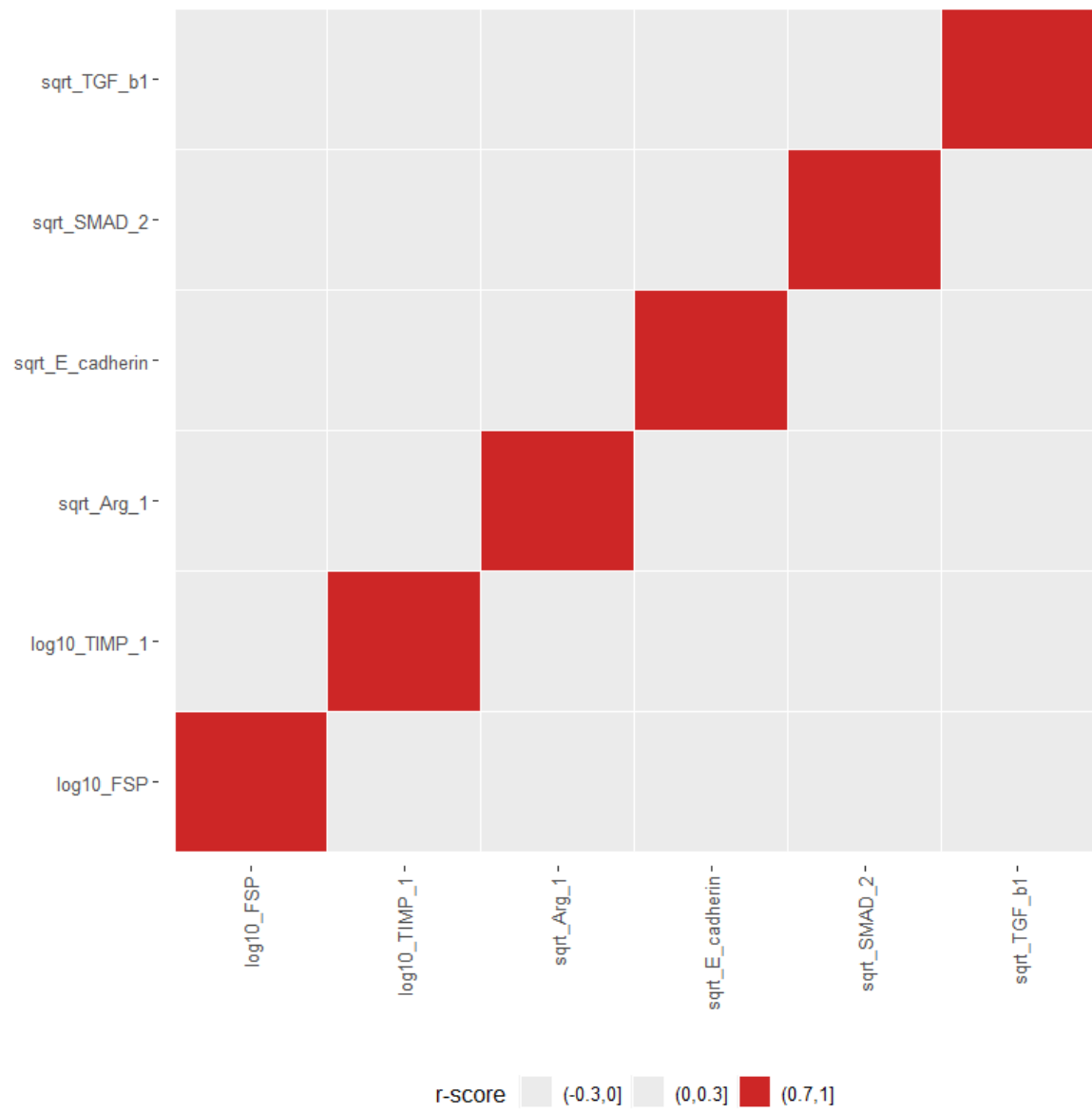


Figure S3: Calculation of parametric criterion Pearson correlation.

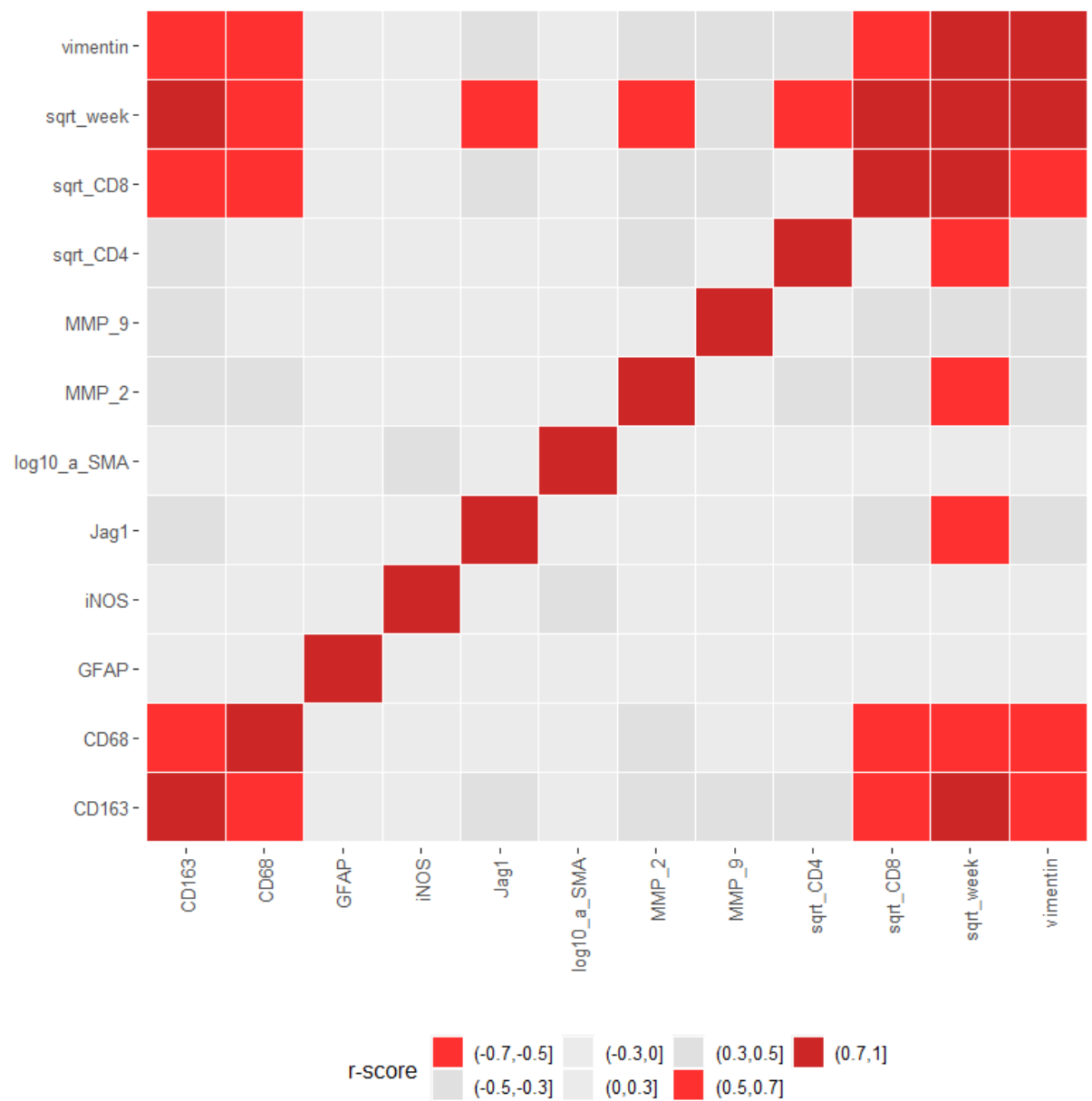


Figure S4: Calculation of non-parametric criterion Spearman correlation.