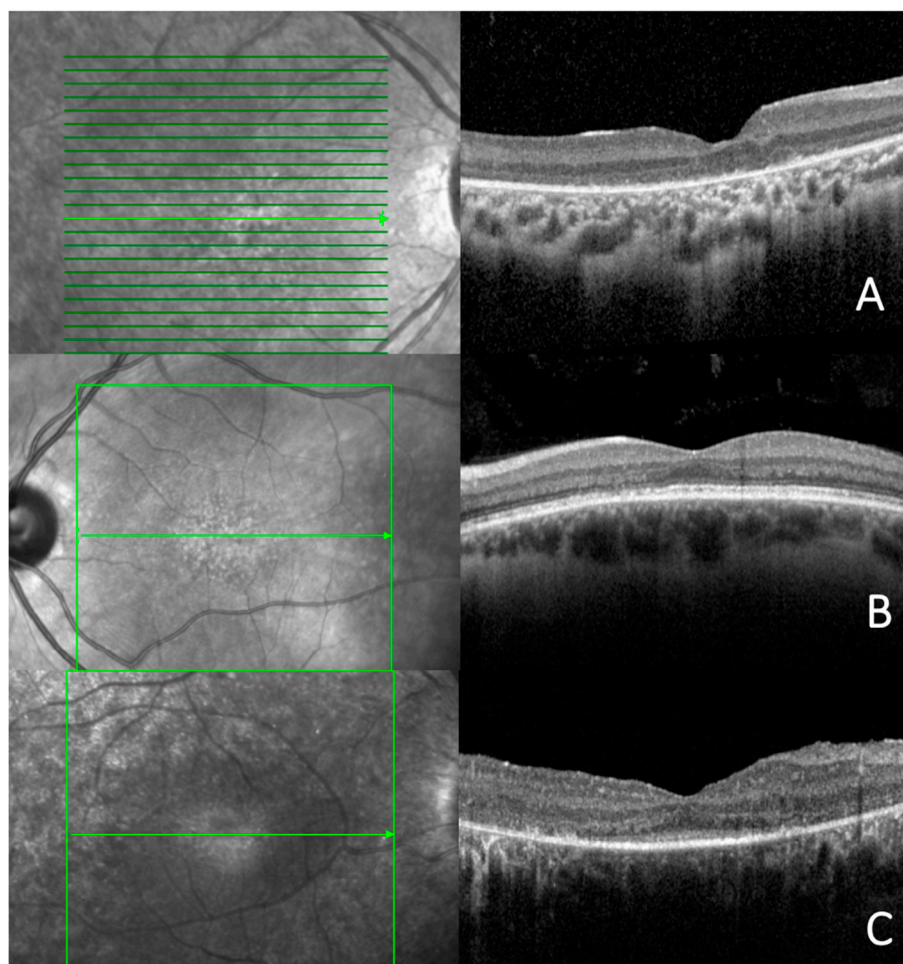


## Supplemental Material



**Supplemental Figure S1.** Multimodal imaging in representative patients with FH.  
(A) Grade 1a FH (B) Grade 1b FH (C) Grade 1b FH.