

Supplementary material: Non-invasive prediction of *IDH* mutation in patients with glioma WHO II/III/IV based on F-18-FET PET-guided *in vivo* ¹H-magnetic resonance spectroscopy and machine learning

Elisabeth Bumes^{1*#}, Fro-Philip Wirtz^{2#}, Claudia Fellner³, Jirka Grosse⁴, Dirk Hellwig⁴, Peter J. Oefner², Martina Häckl², Ralf Linker¹, Martin Proescholdt⁵, Nils Ole Schmidt⁵, Markus J. Riemenschneider⁶, Claudia Samol², Katharina Rosengarth⁵, Christina Wendl³, Peter Hau¹, Wolfram Gronwald²⁺, Markus Hutterer^{1,6+}

¹Department of Neurology and Wilhelm Sander-NeuroOncology Unit, Regensburg University Hospital, Regensburg, Germany

²Institute of Functional Genomics, University of Regensburg, Regensburg, Germany

³Department of Radiology and Division of Neuroradiology, Regensburg University Hospital, Regensburg, Germany

⁴Department of Nuclear Medicine, Regensburg University Hospital, Regensburg, Germany

⁵Department of Neurosurgery, Regensburg University Hospital, Regensburg, Germany

⁶Department of Neuropathology, Regensburg University Hospital, Regensburg, Germany

⁷Department of Neurology, Saint John of God Hospital Linz, Linz, Austria

[#]shared first authorship, ⁺shared last authorship

*Correspondence: elisabeth.bumes@ukr.de; Tel.: +0049-0941-944-18751

Supplementary Material: Figure S1

CONSORT Flow Diagram

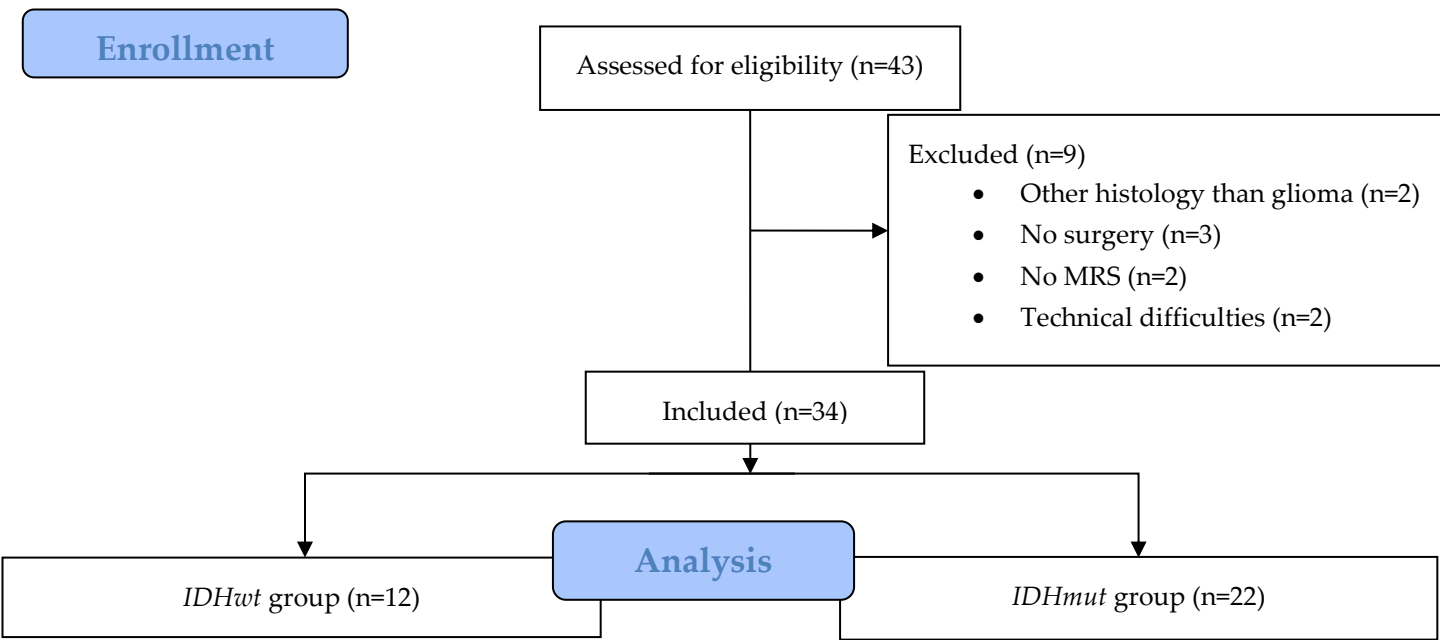


Figure S1: Consort flow diagram showing the patient enrollment.

Supplementary Material: Figure S2

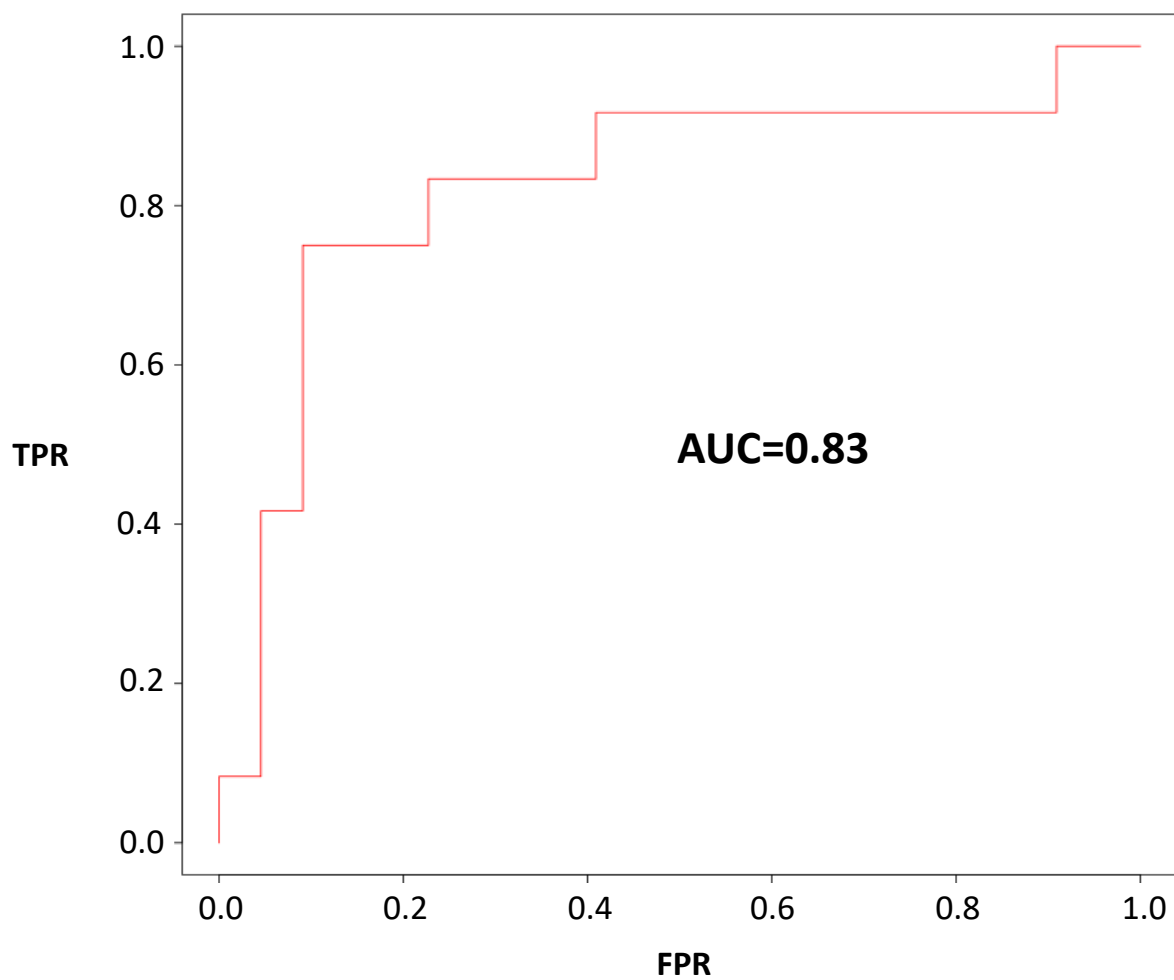


Figure S2. Prognostication of IDH status by linear SVM. Prognostication performance was assessed by analysis of the ROC curve.