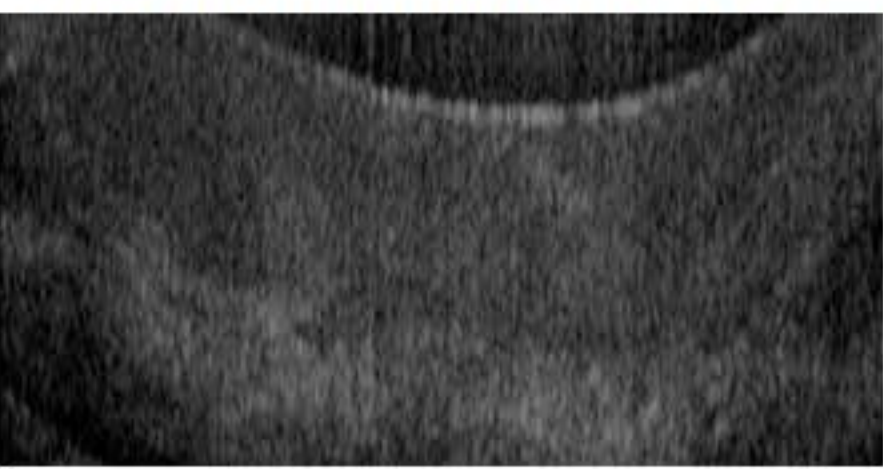
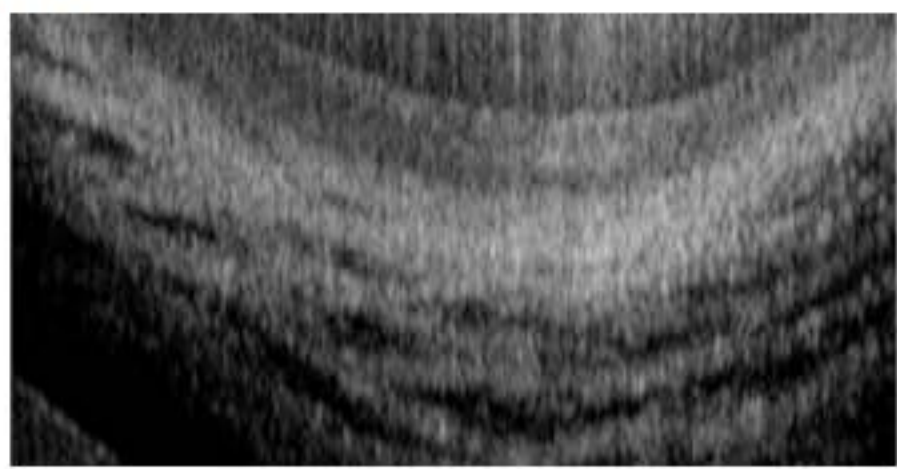


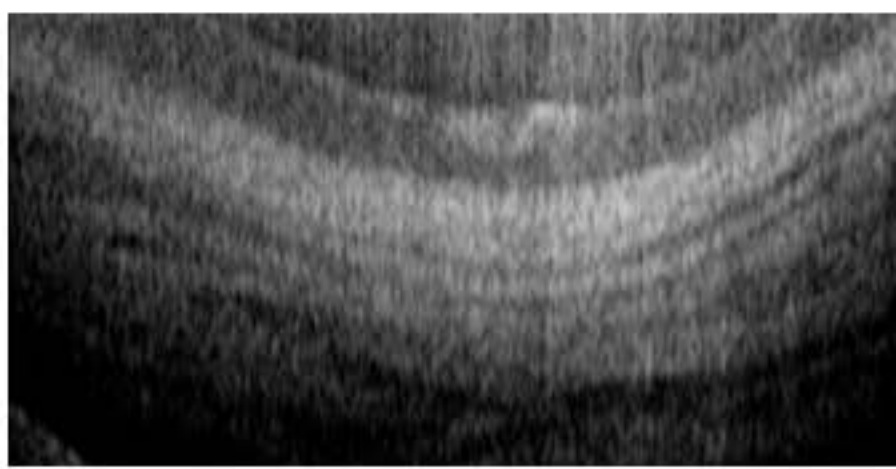
A. Normal oral mucosal sub-sites



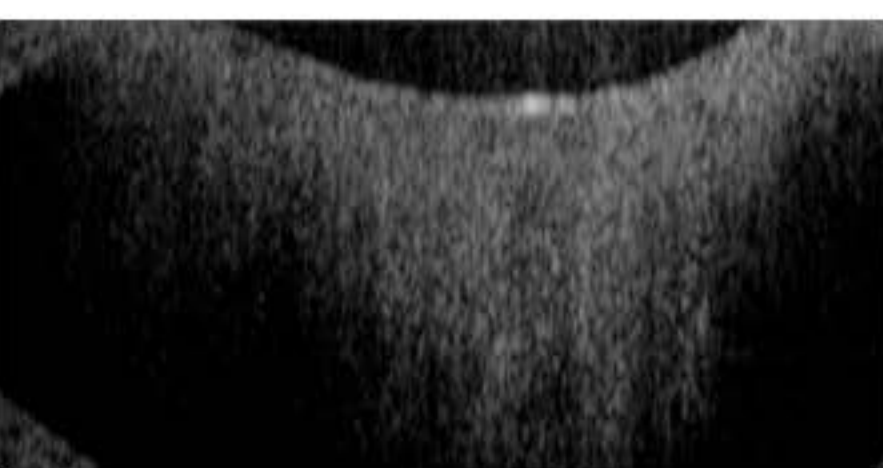
Buccal mucosa



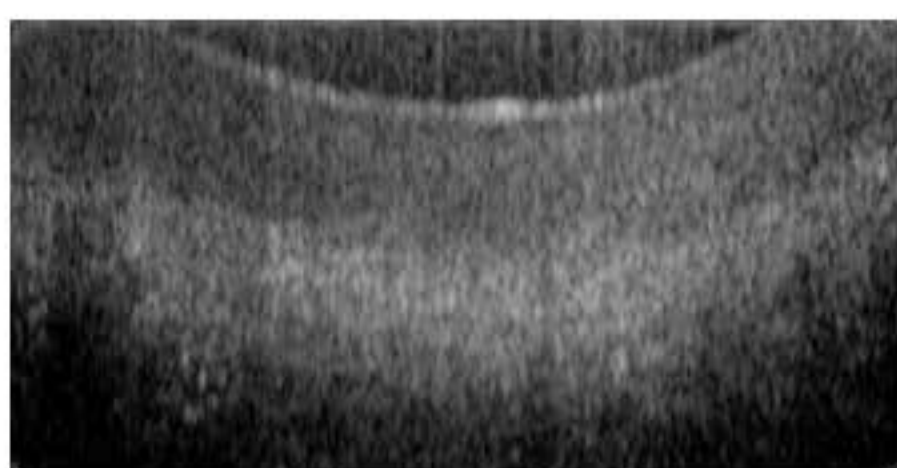
Floor of the mouth



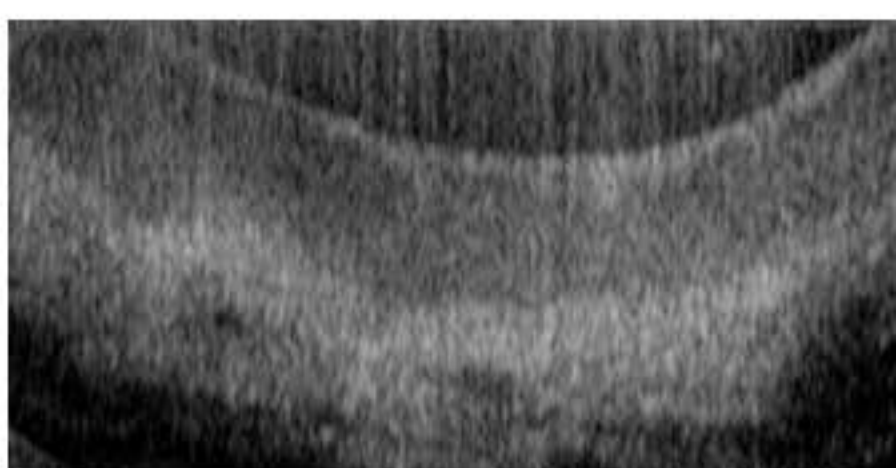
Gingiva



Dorsal Tongue

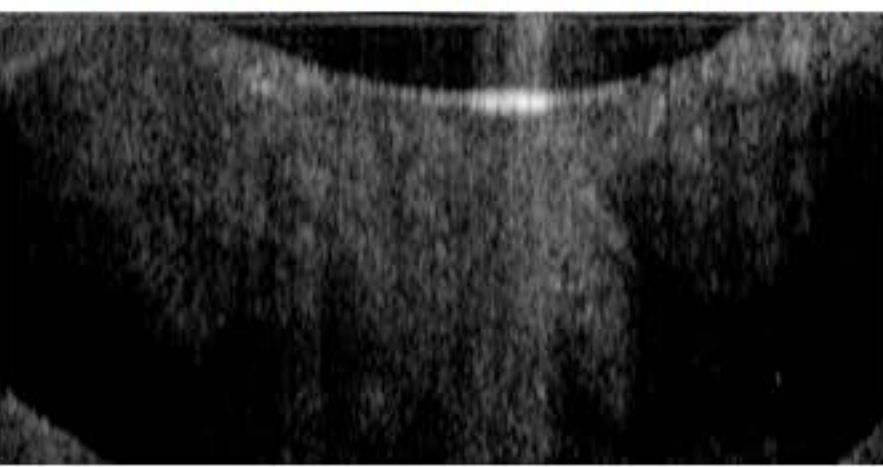


Ventral Tongue

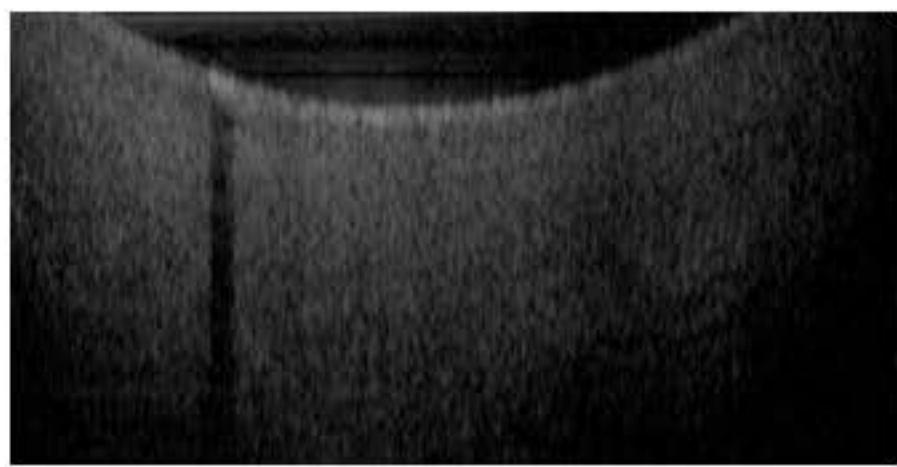


Retro-molar trigone

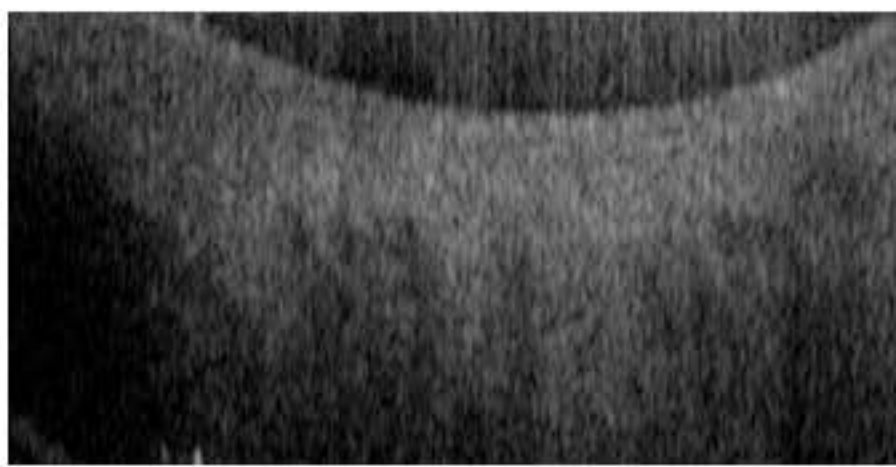
B. Multiple tongue lesions



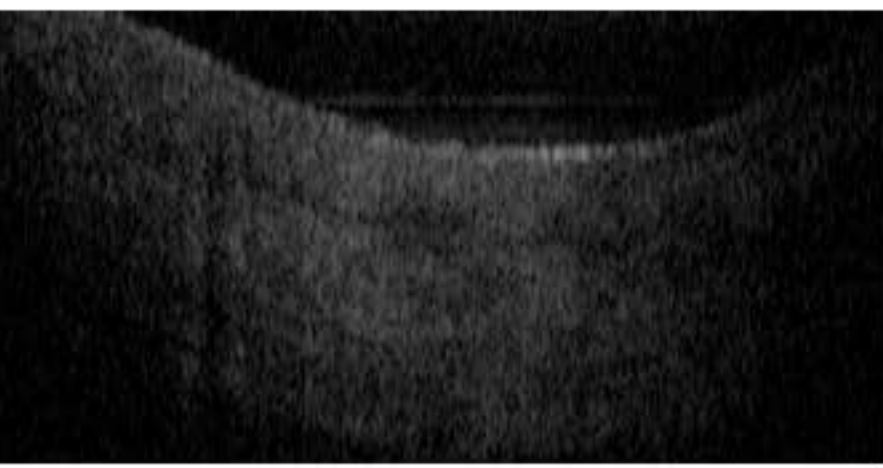
Normal



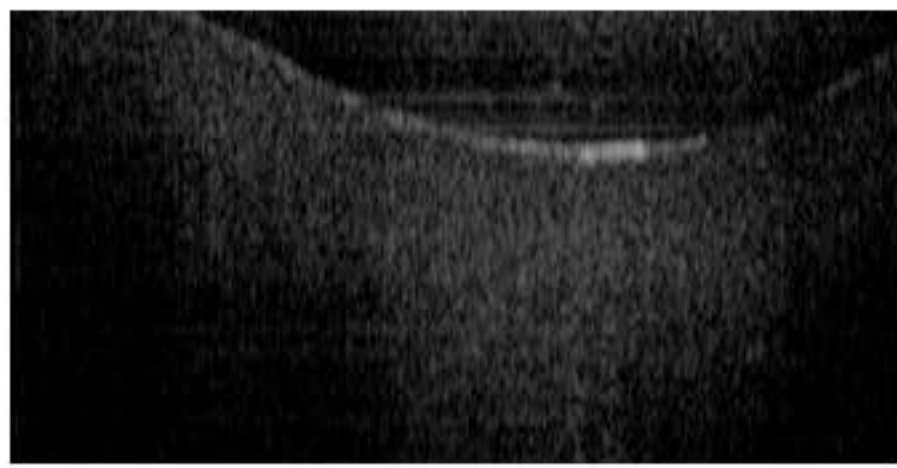
Aphthous ulcer



Lichen Planus



Dysplasia



OSCC