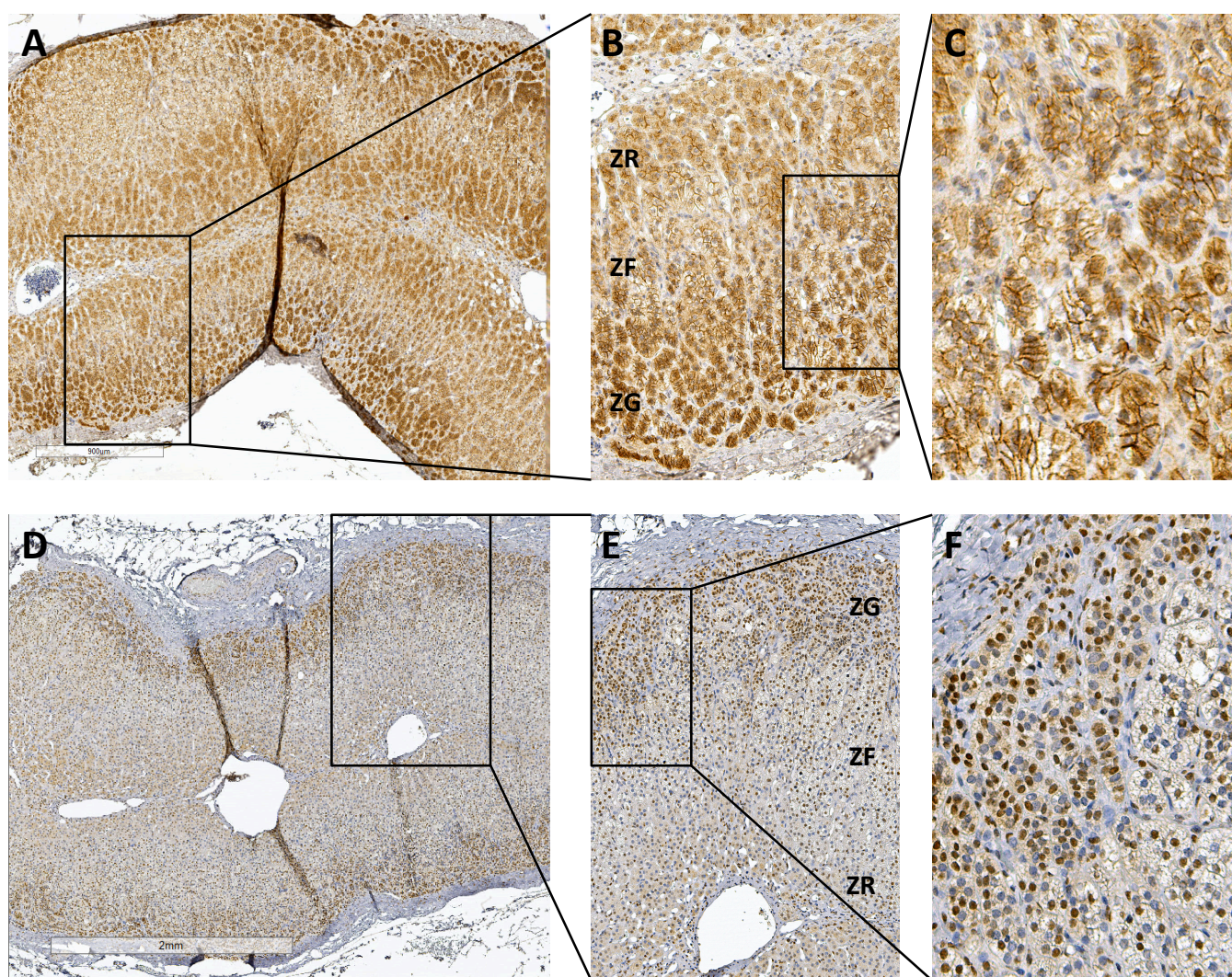


Supplementary information

Epithelial and mesenchymal markers in adrenocortical tissues: how mesenchymal are adrenocortical tissues?

Iuliu Sbiera¹, Stefan Kircher², Barbara Altieri¹, Martin Fassnacht^{1,3,4}, Matthias Kroiss^{1,4,5}, Silviu Sbiera¹

¹ Department of Internal Medicine I, Division of Endocrinology and Diabetes, University Hospital Würzburg, 97080 Würzburg, Germany; ² Institute for Pathology, University of Würzburg, 97080 Würzburg, Germany; ³ Clinical Chemistry and Laboratory Medicine, University Hospital Würzburg, 97080 Würzburg, Germany; ⁴ Comprehensive Cancer Center Mainfranken, University of Würzburg, 97080 Würzburg, Germany; ⁵ Department of Internal Medicine IV, University Hospital Munich, Ludwig-Maximilians-Universität München, 80336 Munich, Germany



Supplementary Figure 1. Expression of canonical immunohistochemical mesenchymal markers in normal adrenal gland. Staining of mesenchymal markers N-cadherin (A, B and C) and SLUG (D, E and F) in normal adrenal gland. Overview of the middle section of a normal adrenal gland (A and D) with zoom in a representative region (B and E) containing all three functional zones of the adrenal gland (ZG= zona glomerulosa, ZF= zona fasciculata and ZR= zona reticularis) and further zoom to visualize staining subcellular localization in C and F, respectively.