

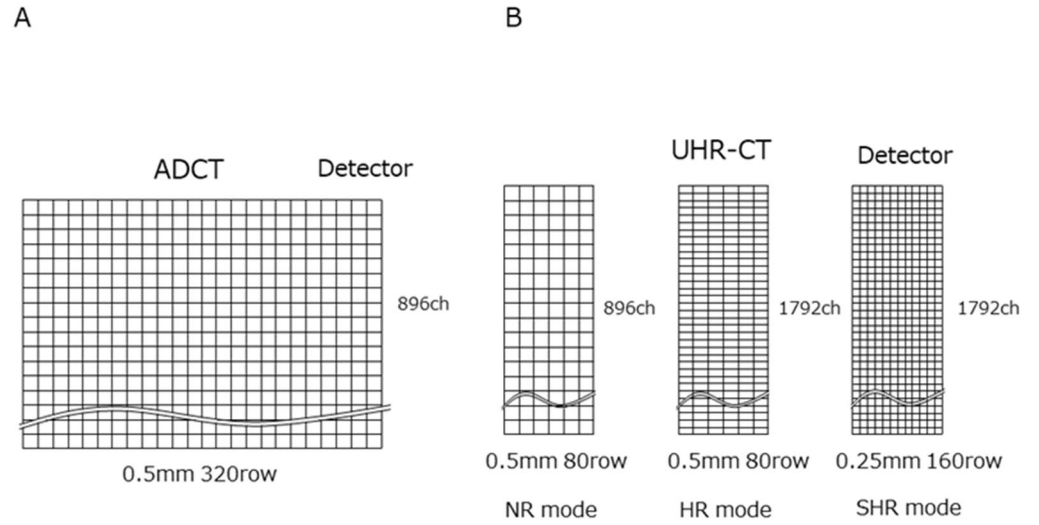Figure S1. Schematic demonstrating the difference in detector architecture between ultra-high-resolution computed tomography (CT) and area-detector CT. **(A)** Overview of the area-detector CT detector. **(B)** Overview of the ultra-high-resolution CT detector and scan mode.

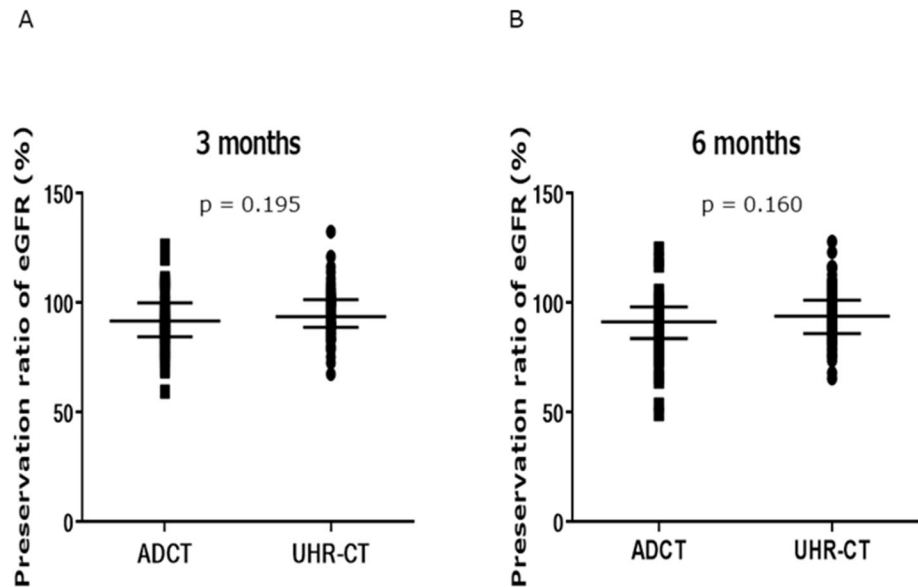


Figure S2. Preservation ratio of postoperative eGFR at 3 or 6 months (ADCT vs. UHR-CT, median with interquartile range). ADCT, area-detector computed tomography; UHR-CT, ultra-high-resolution computed tomography.