

Supplementary Materials

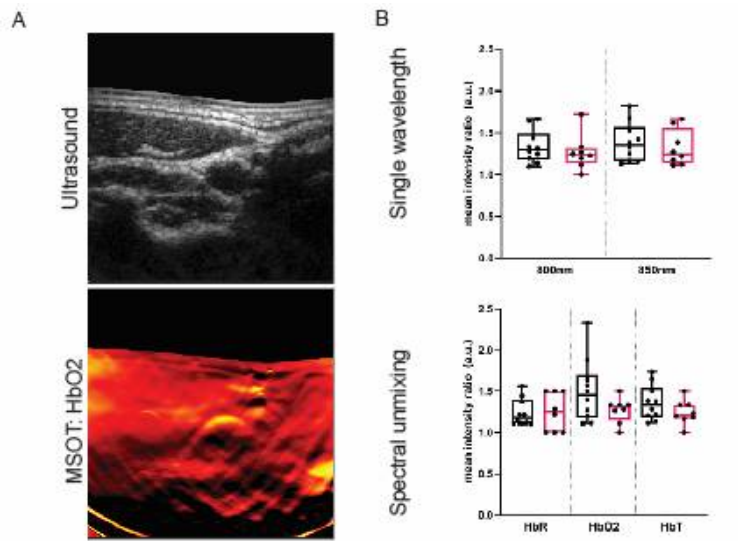


Figure S1: Healthy Volunteer Imaging. Representative image of intact bevacizumab-800CW at 150 kD. SDS-PAGE was performed on a fresh frozen tissue slice of a carotid surgical specimen collected directly after carotid endarterectomy.

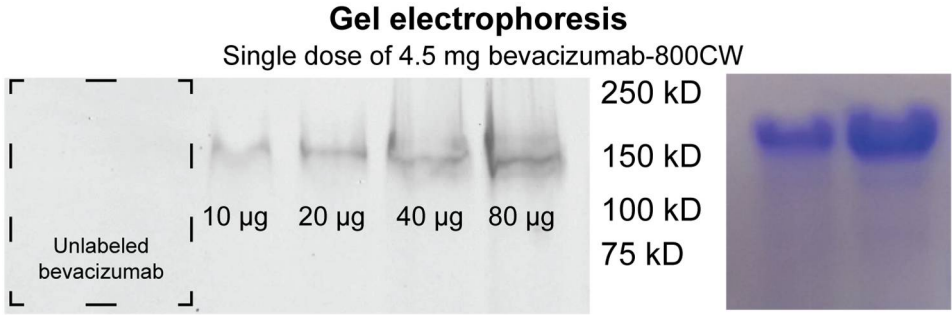


Figure S2: Gel electrophoresis. Representative image of healthy volunteer carotid artery imaging.