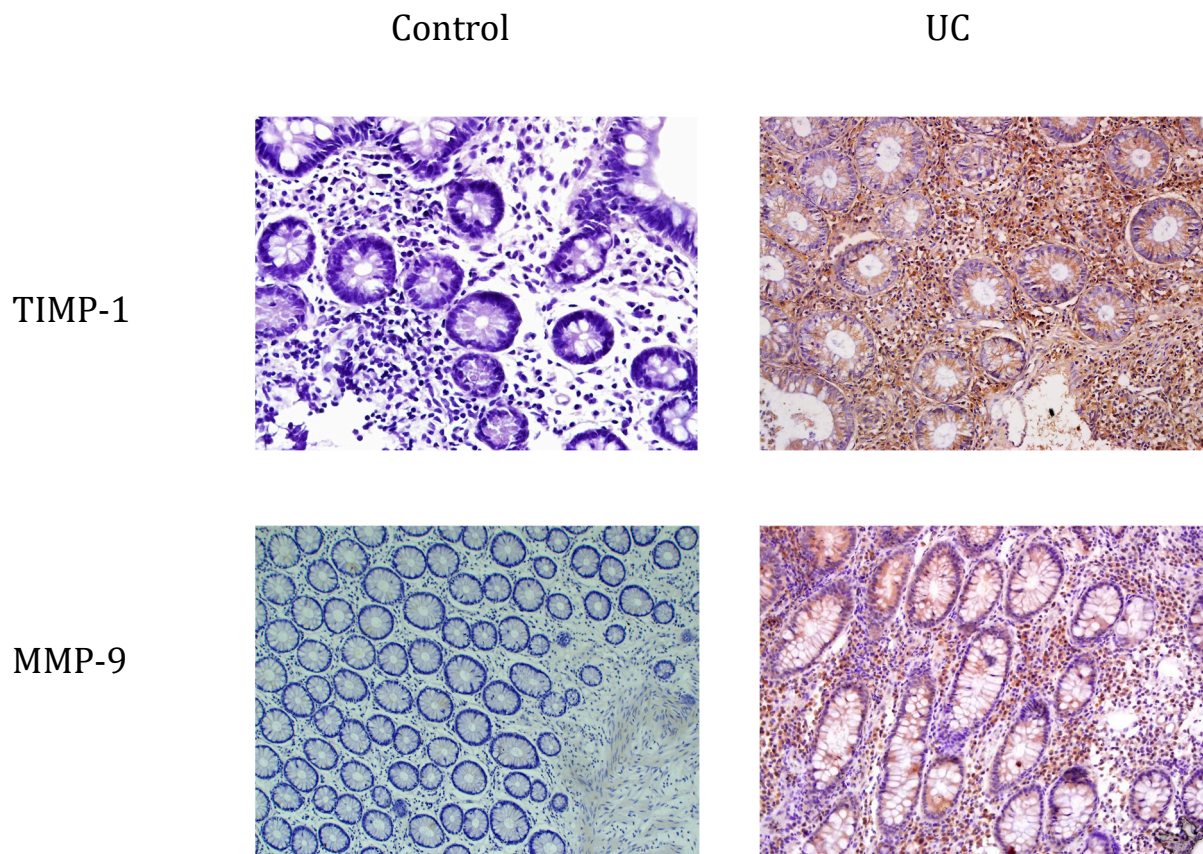


**Table S1.** Immunohistochemical staining of MMP-9 and TIMP-1 in biopsy samples of patients with Colitis Ulcerosa (CU) and control Group (Ctr).

	MMP-9 Staining				TIMP-1 Staining			
	Intensity	Extent	Sum score	Expression in glandular epithelium	Intensity	Extent	Sum score	Expression in glandular epithelium
CU	2 (1-3)	4 (1-4)	6 (2-7)	70% (20-100%)	3 (1-3)	4 (2-4)	7 (3-7)	100% (30-100%)
Ctr	0.5 (0-1)	0.5 (0-1)	1 (0-2)	1.5% (0-10%)	0 (0-1)	0 (0-5)	0 (0-2)	0% (0-5%)



**Figure S1:** Immunohistochemical staining showing mucosal expression of TIMP-1 and MMP-9 in UC and Control group