

Supplementary

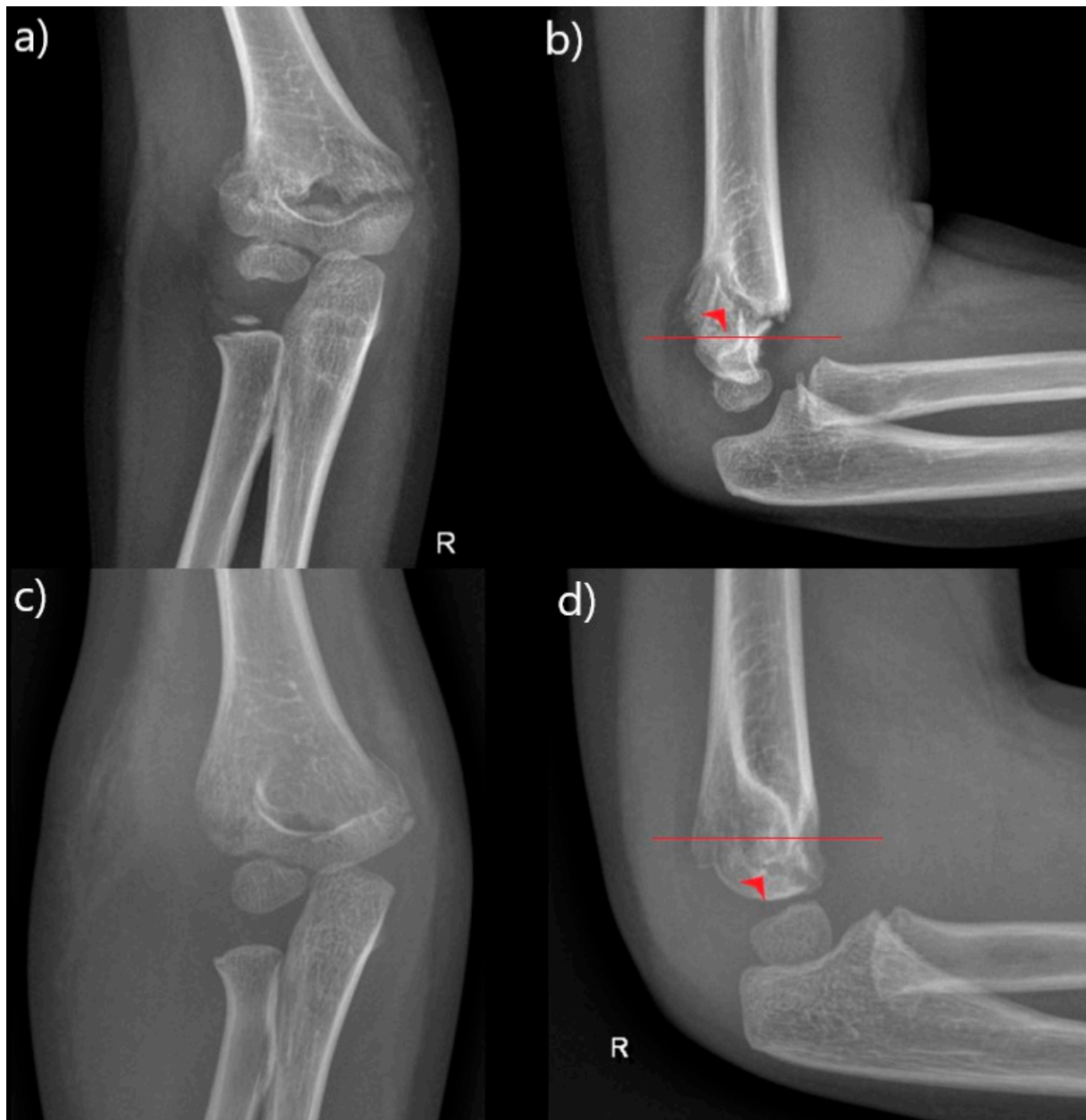


Figure S1. Anteroposterior and lateral x-rays of supracondylar fractures; (a,b) - high type of supracondylar fracture of the right humerus in a four-year-old boy; (c,d) - low type of supracondylar fracture of the right humerus in a five-year-old girl (red line - isthmus of the humerus, red arrow - fracture)