germs

MDPI

Review

Tubo-Ovarian Abscess, Sepsis and Diffuse Peritonitis in Pelvic Inflammatory Disease—A Diagnostic and Therapeutic Review

Yavor Kornovski [1,†], Stoyan Kostov [1,2], Yonka Ivanova [1], Stanislav Slavchev [1], Angel Yordanov [3,*] and Eva Tsoneva [4,†]

[1] Department of Gynecology, St. Anna University Hospital, Medical University of Varna, 9002 Varna, Bulgaria; ykornovski@abv.bg (Y.K.); drstoqn.kostov@gmail.com (S.K.); yonka.ivanova@abv.bg (Y.I.); st_slavchev@abv.bg (S.S.)
[2] Research Institute, Medical University Pleven, 5800 Pleven, Bulgaria
[3] Department of Gynecologic Oncology, Medical University Pleven, 5800 Pleven, Bulgaria
[4] Department of Reproductive Medicine, Specialized Hospital for Active Treatment of Obstetrics and Gynaecology Dr Shterev, 1330 Sofia, Bulgaria; dretsoneva@gmail.com
* Correspondence: angel.jordanov@gmail.com
† These authors contributed equally to this work.

Abstract

Background: Pelvic inflammatory disease (PID) is a common and potentially severe infection of the upper genital tract. Complications such as tubo-ovarian abscess (TOA), sepsis, and diffuse peritonitis contribute significantly to reproductive morbidity, particularly when diagnosis or treatment is delayed. Aim: The aim of this review is to present an updated, clinically relevant synthesis of the current evidence on the epidemiology, microbiology, diagnostic approach, imaging modalities, and management of PID, with a focus on severe forms including TOA, sepsis, and peritonitis. Content: PID is most frequently initiated by sexually transmitted pathogens—primarily *Chlamydia trachomatis* and *Neisseria gonorrhoeae*—which rapidly progresses to a polymicrobial infection involving anaerobic and enteric organisms. Diagnosis is predominantly clinical, supported by nucleic acid amplification tests, inflammatory markers, and imaging. Transvaginal ultrasonography remains the first-line diagnostic approach for suspected TOA, while CT or MRI is reserved for unclear cases or to assess rupture. Mild to moderate disease is managed with broad-spectrum combination antibiotics, whereas severe PID or TOA requires hospitalization, parenteral therapy, and timely source control through image-guided drainage or surgery. Ruptured abscesses and PID-associated sepsis demand urgent surgical intervention and multidisciplinary supportive care. Tailored approaches are necessary in pregnancy, adolescence, and immunosuppressed and postmenopausal patients. Conclusions: Prompt recognition, a low threshold for empiric antimicrobial therapy, the appropriate use of imaging, and decisive escalation to drainage or surgery are essential to limit morbidity and preserve reproductive health. Integrating guideline-based practice with structured clinical pathways may improve outcomes and reduce long-term sequelae of PID.

Keywords: pelvic inflammatory disease; tubo-ovarian abscess; peritonitis; sepsis; ultrasound; magnetic resonance imaging; anti-bacterial agents; drainage; laparoscopy

check for updates

Received: 27 October 2025
Revised: 15 December 2025
Accepted: 16 December 2025
Published: 18 December 2025

Citation: Kornovski, Y.; Kostov, S.; Ivanova, Y.; Slavchev, S.; Yordanov, A.; Tsoneva, E. Tubo-Ovarian Abscess, Sepsis and Diffuse Peritonitis in Pelvic Inflammatory Disease—A Diagnostic and Therapeutic Review. *Germs* **2025**, *15*, 6. https://doi.org/10.3390/germs15040006

Copyright: © 2025 by the authors. Published by MDPI on behalf of the Germs. Licensee MDPI, Basel, Switzerland. This article is an open access article distributed under the terms and conditions of the Creative Commons Attribution (CC BY) license (https://creativecommons.org/licenses/by/4.0/).

1. Introduction

Pelvic inflammatory disease (PID) represents a spectrum of ascending infections involving the endometrium, fallopian tubes, ovaries, and adjacent pelvic structures [1]. It

remains a major cause of reproductive morbidity worldwide, affecting millions of women annually and accounting for a substantial proportion of gynecologic emergency visits. Although many cases are mild and managed in outpatient settings, a significant proportion of patients present with moderate to severe disease, and delayed diagnosis can lead to tubo-ovarian abscess (TOA), diffuse peritonitis, sepsis, and long-term sequelae such as infertility, ectopic pregnancy, and chronic pelvic pain.

The epidemiology of PID varies widely across regions and populations, and is largely influenced by differences in STI surveillance, healthcare access, socioeconomic factors, and diagnostic thresholds. Young women under 25, individuals with inconsistent access to screening services, and those facing structural barriers to care remain disproportionately affected [2,3]. Despite the high prevalence of PID, clinical diagnosis is challenging. Symptoms are often nonspecific or subclinical, and up to one-third of cases present with minimal or atypical findings. There is also no single definitive diagnostic test; instead, clinicians rely on combinations of clinical criteria, laboratory results, and imaging when complications are suspected.

Severe manifestations such as TOA, sepsis, and diffuse purulent peritonitis represent the most dangerous forms of PID [4]. TOA is a polymicrobial abscess resulting from extension of infection to adnexal tissues; it carries significant risk of rupture, leading to sepsis and multisystem involvement. Management requires careful decision-making, balancing medical therapy, image-guided drainage, and surgical intervention. Thresholds for transitioning between these modalities vary across institutions, and evidence remains fragmented across the infectious disease, gynecology, emergency medicine, and radiology literature.

Given the ongoing challenges in accurately diagnosing and appropriately managing severe PID, as well as the evolving landscape of STI epidemiology—particularly the rise of macrolide-resistant *Mycoplasma genitalium* and multidrug-resistant *Neisseria gonorrhoeae*—there is a clear need for a consolidated, up-to-date synthesis of current evidence [5]. The existing literature is dispersed across multiple specialties, and many recent guideline updates, imaging advances, and risk-stratification considerations are not uniformly integrated into clinical practice.

The purpose of this narrative review is to synthesize the contemporary evidence regarding the epidemiology, pathophysiology, clinical presentation, diagnostic criteria, imaging findings, microbiology, and therapeutic strategies for PID, with an emphasis on cases complicated by TOA, sepsis, and diffuse peritonitis. By consolidating updated guidelines, severity assessment tools, imaging comparisons, and management thresholds, we aim to provide clinicians with a comprehensive and practical framework for effectively and promptly recognizing and treating severe pelvic infections.

2. Methods

This narrative review was conducted through structured searches of PubMed, Scopus, and Google Scholar for literature published between January 2010 and December 2024. Keywords included “pelvic inflammatory disease,” “tubo-ovarian abscess,” “peritonitis,” “sepsis,” “ultrasound,” “computed tomography,” “MRI,” “Mycoplasma genitalium,” and “laparoscopy.” Priority was given to clinical guidelines, systematic reviews, meta-analyses, and prospective studies. Inclusion criteria were English-language publications addressing epidemiology, diagnosis, imaging, microbiology, or management of PID or TOA. Exclusion criteria included case reports without broader applicability, non-clinical laboratory studies, and articles without clear methodologies. Reference lists of selected publications were reviewed for additional relevant literature.

3. Epidemiology

Pelvic inflammatory disease (PID) remains a significant public health issue, affecting millions of reproductive-aged women globally. Its incidence varies considerably between regions, largely reflecting disparities in sexually transmitted infection (STI) prevalence, access to healthcare, and availability of routine screening programs [6]. In high-income countries, the annual PID incidence has declined in areas with robust chlamydia and gonorrhea screening, although the overall disease burden remains substantial [7]. In contrast, rates are higher in low- and middle-income countries where screening, partner treatment, and sexual health education are limited.

Population-based surveillance data indicate that PID is most common among women aged 15–24, coinciding with the peak incidence of *Chlamydia trachomatis* and *Neisseria gonorrhoeae.* Adolescents carry the highest risk, driven by multiple sexual partners, unprotected intercourse and a prior STI. Despite improvements in diagnostic tools, a large proportion of PID cases remain underdiagnosed due to subclinical presentations and inconsistent reporting systems across countries. Rising antimicrobial resistance—particularly in *Mycoplasma genitalium* and *N. gonorrhoeae*—also poses emerging challenges for prevention and treatment [8].

4. Risk Factors

Pelvic inflammatory disease develops through a blend of behavioral, biological, and healthcare-related factors that often overlap. The risk rises in sexually active individuals under 25, those with multiple or new partners, inconsistent condom use, prior STIs—especially chlamydia or gonorrhea—and anyone with a previous episode of PID since persistent tubal damage increases recurrence [9]. Gynecologic events that disrupt the cervical barrier, including recent IUD insertion, endometrial biopsy, dilation and curettage, hysteroscopy, or other cervical and endometrial procedures, also heighten susceptibility, as do bacterial vaginosis and douching, which disturb the vaginal flora and promote ascending infection [10]. Overgrowth of anaerobic microbiologic contributors, such as *Chlamydia trachomatis*, *Neisseria gonorrhoeae*, *Mycoplasma genitalium*, is linked to bacterial vaginosis and polymicrobial infections that elevate the risk of tubo-ovarian abscess further affect disease severity [5]. Sociodemographic pressures—including low socioeconomic status, limited access to STI screening or timely treatment, lack of partner treatment, and broader healthcare barriers affecting adolescents, migrants, and uninsured patients—add another layer of vulnerability [6]. Finally, immunologic and host factors such as HIV, immunosuppressive therapy, poorly controlled diabetes, postpartum or post-abortion states where the cervical barrier is compromised, and rare nonsexual mechanisms like hematogenous spread in virgo intacta patients complete this complex risk profile [11].

5. Pathophysiology and Complications

Pelvic inflammatory disease (PID) results from the ascension of microorganisms from the lower genital tract into the endometrium, fallopian tubes, and peritoneal cavity [12]. Infection typically begins with cervicitis, where disruption of the cervical mucus barrier—often following an episode of *Chlamydia trachomatis*, *Neisseria gonorrhoeae*, or alterations in vaginal flora—permits microbial access to the upper reproductive organs. This early phase triggers epithelial injury, cytokine release, and recruitment of neutrophils, leading to endometritis and salpingitis.

Within the fallopian tubes, inflammation causes mucosal edema, destruction of ciliated epithelium, and sloughing of the tubal lining [13]. These changes impair normal tubal function, promote adhesion formation, and may result in tubal occlusion or hydrosalpinx. Persistent or inadequately treated infection can progress to pyosalpinx, which is

characterized by accumulation of purulent fluid within a distended fallopian tube [14]. A tubo-ovarian abscess (TOA) forms when infected fluid, inflammatory debris, and necrotic tissue become encapsulated by surrounding adnexal structures [15]. The pathogenesis is typically polymicrobial, reflecting contributions from anaerobes and facultative bacteria. As the abscess enlarges, local tissue destruction and adhesion formation create multiloculated collections that are poorly penetrated by antibiotics.

If a TOA is not promptly treated, pressure within the abscess cavity may exceed the tensile strength of surrounding tissue, leading to rupture [16]. Rupture of a TOA releases purulent material into the peritoneal cavity, triggering diffuse peritonitis, sepsis, and systemic inflammatory response. These events cause profound capillary leakage, third spacing, and potential progression to septic shock if not rapidly managed.

Inflammation from PID may also spread along the peritoneal surfaces without abscess formation. In Fitz-Hugh–Curtis syndrome, inflammatory exudate tracks along the paracolic gutters to the hepatic capsule, resulting in perihepatitis and characteristic "violin-string" adhesions between the liver and the anterior abdominal wall. Unlike diffuse peritonitis, this condition usually spares the hepatic parenchyma and responds to standard antibiotic therapy [17]. Overall, the pathophysiology of PID reflects a continuum ranging from mild mucosal infection to severe, life-threatening intra-abdominal disease. The degree of host inflammatory response, microbial virulence, and delayed access to treatment strongly influence progression to TOA, rupture, and sepsis.

6. Clinical Presentation

PID presents along a broad clinical spectrum, ranging from subtle discomfort to severe systemic illness. The variability in symptoms contributes significantly to underdiagnosis and delayed treatment. Many women experience only mild or nonspecific symptoms, while a substantial minority remain entirely asymptomatic. Subclinical PID is estimated to account for up to one-third of cases and is often identified only during evaluation for infertility or tubal abnormalities [1]. The most common symptom is lower abdominal or pelvic pain, typically bilateral and ranging from dull aching discomfort to sharp exacerbations. Pain frequently worsens during or shortly after menses when disruption of the cervical mucus barrier may facilitate ascending infection [18]. Additional symptoms include abnormal vaginal discharge, intermenstrual or postcoital bleeding, dyspareunia, urinary frequency or dysuria, nausea, and vomiting. Fever (>38 °C) and chills may be present in moderate to severe PID, although normal temperature does not exclude disease [1].

Physical examination classically reveals uterine, cervical motion, or adnexal tenderness, forming the minimum diagnostic criteria recommended by the CDC called the "Chandelier sign" (Figure 1) [19]. Adnexal fullness or a palpable mass raises suspicion for tubo-ovarian abscess (TOA), although guarding may limit the accuracy of bimanual examination. Right upper quadrant pain may occur in Fitz-Hugh–Curtis syndrome due to perihepatic inflammation and can mimic hepatobiliary pathology [17].

Atypical presentations occur in adolescents, postpartum patients, immunocompromised women, and virgo intacta individuals. In these groups, abdominal pain may be more diffuse and pelvic findings less pronounced, necessitating a lower threshold for imaging. Gastrointestinal and urinary symptoms may further obscure the diagnosis, and PID is frequently mistaken for appendicitis, ovarian torsion, urinary tract infection, or diverticulitis [18].

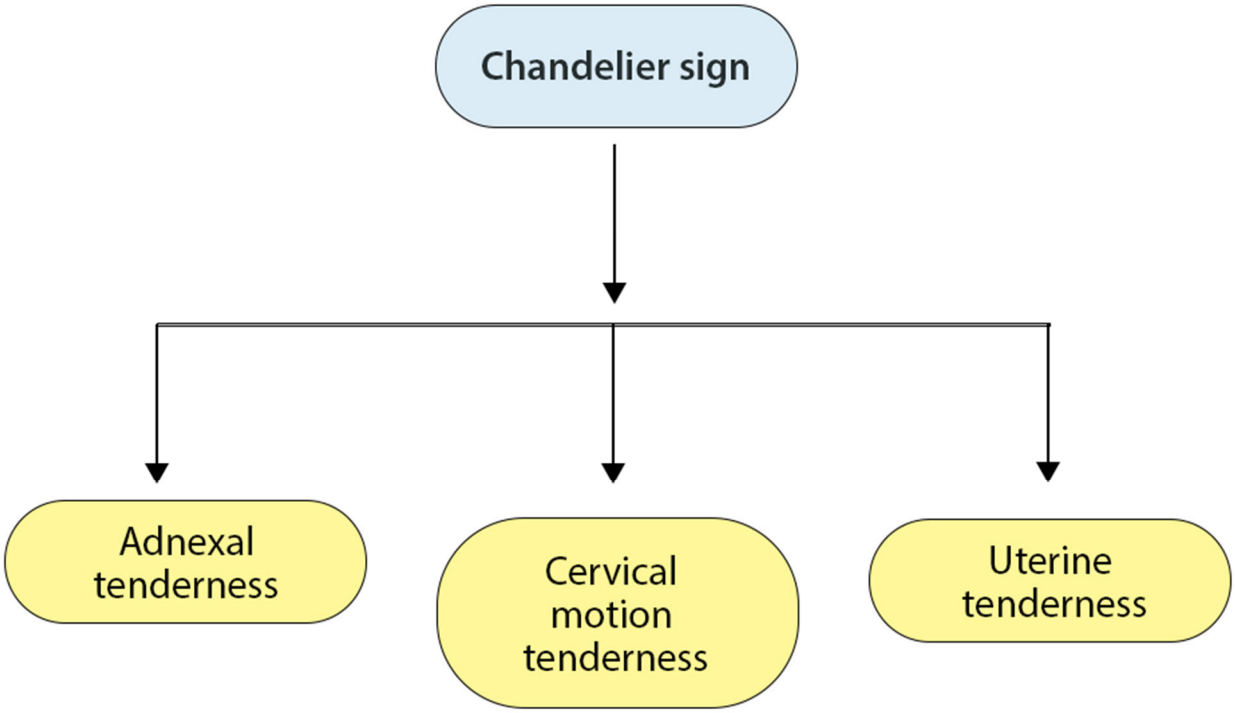

Figure 1. Chandelier sign in PID.

Because PID cannot be reliably confirmed or excluded based on clinical evaluations alone, clinicians are encouraged to maintain a high index of suspicion. Empiric treatment should be initiated when the CDC minimum criteria are met in the absence of an alternative diagnosis given the significant reproductive morbidity associated with delayed therapy. Early recognition is essential to prevent progression to severe complications such as TOA, peritonitis, sepsis, or chronic pelvic pain [19].

7. Diagnosis

Pelvic inflammatory disease remains chiefly a clinical diagnosis since no single laboratory or imaging test can definitively confirm or exclude it, and because delays in treatment increase the risk of infertility, ectopic pregnancy, and chronic pelvic pain, guidelines stress keeping a low threshold for empiric diagnosis in sexually active women with pelvic pain and findings suggestive of PID [19]. Empiric therapy should begin when pelvic or lower abdominal pain is present without a more likely alternative explanation and at least one of the following is noted on examination: cervical motion tenderness, uterine tenderness, or adnexal tenderness—criteria that favor sensitivity over specificity to avoid missing early disease. Diagnostic certainty increases when supportive features such as a fever above 38 °C, abnormal discharge, elevated inflammatory markers, leukocytosis, signs of cervicitis, or positive NAAT results for *Chlamydia trachomatis*, *Neisseria gonorrhoeae*, or *Mycoplasma genitalium* are present, though negative NAATs do not rule out PID because infection may have already moved beyond the cervix [18]. Laboratory evaluation typically includes pregnancy testing to exclude ectopic pregnancy, CBC, CRP, ESR, cervical NAAT for CT, NG, and MG, and urinalysis when urinary symptoms are present, with the caveat that inflammatory markers may remain normal in early or mild disease and therefore should not delay treatment [9]. Several clinical scoring systems support assessment and triage, including qSOFA for evaluating sepsis risk [20], MEWS for predicting deterioration [21], and the Modified McCormack Score for grading PID severity [22]. Because PID shares symptoms with a range of pelvic and abdominal emergencies—including ectopic pregnancy, ovarian torsion, ruptured ovarian cyst, acute appendicitis, diverticulitis, urinary tract infection,

and endometriosis—imaging becomes crucial when diagnosis is uncertain, pain is severe, adnexal masses are suspected, or treatment response is suboptimal [14]. While imaging is not required before treating mild to moderate disease, it is advised in severe presentations; when a tubo-ovarian abscess is suspected; when there is no improvement after 48–72 h of antibiotics; in immunocompromised patients, adolescents, and virgo-intact individuals; or when diagnostic ambiguity persists. To address the absence of a unified diagnostic pathway in the current literature, we introduce a new algorithm that integrates CDC criteria, severity scoring, laboratory thresholds, and clear triggers for imaging, drainage, and surgical intervention; this approach is intended to offer clinicians a more practical and cohesive framework for PID evaluation.

Diagnostic Algorithm for Evaluation of Suspected Pelvic Inflammatory Disease (Figure 2)
Step 1—Initial Clinical Assessment

- Presenting symptoms: pelvic/lower abdominal pain ± vaginal discharge, bleeding, fever, dyspareunia, dysuria.
- Mandatory test: urine/serum pregnancy test.
- Immediate red flags: hemodynamic instability, peritonitis, severe pain → urgent evaluation for TOA/rupture.

Step 2—Apply CDC Minimum Clinical Criteria
Treat empirically for PID if:

- Pelvic or lower abdominal pain **AND**
- No other more likely diagnosis **AND**
- ≥1 of:
    - Cervical motion tenderness;
    - Uterine tenderness;
    - Adnexal tenderness.

Step 3—Assess Severity (Mild/Moderate/Severe)
Mild/Moderate:

- No TOA on exam;
- Afebrile or low-grade fever;
- No systemic illness;
- Able to tolerate oral intake.

Severe:

- Suspected TOA;
- Temperature ≥38.5 °C;
- Markedly elevated CRP/ESR/WBC;
- Clinical sepsis or qSOFA ≥ 2;
- Pregnancy;
- Immunocompromised state;
- No improvement within 48–72 h of therapy.

Step 4—Decide on Imaging
Perform imaging when:

- Severe PID criteria met;
- Adnexal mass palpable;
- No improvement after 48–72 h;
- Diagnostic uncertainty (e.g., rule out torsion, appendicitis, diverticulitis);
- Adolescents/virgo intacta;
- Immunocompromised patients;

- Suspected TOA or rupture.

Imaging choice:

1. **Transvaginal ultrasound** (first-line);
2. **CT** if alternative abdominal pathology suspected or rupture suspected;
3. **MRI** if US is inconclusive.

Step 5—Management Pathway
If mild–moderate PID:

- Outpatient antibiotics;
- Re-evaluate in 48–72 h;
- If no improvement → switch to severe pathway.

If severe PID or TOA:

- Admit for IV therapy;
- Start broad-spectrum antibiotics;
- If TOA ≥7–8 cm OR no improvement in 48–72 h → image-guided drainage;
- If rupture OR sepsis → surgical management (laparoscopy or laparotomy).

Step 6—Follow-up and Prevention

- Ensure partner treatment;
- Abstinence until completion of therapy;
- Repeat STI testing at 3 months;
- Counsel on long-term fertility implications.

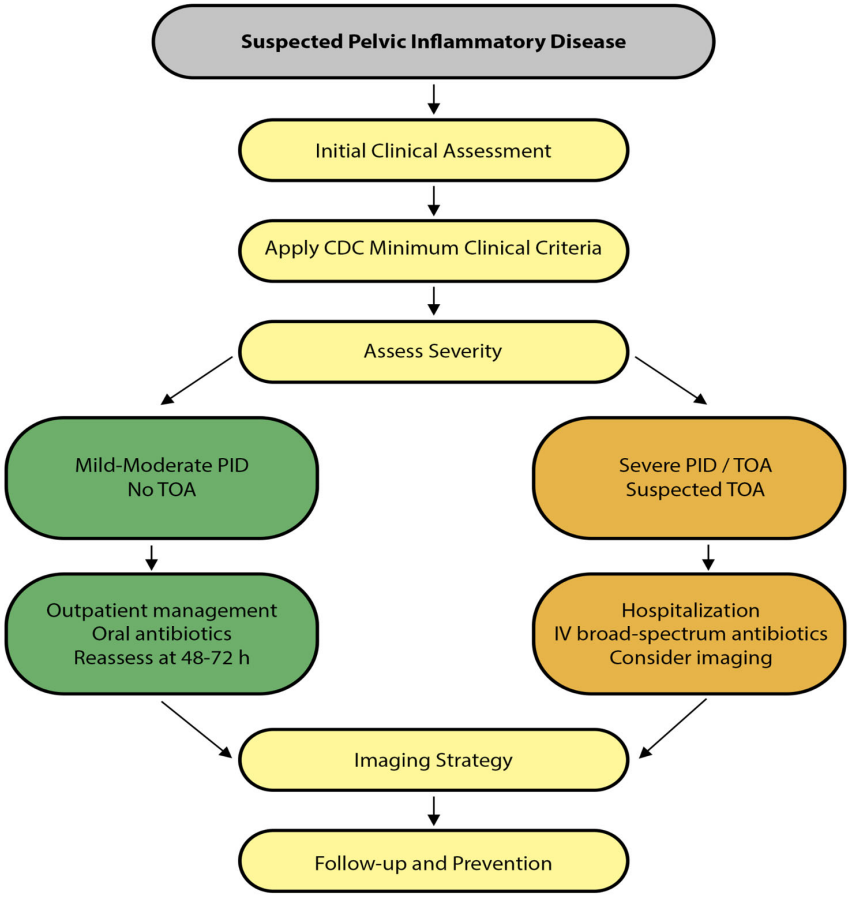

Figure 2. Diagnostic Algorithm for PID.

8. Imaging Modalities in Diagnosis

Imaging plays a crucial role in assessing patients with suspected severe pelvic inflammatory disease, particularly when symptoms are atypical, the diagnosis is uncertain, or complications such as tubo-ovarian abscess are being considered; although imaging is not required for mild or moderate PID, it becomes essential when pain is severe, the clinical picture is unclear, the treatment response is poor, or adnexal pathology is suspected [23]. Transvaginal ultrasound serves as the first-line modality because it is accessible, cost-effective, and allows for detailed visualization of the adnexa, with characteristic findings such as thickened fluid-filled tubes, the "cogwheel" appearance of endosalpingeal folds, indistinct tubo-ovarian complexes, free pelvic fluid, Doppler hyperemia, and complex adnexal masses suggestive of abscess. It offers a moderate sensitivity of around 75% and a high specificity near 90% for detecting TOA, though early salpingitis may remain invisible, meaning that a normal result does not rule out PID [14,24]. Ultrasound guidance is also widely used for transvaginal drainage of abscesses and has high rates of success in well-selected cases [24,25]. Computed tomography, although not a routine diagnostic tool for PID itself, becomes valuable in evaluating severe abdominal pain when appendicitis, diverticulitis, or perforation are in the differential; in suspected abscess rupture; for mapping extensive disease in unstable patients; or when ultrasound is limited. It can provide findings such as pelvic fat stranding, thickened tubes, enhancing adnexal masses, gas-forming abscesses, complex fluid collections, and signs of rupture. CT can reach sensitivities of up to about 90% for TOA but has a lower specificity due to overlap with gastrointestinal and other inflammatory conditions [26,27]. Magnetic resonance imaging offers superior soft-tissue definition and avoids radiation, achieving sensitivities as high as 95–100% and specificities of 90–100% for PID and TOA, making it the most accurate option when ultrasound is inconclusive or radiation needs to be avoided [14,28]. Its advantages include excellent anatomical detail, strong performance in differentiating PID from conditions like endometriosis or neoplasms, and improved detection of purulent material with diffusion-weighted sequences. MRI is especially useful in complex or unclear cases, in virgo intacta patients, and when assessing possible pelvic sidewall involvement or adnexal necrosis. Evidence-based triggers for imaging include severe pelvic or abdominal pain, suspected TOA, a palpable adnexal mass, failure to improve within 48–72 h of antibiotics, pregnancy, immunocompromise, adolescence or virginal status, diagnostic uncertainty involving torsion or gastrointestinal pathology, and concern for rupture or diffuse peritonitis—criteria consistent with the CDC and other major guideline recommendations.

9. Microbiology

Pelvic inflammatory disease is fundamentally polymicrobial, mirroring the complexity of the lower genital tract's microbial environment. Although ascending infection often begins with a sexually transmitted pathogen, progression into the upper genital tract and the development of inflammatory complications or abscesses typically involve a wider array of organisms, including anaerobes and facultative bacteria. Modern NAAT testing has clarified this landscape, showing that classic STIs account for only a portion of cases while endogenous flora play a major role in more severe disease. The principal sexually transmitted initiators remain *Chlamydia trachomatis*—often producing subclinical or minimally symptomatic disease due to its intracellular behavior—and Neisseria gonorrhoeae, which is more likely to cause abrupt symptoms and early complications [26]; both disrupt the cervical barrier and facilitate secondary microbial ascent, with NAAT serving as the diagnostic standard for its sensitivity and specificity [19]. *Mycoplasma genitalium* has become an increasingly significant contributor to cervicitis and upper tract infection, supported by molecular evidence identifying it within endometrial and tubal specimens, especially in mild or

slowly evolving PID [13]. Its intrinsic β-lactam resistance and rising macrolide resistance reduce responsiveness to standard regimens, prompting European guidance to recommend testing when available and using moxifloxacin for confirmed cases, while the CDC notes that empiric MG coverage remains of uncertain benefit [23]. Anaerobic and polymicrobial flora—including *Bacteroides fragilis*, *Prevotella*, *Peptostreptococcus*, *E. coli*, and *Group B Streptococcus*—are closely tied to severe PID and tubo-ovarian abscess. Their collagenases, cytotoxins, and biofilm-forming abilities drive tissue destruction and allow them to thrive in the low-oxygen, multiloculated environment of abscesses, emphasizing the need for strong anaerobic coverage in therapy [29]. Disruptions associated with bacterial vaginosis further heighten the risk as BV-related organisms like *Gardnerella vaginalis* and *Atopobium vaginae* promote pathogen ascension and sustain inflammation, acting as cofactors rather than independent causes of PID [30]. Rare etiologies appear in special settings such as virgo intacta patients, postoperative cases, or immunocompromised individuals, where the spread of enteric organisms, *Staphylococcus aureus*, or even hematogenous infections may play a role, though these remain uncommon [15]. Rising antimicrobial resistance—most notably in *N. gonorrhoeae* and *M. genitalium*—has become a major clinical concern, with WHO surveillance documenting expanding resistance to macrolides, fluoroquinolones, and cephalosporins, necessitating ongoing stewardship and updates to treatment guidelines. Taken together, the evolving microbiologic profile underscores the importance of broad anaerobic coverage, consideration of *M. genitalium* in persistent or non-resolving cases, and incorporation of local resistance patterns into therapeutic pathways, principles that are reflected in the diagnostic and management algorithm proposed in this review.

10. Medical Management

Early initiation of broad-spectrum antimicrobial therapy is essential in preventing the progression of pelvic inflammatory disease to tubo-ovarian abscess, peritonitis, infertility, and chronic pelvic pain, and current guidelines emphasize a low threshold for treatment because of diagnostic uncertainty and the serious consequences of delayed care [18]. Outpatient therapy may be used for clinically stable women who can tolerate oral medication and do not have severe pain, suspected TOA, pregnancy, or are immunocompromised. The preferred regimen remains a ceftriaxone-based combination: a single intramuscular dose of ceftriaxone 500 mg accompanied by doxycycline 100 mg twice daily and metronidazole 500 mg twice daily for 14 days, a regimen that provides coverage for N. gonorrhoeae, C. trachomatis, and the anaerobic and BV-associated flora implicated in PID [26]. Fluoroquinolone-based alternatives, such as levofloxacin with metronidazole, are reserved for settings with low gonococcal resistance or for patients with true cephalosporin allergy, although increasing quinolone resistance limits their utility [31]. Hospitalization becomes appropriate when TOA is suspected, when systemic illness or sepsis is present (including qSOFA $\geq$ 2), in pregnancy, when symptoms fail to improve after 48–72 h of outpatient therapy, when oral therapy cannot be tolerated, or in immunocompromised individuals. For inpatients, ceftriaxone-based regimens continue to be the first-line treatment, mirroring outpatient therapy but administered intravenously; the CDC recommends ceftriaxone 1 g IV every 24 h. Ceftriaxone is given together with doxycycline, with metronidazole added when anaerobic coverage is required. Acceptable cephalosporin alternatives include cefotetan 2 g IV every 12 h or cefoxitin 2 g IV every 6 h, both combined with doxycycline. The clindamycin plus gentamicin regimen—which uses clindamycin 900 mg IV every 8 h and gentamicin dosed with a 2 mg/kg loading dose followed by 1.5 mg/kg every 8 h—is now considered an alternative rather than the preferred regimen; patients receiving intravenous therapy of any type may transition to oral doxycycline and metronidazole once afebrile and clinically improving [23]. The total duration of treatment

across all care settings is 14 days, and failure to improve within 48–72 h should prompt reassessment, repeat imaging, and evaluation for TOA or other diagnoses [19]. Management must also consider *Mycoplasma genitalium*, which responds poorly to standard PID regimens due to intrinsic β-lactam resistance, high global macrolide resistance, and reduced susceptibility to doxycycline. When NAAT confirms M. genitalium, European guidelines recommend moxifloxacin 400 mg daily for 14 days [23], whereas the CDC advises against empiric MG coverage unless infection is documented [19]. Partner treatment remains essential; sexual contacts within the previous 60 days should receive empiric therapy for chlamydia and gonorrhea, and patients should abstain from intercourse until symptoms have resolved [19]. Those managed as outpatients must be reassessed within 48–72 h, and persistent symptoms should lead to hospital admission, imaging for TOA, consideration of resistant organisms such as *M. genitalium,* and, if needed, interventional or surgical drainage [13,19,23]. Retesting for STIs at three months is recommended because reinfection rates are high [19]. To address inconsistencies in existing guidelines regarding escalation of care, this review proposes a severity-based management framework that clarifies when outpatient treatment is appropriate, when inpatient intravenous therapy should begin, when drainage is indicated—particularly for abscesses larger than 7–8 cm or symptoms that fail to improve—and when surgical management becomes necessary. This structured approach integrates microbiological considerations, clinical severity, and response to therapy, offering a more coherent pathway than is currently available in published guidelines.

11. Management of Tubo-Ovarian Abscess

Tubo-ovarian abscess represents the most serious complication of pelvic inflammatory disease and requires timely, carefully structured management as these abscesses are typically polymicrobial and involve anaerobes, Gram-negative rods, and a mixture of endogenous genital-tract organisms. All patients with suspected or confirmed TOA require inpatient admission and broad-spectrum intravenous antimicrobial therapy that reliably covers anaerobic and Gram-negative pathogens, as recommended by major guidelines [19,23,32]. Clinical improvement is generally expected within 48–72 h, and failure to improve during this window raises concern for a larger, more complex, or potentially ruptured abscess. Abscess size is one of the strongest predictors of treatment response: collections smaller than approximately 5–7 cm often resolve with antibiotics alone, whereas those measuring 7–8 cm or more have significantly higher failure rates and typically require drainage [25,29]. Image-guided drainage has become the preferred next step for clinically stable patients whose symptoms persist despite adequate medical therapy or whose abscess size meets criteria for intervention. Transvaginal ultrasound-guided drainage is considered the first-line technique and achieves clinical success rates near 90% in contemporary studies [25], while CT-guided percutaneous drainage through retroperitoneal or transgluteal routes serves as an alternative when transvaginal access is not feasible [33]. Such minimally invasive approaches shorten hospitalization and frequently avert the need for definitive surgery [34]. Surgical management becomes necessary in a subset of patients, particularly when clinical stability is threatened or when conservative measures fail. Immediate operative intervention is required when abscess rupture is suspected or when the patient presents with diffuse purulent peritonitis, conditions associated with a high risk of septic shock and the need for urgent source control [35]. Hemodynamic instability or sepsis likewise mandates operative management, as image-guided drainage alone may not provide rapid stabilization [33]. Patients who fail to improve after 48–72 h of appropriate antimicrobial therapy and attempted drainage, or who harbor large, multiloculated abscesses not amenable to percutaneous access, should also be evaluated for surgery [36]. Operative exploration is further warranted when there is suspicion of underlying malignancy—an im-

portant consideration in postmenopausal women, who exhibit a higher likelihood of occult neoplasia presenting with adnexal masses [37]—and may also be necessary in adolescents who often present late with atypical or severe PID and may require diagnostic laparoscopy for clarification [38]. The choice between laparoscopy and laparotomy depends on clinical stability, surgeon expertise, and the extent of intra-abdominal contamination, with overall priorities centered on rapid control of sepsis and preservation of fertility whenever possible.

To support clinical decision-making and to address guideline variability, Table 1 summarizes the key indications and contraindications for image-guided drainage, laparoscopy, and laparotomy in the management of tubo-ovarian abscess.

Table 1. Indications and Contraindications for Image-Guided Drainage, Laparoscopy, and Laparotomy in Tubo-Ovarian Abscess (TOA).

Management Approach	Indications	Contraindications	Advantages
Image-Guided Drainage (Transvaginal US-guided or CT-guided) [27]	• TOA $\geq$ 7–8 cm • Persistent fever/pain after 48–72 h on IV antibiotics • Unilocular or accessible multiloculated abscess • Hemodynamically stable patient • Fertility preservation desired	• Ruptured TOA • Hemodynamic instability or sepsis • Inaccessible abscess location (bowel loops, adhesions) • Coagulopathy not corrected • Suspicion of malignancy	• Minimally invasive • High success rate (~90%) • Fertility-sparing • Shorter hospital stay • Can be repeated
Laparoscopy [25]	• Failure of percutaneous drainage • Large or multiloculated TOA not amenable to aspiration • Diagnostic uncertainty (e.g., torsion, appendicitis) • Fertility preservation desired • Stable patient with extensive adhesions requiring lysis	• Diffuse purulent peritonitis • Severe sepsis/shock • Inability to visualize anatomy safely (dense adhesions, distorted pelvis)	• Less morbidity compared to laparotomy • Precise drainage and irrigation • Adhesiolysis possible • Preserves fertility
Laparotomy [38]	• Ruptured TOA with peritonitis • Severe sepsis or septic shock • Hemodynamic instability • No improvement despite drainage + antibiotics • Suspicion of malignancy (especially postmenopausal women) • Very large or complex multiloculated abscess	• Higher morbidity • Longer recovery • May compromise fertility	• Rapid and definitive source control • Essential for life-threatening rupture • Allows for exploration and removal of necrotic tissue • Appropriate when malignancy is suspected

12. Surgical Management

Surgical intervention becomes necessary in patients with tubo-ovarian abscess who deteriorate clinically or fail to respond to antimicrobial therapy and image-guided drainage, and laparoscopy is generally preferred whenever the patient's condition and anatomy allow. Compared with laparotomy, laparoscopy offers reduced postoperative pain, shorter hospi-

talization, faster recovery, and the advantage of directly visualizing and draining abscess cavities, lysing adhesions, and thoroughly irrigating the pelvis, all while maximizing the likelihood of preserving reproductive potential in younger women [39]. Despite these benefits, certain clinical situations demand conversion to, or primary use of, an open approach. Laparotomy is often unavoidable in cases of ruptured TOA with diffuse purulent peritonitis, hemodynamic instability, severe sepsis, or when dense adhesions or distorted pelvic anatomy prevent safe laparoscopic access. In these circumstances, the priority shifts away from fertility preservation toward rapid, life-saving source control [40]. Fertility considerations remain central in reproductive-age women, and conservative strategies—including laparoscopic drainage, irrigation, and selective excision of necrotic tissue—should be used whenever feasible [25]. By contrast, postmenopausal women more frequently require salpingo-oophorectomy as the likelihood of underlying malignancy is higher and the response to conservative therapy is poorer in this population [37].

13. Special Populations

Certain patient populations require tailored diagnostic and therapeutic approaches due to higher risk profiles or atypical presentations. PID during pregnancy is uncommon but poses significant dangers to both mother and fetus, necessitating hospitalization and parenteral therapy while avoiding medications contraindicated in pregnancy. Early imaging with ultrasound or MRI is essential to distinguish PID from appendicitis or TOA, and any required surgical intervention must prioritize uterine preservation and fetal wellbeing [19]. Adolescents and virgo intacta patients often present with vague or atypical symptoms, which can delay diagnosis and lead to more advanced disease, including a higher incidence of TOA. Ultrasound is the preferred first-line imaging modality, with CT or MRI reserved for equivocal cases, and persistent uncertainty may require diagnostic laparoscopy [11]. Immunocompromised patients—such as those with HIV, organ transplant recipients, or individuals on chronic immunosuppressive medications—are particularly susceptible to severe PID, abscess formation, and polymicrobial or opportunistic infections. For these patients, a lower threshold for admission, advanced imaging, and invasive intervention are recommended [41]. Postmenopausal women represent another distinctive group in whom PID and TOA are rare but often more serious; these patients face a greater likelihood of underlying genital tract malignancy, an increased risk of abscess rupture, and diminished responsiveness to antibiotic therapy alone, making operative management, including salpingo-oophorectomy, more likely to be necessary [42].

14. Complications and Prognosis

Pelvic inflammatory disease carries a substantial burden of both acute and long-term morbidity, particularly when diagnosis or treatment is delayed, and its complications reflect the spectrum of inflammation and structural damage that can evolve over time. Tubo-ovarian abscess develops in roughly 20–30% of women who require hospitalization for PID [34], with multiloculated collections or late presentation significantly increasing the need for drainage or surgical management. Infertility remains one of the most feared sequelae as tubal damage correlates directly with both the severity and frequency of PID episodes; recurrent infection, TOA, or inadequate or delayed therapy markedly raise the risk of tubal occlusion and subsequent infertility [43]. These damaged tubes also predispose patients to ectopic pregnancy, with the risk rising six- to ten-fold after PID [44]. Chronic pelvic pain affects an estimated 30% of women after severe PID or TOA as a result of persistent inflammation, adhesions, and scarring [43]. In some cases, the infection spreads beyond the pelvis to the liver capsule, resulting in Fitz-Hugh–Curtis syndrome, which manifests as right upper quadrant pain and characteristic “violin-string”

adhesions, usually without elevation of liver enzymes and typically resolving with appropriate antimicrobial therapy [17]. The most life-threatening complication is rupture of a TOA, which can precipitate sepsis and diffuse peritonitis and demands immediate surgical intervention, broad-spectrum intravenous antibiotics, and intensive supportive care. Collectively, these complications underscore the critical importance of early recognition, aggressive management, and structured follow-up to reduce morbidity and preserve reproductive health.

15. Discussion

This review brings together current evidence on the diagnosis and management of pelvic inflammatory disease and its more serious complications, with particular attention to the practical decisions clinicians must make regarding imaging, severity assessment, and escalation of care. A recurring challenge emphasized throughout the literature is the difficulty of establishing a timely diagnosis as PID often presents with vague, overlapping, or even subclinical symptoms. When recognition is delayed, the likelihood of infertility, ectopic pregnancy, and complications such as tubo-ovarian abscess or sepsis rises sharply. One of the central contributions of this review is the attempt to unify recommendations that are typically scattered across multiple guidelines. By integrating diagnostic criteria, severity stratification, imaging thresholds, and interventional steps into a single coherent algorithm, the review offers a structured pathway that aligns clinical, radiologic, and procedural decision-making—an approach that is rarely presented as a consolidated framework in existing publications.

Current practice continues to face significant hurdles, not least the growing problem of antimicrobial resistance in *N. gonorrhoeae* and *M. genitalium*, and the wide variation in imaging practices across institutions. Important questions remain unresolved, including the optimal management of PID in the setting of confirmed *M. genitalium* infection, the most reliable criteria for determining when image-guided drainage is indicated, and the long-term reproductive impact of various surgical and interventional strategies.

16. Conclusions

Pelvic inflammatory disease continues to be a major contributor to reproductive morbidity, infertility, and emergency gynecologic admissions. Rapid identification, timely initiation of broad-spectrum antimicrobials, and judicious use of imaging are essential to minimize complications. When TOA develops, care must escalate in a structured manner—from medical therapy to drainage or surgery—guided by abscess size, clinical response, and patient stability. The unified diagnostic and management framework presented here, including a novel evidence-based algorithm, is intended to support clinicians in navigating these decisions. Looking ahead, research priorities should include refining treatment strategies for *M. genitalium*, improving imaging criteria for TOA assessment, and developing a better understanding of fertility outcomes following modern interventional and surgical management.

Author Contributions: Conceptualization: Y.K.; methodology: Y.K., E.T. and A.Y.; formal analysis: Y.K., Y.I. and S.S.; investigation: Y.K. and E.T.; resources: E.T., Y.I. and S.K.; data curation: S.S., Y.I. and E.T.; writing—original and draft preparation: Y.K. and E.T.; writing—review and editing: A.Y., S.K. and E.T.; visualization: E.T.; supervision: Y.K. and A.Y. All authors have read and agreed to the published version of the manuscript.

Funding: This research received no external funding.

Institutional Review Board Statement: Not applicable.

Data Availability Statement: The authors declare that all related data can be made available to interested researchers by contacting the corresponding author via email.

Conflicts of Interest: The authors declare no competing interests.

References

1. Curry, A.; Williams, T.; Penny, M.L. Pelvic Inflammatory Disease: Diagnosis, Management, and Prevention. *Am. Fam. Physician* **2019**, *100*, 357–364.
2. Kreisel, K.; Torrone, E.; Bernstein, K.; Hong, J.; Gorwitz, R. Prevalence of Pelvic Inflammatory Disease in Sexually Experienced Women of Reproductive Age—United States, 2013–2014. *MMWR Morb. Mortal Wkly. Rep.* **2017**, *66*, 80–83. [CrossRef] [PubMed]
3. Benaim, J.; Pulaski, M.; Coupey, S.M. Adolescent girls and pelvic inflammatory disease: Experience and practices of emergency department pediatricians. *Arch. Pediatr. Adolesc. Med.* **1998**, *152*, 449–454. [CrossRef] [PubMed]
4. Brunham, R.C.; Gottlieb, S.L.; Paavonen, J. Pelvic inflammatory disease. *N. Engl. J. Med.* **2015**, *372*, 2039–2048. [CrossRef] [PubMed]
5. *Gonorrhoea* (*Neisseria gonorrhoeae* Infection). Available online: https://www.who.int/news-room/fact-sheets/detail/gonorrhoea-(neisseria-gonorrhoeae-infection) (accessed on 17 October 2025).
6. European Centre for Disease Prevention and Control. Chlamydia. In *ECDC. Annual Epidemiological Report for 2023*; ECDC: Stockholm, Sweden, 2025.
7. Available online: https://www.gov.uk/government/publications/pelvic-inflammatory-disease-in-england/rates-of-pelvic-inflammatory-disease-pid-diagnoses-in-england-2014-to-2023-an-outcome-of-stis-and-other-factors (accessed on 18 October 2025).
8. Dela, H.; Behene, E.; Ocansey, K.; Yanney, J.N.; Kwasi Addo, K.; Miranda, H.V.; Letizia, A.G.; Fox, A.T.; Sanders, T.; Attram, N. Prevalence and macrolide resistance of Mycoplasma genitalium from patients seeking sexual health care in Southern Ghana. *BMC Infect. Dis.* **2024**, *24*, 981. [CrossRef] [PubMed] [PubMed Central]
9. Simms, I.; Stephenson, J.M.; Mallinson, H.; Peeling, R.W.; Thomas, K.; Gokhale, R.; Rogers, P.A.; Hay, P.; Oakeshott, P.; Hopwood, J.; et al. Risk factors associated with pelvic inflammatory disease. *Sex Transm. Infect.* **2006**, *82*, 452–457. [CrossRef] [PubMed] [PubMed Central]
10. Goje, O. Pelvic Inflammatory Disease (PID). Available online: https://www.msdmanuals.com/professional/gynecology-and-obstetrics/vaginitis-cervicitis-and-pelvic-inflammatory-disease/pelvic-inflammatory-disease-pid (accessed on 18 October 2025).
11. Surd, A.; Muresan, R.; Oprea, A.; Snakovszki, K.; Sur, L.M.; Usatiuc, L.O.; Ciongradi, C.I.; Sârbu, I. Diagnostic Challenges and Management Strategies of Pelvic Inflammatory Disease in Sexually Inactive Pediatric and Adolescent Patients: A Systematic Review of Case Reports. *J. Clin. Med.* **2025**, *14*, 3971. [CrossRef] [PubMed] [PubMed Central]
12. Beigi, R.H.; Wiesenfeld, H.C. Pelvic inflammatory disease: New diagnostic criteria and treatment. *Obs. Gynecol. Clin. N. Am.* **2003**, *30*, 777–793. [CrossRef] [PubMed]
13. Haggerty, C.L.; Totten, P.A.; Astete, S.G.; Lee, S.; Hoferka, S.L.; Kelsey, S.F.; Ness, R.B. Failure of cefoxitin and doxycycline to eradicate endometrial Mycoplasma genitalium and the consequence for clinical cure of pelvic inflammatory disease. *Sex. Transm. Infect.* **2008**, *84*, 338–342. [CrossRef] [PubMed] [PubMed Central]
14. Tukeva, T.A.; Aronen, H.J.; Karjalainen, P.T.; Molander, P.; Paavonen, T.; Paavonen, J. MR imaging in pelvic inflammatory disease: Comparison with laparoscopy and US. *Radiology* **1999**, *210*, 209–216. [CrossRef] [PubMed]
15. Goje, O.; Markwei, M.; Kollikonda, S.; Chavan, M.; Soper, D.E. Outcomes of Minimally Invasive Management of Tubo-ovarian Abscess: A Systematic Review. *J. Minim. Invasive Gynecol.* **2021**, *28*, 556–564. [CrossRef] [PubMed]
16. Li, H.; Zhao, Y.; Chang, X.H.; Wang, Y.; Zhu, H.L. Clinical characteristics, treatment status and complications in women with tube ovarian abscess and endometriosis: A retrospective study. *BMC Womens Health* **2021**, *21*, 109. [CrossRef] [PubMed] [PubMed Central]
17. Peter, N.G.; Clark, L.R.; Jaeger, J.R. Fitz-Hugh-Curtis syndrome: A diagnosis to consider in women with right upper quadrant pain. *Clevel. Clin. J. Med.* **2004**, *71*, 233–239. [CrossRef] [PubMed]
18. Alshammari, S.M.; Alrajhi, N.N.; Al-Rumayh, S.S.; Alosaimi, M.A.; Alsharyufi, R.M.; Bukhari, Y.S.; Aldhrye, S.A.; Kasem, G.H.; Aljohani, R.M.J. An Overview on Pelvic Inflammatory Disease Diagnosis and Management Approach. *Arch. Pharm. Pract.* **2021**, *12*, 103–105. [CrossRef]
19. CDC. Sexually Transmitted Infections (STI) Treatment Guidelines, 2021. Pelvic Inflammatory Disease (PID). Available online: https://www.cdc.gov/std/treatment-guidelines/pid.htm#: :text=isolated%20from%20the%20upper%20genital,Treatment (accessed on 19 October 2025).
20. Singer, M.; Deutschman, C.S.; Seymour, C.W.; Shankar-Hari, M.; Annane, D.; Bauer, M.; Bellomo, R.; Bernard, G.R.; Chiche, J.D.; Coopersmith, C.M.; et al. The Third International Consensus Definitions for Sepsis and Septic Shock (Sepsis-3). *JAMA* **2016**, *315*, 801–810. [CrossRef] [PubMed] [PubMed Central]

21. Subbe, C.P.; Kruger, M.; Rutherford, P.; Gemmel, L. Validation of a modified Early Warning Score in medical admissions. *QJM* **2001**, *94*, 521–526. [CrossRef] [PubMed]
22. McCormack, W.M. Pelvic inflammatory disease. *N. Engl. J. Med.* **1994**, *330*, 115–119. [CrossRef] [PubMed]
23. Ross, J.; Judlin, P.; Nilas, L. European guideline for the management of pelvic inflammatory disease. *Int. J. STD AIDS* **2007**, *18*, 662–666. [CrossRef] [PubMed]
24. Perez-Medina, T.; Huertas, M.A.; Bajo, J.M. Early ultrasound-guided transvaginal drainage of tubo-ovarian abscesses: A randomized study. *Ultrasound Obstet. Gynecol.* **1996**, *7*, 435–438. [CrossRef] [PubMed]
25. Gjelland, K.; Ekerhovd, E.; Granberg, S. Transvaginal ultrasound-guided aspiration for treatment of tubo-ovarian abscess: A study of 302 cases. *Am. J. Obstet. Gynecol.* **2005**, *193*, 1323–1330. [CrossRef] [PubMed]
26. Sweet, R.L. Treatment of acute pelvic inflammatory disease. *Infect. Dis. Obs. Gynecol.* **2011**, *2011*, 561909. [CrossRef] [PubMed] [PubMed Central]
27. Gigli, S.; Gennarini, M.; Ninkova, R.V.; Miceli, V.; Curti, F.; Riccardi, S.; Cutonilli, C.; Frezza, F.; Amoroso, C.; Catalano, C.; et al. Cross-Sectional Imaging of Pelvic Inflammatory Disease: Diagnostic Pearls and Pitfalls on CT and MR. *Diagnostics* **2025**, *15*, 2001. [CrossRef] [PubMed] [PubMed Central]
28. Puissant, G.; Fellah, L.; Perlepe, V. Multimodality Imaging of Pelvic Inflammatory Disease Complicated with Tubo-Ovarian Abscess. *J. Belg. Soc. Radiol.* **2023**, *107*, 20. [CrossRef] [PubMed] [PubMed Central]
29. Fouks, Y.; Cohen, A.; Shapira, U.; Solomon, N.; Almog, B.; Levin, I. Surgical Intervention in Patients with Tubo-Ovarian Abscess: Clinical Predictors and a Simple Risk Score. *J. Minim. Invasive Gynecol.* **2019**, *26*, 535–543. [CrossRef] [PubMed]
30. Al-Kuran, O.; Al-Mehaisen, L.; Alduraidi, H.; Al-Husban, N.; Attarakih, B.; Sultan, A.; Othman, Z.; AlShárat, S.; AlHilali, S.; Alkouz, N.; et al. How prevalent are symptoms and risk factors of pelvic inflammatory disease in a sexually conservative population. *Reprod. Health* **2021**, *18*, 109. [CrossRef] [PubMed] [PubMed Central]
31. WHO. Enhanced Gonococcal AMR Surveillance Programme (EGASP). Available online: https://www.who.int/initiatives/gonococcal-antimicrobial-surveillance-programme (accessed on 21 October 2025).
32. Landers, D.V.; Sweet, R.L. Tubo-ovarian abscess: Contemporary approach to management. *Rev. Infect. Dis.* **1983**, *5*, 876–884. [CrossRef] [PubMed]
33. Tyrrel, R.T.; Murphy, F.B.; Bernardino, M.E. Tubo-ovarian abscesses: CT-guided percutaneous drainage. *Radiology* **1990**, *175*, 87–89. [CrossRef] [PubMed]
34. Farid, H.; Lau, T.C.; Karmon, A.E.; Styer, A.K. Clinical Characteristics Associated with Antibiotic Treatment Failure for Tuboovarian Abscesses. *Infect. Dis. Obstet. Gynecol.* **2016**, *2016*, 5120293. [CrossRef] [PubMed] [PubMed Central]
35. Micheli, G.; Parpex, G.; Tazi, A.; Holeindre, E.; Loubinoux, J.; Guyonnet, C.; Reboul-Marty, J.; Poyart, C.; Chapron, C.; Richebé, P.; et al. Microbiology and outcomes of tubo-ovarian abscesses: A 5-year cohort of 105 cases. *J. Infect.* **2024**, *89*, 106253. [CrossRef] [PubMed]
36. Goharkhay, N.; Verma, U.; Maggiorotto, F. Comparison of CT- or ultrasound-guided drainage with concomitant intravenous antibiotics vs. intravenous antibiotics alone in the management of tubo-ovarian abscesses. *Ultrasound Obstet. Gynecol.* **2007**, *29*, 65–69. [CrossRef] [PubMed]
37. Gözüküçük, M.; Yıldız, E.G. Is it possible to estimate the need for surgical management in patients with a tubo-ovarian abscess at admission? A retrospective long-term analysis. *Gynecol. Surg.* **2021**, *18*, 14. [CrossRef]
38. Jalloul, R.J.; Thomas, M.; Ward, C.; Pedroza, C. Clinical Predictors of Failed Medical Treatment in Patients with Tubo-ovarian Abscess: External Validation of a Recently Published Risk Score. *J. Minim. Invasive Gynecol.* **2022**, *29*, 649–655. [CrossRef] [PubMed]
39. George, J.P. Laparoscopic Management of Tubo-Ovarian Abscess. *J. Am. Assoc. Gynecol. Laparosc.* **1994**, *1*, S12. [CrossRef] [PubMed]
40. Casola, G.; vanSonnenberg, E.; D'Agostino, H.B.; Harker, C.P.; Varney, R.R.; Smith, D. Percutaneous drainage of tubo-ovarian abscesses. *Radiology* **1992**, *182*, 399–402. [CrossRef] [PubMed]
41. Workowski, K.A.; Bachmann, L.H.; Chan, P.A.; Johnston, C.M.; Muzny, C.A.; Park, I.; Reno, H.; Zenilman, J.M.; Bolan, G.A. Sexually Transmitted Infections Treatment Guidelines, 2021. *MMWR Recomm. Rep.* **2021**, *70*, 1–187. [CrossRef] [PubMed] [PubMed Central]
42. Chan, G.M.F.; Fong, Y.F.; Ng, K.L. Tubo-Ovarian Abscesses: Epidemiology and Predictors for Failed Response to Medical Management in an Asian Population. *Infect. Dis. Obstet. Gynecol.* **2019**, *2019*, 4161394. [CrossRef] [PubMed] [PubMed Central]

43. Wiesenfeld, H.C.; Sweet, R.L. Progress in the management of tuboovarian abscesses. *Clin. Obstet. Gynecol.* **1993**, *36*, 433–444. [CrossRef] [PubMed]
44. Hillis, S.D.; Owens, L.M.; Marchbanks, P.A.; Amsterdam, L.F.; Mac Kenzie, W.R. Recurrent chlamydial infections increase the risks of hospitalization for ectopic pregnancy and pelvic inflammatory disease. *Am. J. Obstet. Gynecol.* **1997**, *176*, 103–107. [CrossRef] [PubMed]

Disclaimer/Publisher's Note: The statements, opinions and data contained in all publications are solely those of the individual author(s) and contributor(s) and not of MDPI and/or the editor(s). MDPI and/or the editor(s) disclaim responsibility for any injury to people or property resulting from any ideas, methods, instructions or products referred to in the content.